



## CASE REPORT

# Arterial damages in acute elbow dislocations: which diagnostic tests are required?

Christoph Lutter,<sup>1,2</sup> Ronny Pfefferkorn,<sup>2</sup> Volker Schoeffl<sup>2</sup>

<sup>1</sup>CVPath Institute,  
Gaithersburg, Maryland, USA

<sup>2</sup>Department of Sports  
Orthopedics, Sports Medicine,  
Sports Traumatology,  
Department for Orthopedics  
and Traumatology, Klinikum  
Bamberg, Bamberg, Germany

## Correspondence to

Dr Christoph Lutter,  
christoph.lutter@googlemail.  
com

Accepted 5 July 2016

## SUMMARY

Blunt vessel injuries of peripheral arteries caused by a direct trauma are rare. Studies have described the frequency of arterial ruptures following closed elbow dislocations in 0.3–1.7% of all cases. However, arterial damage does not always necessarily appear as a complete rupture of the vessel with a loss of peripheral circulation and ischaemic symptoms; a relatively strong periarticular system of collaterals can maintain circulation. Furthermore, the traumatic dislocation can also cause intimal tears, arterial dissections and aneurysms or thrombosis. In all cases of vessel injury, including total disruption, a peripheral pulse might still be palpable. 3 weeks after an acute elbow dislocation, we have diagnosed a patient with a long-segment stenosis of the brachial artery and a thrombosis of the radial artery. Therefore, the close anatomic proximity to the neurovascular structures should always be considered in cases of elbow dislocations, even if peripheral pulses are traceable.

## BACKGROUND

Acute elbow dislocations combined with vascular injury are rare cases and the literature only describes case reports or case series. However, in most of the reported cases, the dislocation had caused a rupture of the brachial and/or radial artery, especially in cases of severe traumas with open fractures.<sup>1–5</sup> While isolated dislocations without vascular injuries normally have a good prognosis, a combined injury with vascular damage requires immediate therapy to avoid further damage due to ischaemia. However, the anatomic proximity of neurovascular structures promotes concomitant lesions in cases of severe dislocation with or without fractures and/or bleeding. As we usually see few complications or problems in the treatment of elbow dislocations, we have now diagnosed a patient with an unexpected vascular lesion 3 weeks after the elbow dislocation.

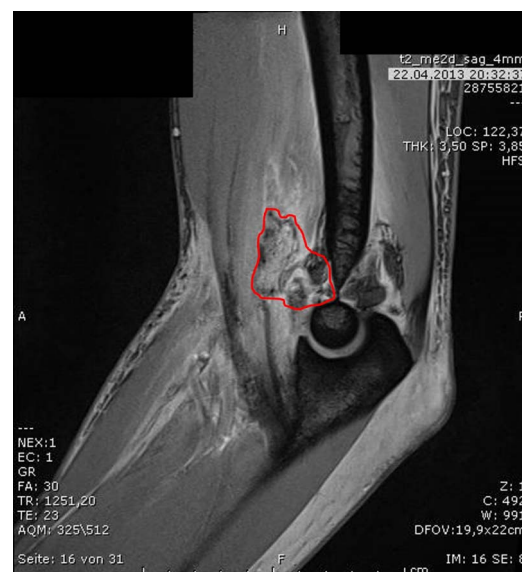## CASE PRESENTATION

A 24-year-old white male patient without any known pre-existing diseases, risk factors, genetic predispositions or drug intake/abuse was diagnosed with an acute posterior elbow dislocation of the left arm in an external emergency room (ER). The patient described a fall on a crash pad (protection device) with his extended arm during bouldering (ropeless rock climbing in low heights). Primary investigations in the ER showed sufficient peripheral circulation, mobility and sensitivity, and a non-dislocated radial-head fracture was seen in

radiographs. After reduction, the left arm was immobilised in a splint and the patient was discharged. Several days later, MRI was performed, showing a partial detachment of the extensor muscles from the radial epicondyle and a medial sided ligamentous lesion (figure 1). In addition, a partial rupture of the brachial muscle tendon and a haematoma within the brachial muscle were detected.

## INVESTIGATIONS

Two weeks later, the patient was seen in our outpatient clinic. The left arm was still immobilised in a 110° extension position in the elbow, and an old haematoma was visible on the medial side of the elbow after removal of the cast. Neither the sensitivity of the forearm and fingers nor the finger mobility was affected. Palpation of the ulnar side flexor muscles revealed a strand-like subcutaneous hardening; peripheral circulation was inconspicuous and radial pulses were easily palpable. According to the numerical analogical pain scale (0–10; 0 representing no pain, 10 representing maximum pain), the patient was completely painless with the arm immobilised in the splint, and only palpation of the medial and lateral epicondyle caused slight pain. While radiographs confirmed the correct positioning of the radial head fracture, the examination of the articular stability showed



**Figure 1** MR-image of the left elbow several days after the dislocation. The red frame indicates a partial rupture of the biceps tendon with intramuscular haematoma.



CrossMark

**To cite:** Lutter C,  
Pfefferkorn R, Schoeffl V.  
*BMJ Case Rep* Published  
online: [please include Day  
Month Year] doi:10.1136/  
bcr-2016-216336

instability under varus and valgus stress and under full extension. Surgical restabilisation of the joint was therefore planned.

### DIFFERENTIAL DIAGNOSIS

Complex capsule-ligament injuries

Bone or articular fractures

Lesions of the nerve vessel bundle

Arterial rupture, arterial dissection, arterial aneurysm, thrombosis and chronic (sub) total occlusion.

### TREATMENT

Surgery was performed 5 days after the initial patient contact in our outpatient clinic. After refixation of the ligament lesions on both the radial and the ulnar side of the elbow and examination of the brachial and biceps muscles and tendons, the nerve vessel bundle appeared to be hardened and scarred over 6–8 cm. Furthermore, only a weak pulsation of the artery was palpable over this distance. The median nerve was dissected and showed no abnormalities, whereas the brachial artery appeared scarred and narrowed. Intraoperative angiography confirmed a long-segment filiform stenosis of the brachial artery. A vascular surgeon then performed a vein-patch angioplasty of the narrowed artery using a cephalic vein graft from the same arm to guarantee sufficient flow to peripheral segments. Repeated angiography showed sufficient flow in the brachial artery, but insufficient flow in the radial artery. After a secondary thrombectomy during the same surgery, the radial artery showed sufficient backflow, and unrestricted flow was indicated by angiography (figure 2). The heparin therapy was continued for 2 days and then switched to dual antiplatelet therapy (aspirin plus platelet P2Y<sub>12</sub> receptor blocker) for 4 weeks.

### OUTCOME AND FOLLOW-UP

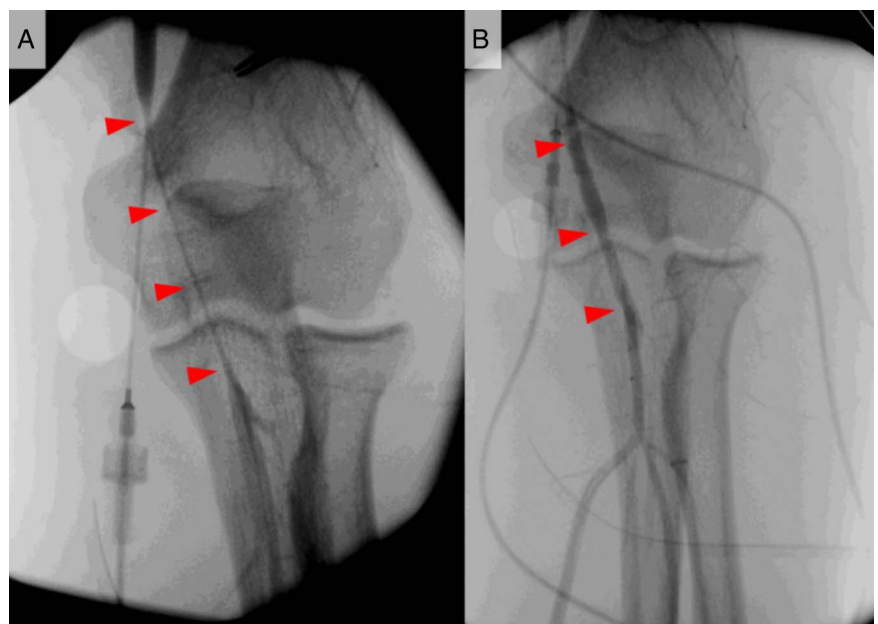
Postoperative immobilisation was continued for 6 weeks and passive guided movements were performed through physical therapy after 3 weeks, before rehabilitation was intensified. Follow-up investigations showed satisfactory healing of the ligament injuries, and Doppler sonography showed normal flow in both the brachial and the radial arteries. The range of elbow movement was 10/0/140° (Ext./Flex.) and 80/0/80° (Pro./sup.)

after 16 weeks and the Mayo Elbow Performance Score was excellent (>90). Resumption of sport-specific load was started 6 months after surgery. The patient reported no pain under rest and only a slight discomfort during sports. One year after surgery, the patient had almost regained his preinjury climbing level, was free of symptoms and the range of elbow movement was excellent (Mayo Elbow Performance Score >90). Another 5 months later, the patient presented again in our outpatient clinic reporting about a feeling of instability during climbing and bouldering after a second fall on the same arm. Clinical investigation confirmed a medial sided instability (valgus laxity), which was treated with a reconstruction of the collateral ligament system using a cork-screw. The patient was finally free of symptoms, regained his preinjury climbing level and the elbow movement was excellent (Mayo Elbow Performance Score >90).

### DISCUSSION

In a retrospective analysis of 911 rock climbing and bouldering injuries, our group recently showed that injuries of the forearm and the elbow are common injuries in this sport (9.1% of all injuries).<sup>6</sup> As falls onto the hands and arms occur regularly, especially in bouldering, it is understandable that dislocations of the elbow are occasionally seen. Different studies have recommended a surgical treatment in cases of torn ligaments causing a general instability of the elbow.<sup>7 8</sup> As recently highlighted by Ayel *et al*<sup>1</sup> who analysed published case reports and case series, this injury is accompanied by arterial lesions in 0.3–1.7% of all cases. This can be explained by the close anatomic proximity of the brachial artery to the joint. While in many of the published cases the arterial damage was presenting as a (sub) total rupture of the vessel with restricted peripheral circulation, our patient had no symptoms of ischaemia at all and pulses were easily palpable. MRI, which was performed several days after the trauma, did not show any distinct vessel injury, although a diffuse haematoma was detected within the biceps and brachial muscle. It cannot be finally determined whether the arterial damage was caused by the initial dislocation of the joint or secondary to the compression by the haematoma, as no further precise examination of the vascular situation had been made in

**Figure 2** Intraoperative angiography images of the brachial artery 3 weeks after acute elbow dislocation. (A) Filiform stenosis of the brachial artery with reduced flow (arrowheads). (B) Brachial artery with patent lumen after vein-patch angioplasty (arrowheads).



the primary hospital. However, as angiography and surgical examination did not show a total occlusion, dissection or disruption of the vessel, we believe that the filiform stenosis was caused by a compression of the haematoma and/or a thrombosis following the trauma. As the periarticular arterial collateral system is relatively strong, a radial pulse and sufficient oxygenation of the forearm and the hand can often be detected even if the brachial artery is acutely occluded or disrupted.<sup>9</sup> However, swelling of the periarticular tissue can cause compression on the collateral network after the trauma, which sometimes induces a delayed ischaemia.<sup>1</sup> Initial assessment of the vascular system and repetitive controls are therefore required to avoid severe damages due to hypoxia or structural changes.

In contrast to the formerly recommended ligation of the affected vessel,<sup>9</sup> today's standard procedure is rapid recanalisation of the occluded or disrupted artery to avoid secondary ischaemia or ischaemic symptoms under exercise.<sup>1</sup>

In both cases, with or without acute ischaemia, the surgical treatment consists of stabilisation of the joint and

re-establishment of sufficient circulation. Most authors therefore recommend a saphenous vein graft, as the length and calibre of this vessel can be easily matched to the given circumstances;<sup>10</sup> furthermore, this vein graft is easily accessible. In our case, in which the initial trauma had occurred several weeks before, the vascular surgeon decided to use a cephalic vein graft from the same arm to avoid a second incision.

**Acknowledgements** The authors thank Rosamunde Pare for English language support.

**Competing interests** None declared.

**Patient consent** Obtained.

**Provenance and peer review** Not commissioned; externally peer reviewed.

### Learning points

- ▶ In cases of elbow dislocations, arterial vascularisation should be systematically assessed (eg, duplex sonography), even if peripheral circulation seems to be unaffected and radial/ulnar pulses are palpable.
- ▶ If duplex sonography shows unclear results, an angiography should be performed to provide clarification.
- ▶ Intraoperative examination of the nerve-vessel bundle is obligatory. If unclear, an intraoperative angiography should be performed.
- ▶ Duplex sonography should be repeated in follow-up investigations as arterial damages can arise with delay.

### REFERENCES

- 1 Ayel JE, Bonneville N, Lafosse JM, *et al.* Acute elbow dislocation with arterial rupture. Analysis of nine cases. *Orthop Traumatol Surg Res* 2009;95:343–51
- 2 Hajji R, Zihni Y, Naouli H, *et al.* Brachial artery injury following opened elbow dislocation associated with accessory brachial artery: two rare entities in a 17-year-old girl: case report. *Pan Afr Med J* 2015;20:265
- 3 Martin DJ, Fazzi UG, Leach WJ. Brachial artery transection associated with closed and open dislocation of the elbow. *Eur J Emerg Med* 2005;12:30–2.
- 4 Platz A, Heinzelmann M, Ertel W, *et al.* Posterior elbow dislocation with associated vascular injury after blunt trauma. *J Trauma* 1999;46:948–50.
- 5 Thomas LG, Williams DT. Simple posterior elbow dislocation and brachial artery transection. *J R Army Med Corps* 2012;158:50–2.
- 6 Schoffl V, Popp D, Kupper T, *et al.* Injury trends in rock climbers: evaluation of a case series of 911 injuries between 2009 and 2012. *Wilderness Environ Med* 2015;26:62–7
- 7 Josefsson PO, Gentz CF, Johnell O, *et al.* Surgical versus nonsurgical treatment of ligamentous injuries following dislocations of the elbow joint. *Clin Orthop Relat Res* 1987;69:165–9.
- 8 O'Driscoll SW. Classification and evaluation of recurrent instability of the elbow. *Clin Orthop Relat Res* 2000;370:34–43.
- 9 Marcheix B, Chaufour X, Ayel J, *et al.* Transection of the brachial artery after closed posterior elbow dislocation. *J Vasc Surg* 2005;42:1230–2
- 10 Seidman GD, Koerner PA. Brachial artery rupture associated with closed posterior elbow dislocation: a case report and review of the literature. *J Trauma* 1995;38:318–21.

Copyright 2016 BMJ Publishing Group. All rights reserved. For permission to reuse any of this content visit <http://group.bmj.com/group/rights-licensing/permissions>.  
BMJ Case Report Fellows may re-use this article for personal use and teaching without any further permission.

Become a Fellow of BMJ Case Reports today and you can:

- ▶ Submit as many cases as you like
- ▶ Enjoy fast sympathetic peer review and rapid publication of accepted articles
- ▶ Access all the published articles
- ▶ Re-use any of the published material for personal use and teaching without further permission

For information on Institutional Fellowships contact [consortiasales@bmjgroup.com](mailto:consortiasales@bmjgroup.com)

Visit [casereports.bmj.com](http://casereports.bmj.com) for more articles like this and to become a Fellow