

# Reversed halo sign in cryptogenic organising pneumonia

Jesper Rømhild Davidsen, Helle Dall Madsen, Christian B Laursen

Department of Respiratory Medicine, Odense University Hospital, Odense, Denmark

## Correspondence to

Dr Jesper Rømhild Davidsen, [jesper.roemhild.davidsen@rsyd.dk](mailto:jesper.roemhild.davidsen@rsyd.dk)

Accepted 23 January 2016

## DESCRIPTION

A 60-year-old woman on no medication, with no obvious exposures and no extrapulmonary symptoms, was referred to diagnostic evaluation due to recurrent pneumonia-like episodes for 6 months. Broad biochemistry, autoimmunology and a body plethysmography were normal. Repeatable chest X-rays found diffuse migratory opacities of pneumonic appearance with mild fluor-18-deoxyglucose metabolic activity on a positron emission tomography scan. Bronchoalveolar lavage fluid revealed lymphocytosis of 57% with a CD4/CD8 ratio of 1.0, but with no signs of infection and no eosinophilia. Transbronchial biopsies were with unspecific inflammation. On suspicion of a hypersensitivity pneumonitis, a supplemental high-resolution CT was performed, which revealed an annular consolidation with central ground glass opacity, the so-called Atoll or reversed halo sign (RHS) (figure 1A, B).<sup>1-3</sup> Histopathological RHS represents a reaction pattern consisting of alveolar inflammation with peripheral fibrin precipitation and formation of granulation tissue, which is a hallmark of cryptogenic organising pneumonia (COP).<sup>4</sup> COP can occur secondary to drug reactions, bacterial and opportunistic infections including fungal infection, sarcoidosis and granulomatosis with polyangiitis, or as idiopathic COP when no apparent aetiology is found.<sup>5</sup> In this case, the latter was interpreted as the most likely cause during a multidisciplinary

team conference. On systemic steroid the patient improved clinically and the radiographic findings remitted fully in 4 months.

## Learning points

- ▶ Reversed halo sign or the Atoll sign on thoracic imaging can be pathognomonic with idiopathic cryptogenic organising pneumonia (COP), but can also be associated with infections, neoplasms and conditions including granulomatosis.
- ▶ On high-resolution CT, the reversed halo sign presents with an annular consolidation and central ground glass opacity.
- ▶ Findings of reversed halo sign and COP may lead to further examination of the underlying cause of its presence, as COP may have multiple aetiologies.

**Acknowledgements** The authors are thankful for the courtesy of Department of Radiology, Odense University Hospital, Denmark.

**Contributors** All the authors have clinically been in contact with the patient. JRD identified the special RHS on the patient's HRCT and wrote the first manuscript draft. HDM and CBL made critical revision to the manuscript, for important intellectual content. CBL made figure 1. All the authors have approved the final version. JRD is the guarantor.

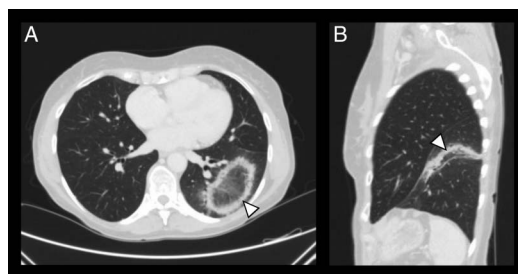
**Competing interests** None declared.

**Patient consent** Obtained.

**Provenance and peer review** Not commissioned; externally peer reviewed.

## REFERENCES

- 1 Hansell DM, Bankier AA, MacMahon H, *et al*. Fleischner Society: glossary of terms for thoracic imaging. *Radiology* 2008;246:697-722.
- 2 Maturu VN, Agarwal R. Reversed halo sign: a systematic review. *Respir Care* 2014;59:1440-9.
- 3 Marchiori E, Zanetti G, Hochegger B, *et al*. Reversed halo sign on computed tomography: state-of-the-art review. *Lung* 2012;190:389-94.
- 4 Cottin V, Cordier JF. Cryptogenic organizing pneumonia. *Semin Respir Crit Care Med* 2012;33:462-75.
- 5 Cagnina RE, Conces MR, Stoler MH, *et al*. Reversed halo sign. A case of cryptogenic organizing pneumonia with spontaneous resolution. *Am J Respir Crit Care Med* 2015;192:109-10.



**Figure 1** (A) Axial high-resolution CT image showing a characteristic reverse halo sign in the left lower lobe, with an annular consolidation and central presence of ground glass opacity. (B) Sagittal high-resolution CT image. The reversed halo sign in image A in this plane is present as a long-shaped opacity.



**To cite:** Davidsen JR, Madsen HD, Laursen CB. *BMJ Case Rep* Published online: [please include Day Month Year] doi:10.1136/bcr-2015-213779

Copyright 2016 BMJ Publishing Group. All rights reserved. For permission to reuse any of this content visit <http://group.bmj.com/group/rights-licensing/permissions>.  
BMJ Case Report Fellows may re-use this article for personal use and teaching without any further permission.

Become a Fellow of BMJ Case Reports today and you can:

- ▶ Submit as many cases as you like
- ▶ Enjoy fast sympathetic peer review and rapid publication of accepted articles
- ▶ Access all the published articles
- ▶ Re-use any of the published material for personal use and teaching without further permission

For information on Institutional Fellowships contact [consortiasales@bmjgroup.com](mailto:consortiasales@bmjgroup.com)

Visit [casereports.bmj.com](http://casereports.bmj.com) for more articles like this and to become a Fellow