

Ruptured intracranial dermoid cyst causing headache and meningism

Clare Thakker, Kristijonas Milinis, Ajay Sahu, Biga Gunawardana

Ealing Hospital, London, UK

Correspondence to
Dr Clare Thakker,
clare.thakker@nhs.net

Accepted 24 February 2016

DESCRIPTION

An 88-year-old man with Parkinson's disease was admitted to the hospital with chronic epididymo-orchitis. During his admission, he had a fall and suffered a head injury, with no loss of consciousness, no urinary incontinence and no tongue biting. Shortly after, he developed a generalised headache with no other features of raised intracranial pressure. On examination, he was found to

have nuchal rigidity but no focal neurological deficits. He was afebrile with stable vital signs and neurological observations. Inflammatory markers and electrolytes were normal.

Axial CT showed multiple areas of low density (minus 42 Hounsfield units) in the frontal and temporal lobes (figure 1). No acute intracranial haemorrhage was detected. Subsequently, coronal T1-weighted MRI (figure 2A), coronal T2 fluid-attenuated inversion recovery MRI (figure 2B) and axial T2 MRI (figure 2C) showed multiple high-intensity foci dispersed around the parasellar region, sylvian fissures and left lateral ventricle, suggestive of extra-axial fat droplets. These findings are typical for a ruptured dermoid cyst.

The patient was managed conservatively with analgesia and his symptoms abated.

Intracranial dermoid cysts are slow-growing tumours that account for <0.5% of all primary

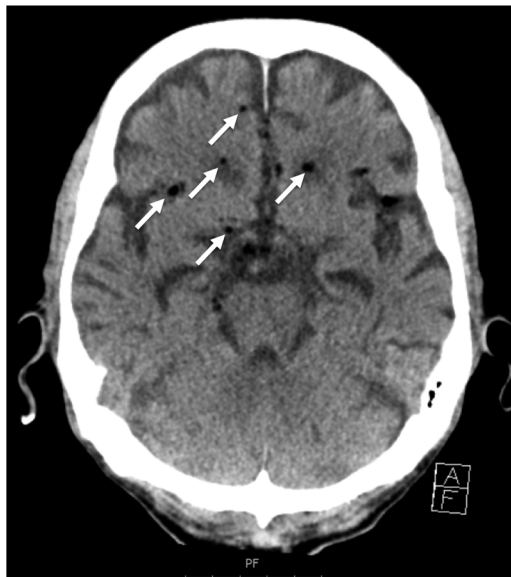

Figure 1 Axial non-contrast CT showing multiple low-density (minus 42 Hounsfield units) abnormalities (arrowed) in the frontal and temporal lobes, and in the parasellar region.

Learning points

- ▶ Dermoid cyst rupture is an uncommon cause of headache and meningism. Other presentations include seizures and hydrocephalus.
- ▶ Neuroimaging is important in patients presenting with headache and signs of meningism. The typical imaging appearance of a ruptured dermoid cyst on T1-weighted and T2-weighted MRI is of extra-axial hyperintense signal abnormalities distributed in the parasellar region.

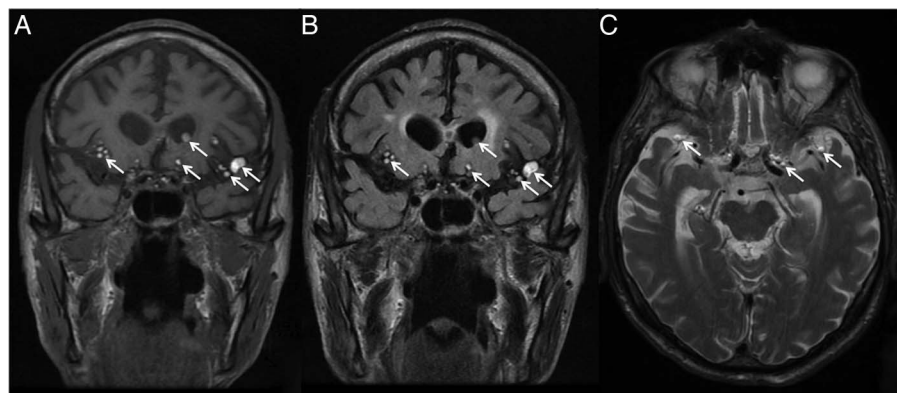


Figure 2 (A) Coronal MRI (T1 sequence) showing hyperintense signals (arrowed) in the parasellar region, sylvian fissures and left lateral ventricle. (B) Coronal T2 fluid-attenuated inversion recovery image showing hyperintense signals (arrowed) in a distribution corresponding to the T1 image along with bilateral periventricular areas of high signal best explained by small vessel disease. (C) Axial T2 image showing hyperintense signal (arrowed) in the parasellar region and anterior temporal lobes. These findings are consistent with extra-axial fat droplets.



To cite: Thakker C, Milinis K, Sahu A, et al. *BMJ Case Rep* Published online: [please include Day Month Year] doi:10.1136/bcr-2015-213527

intracranial tumours.¹ They arise from ectopic ectoderm incorporated into the neural tube as it closes. Intact cysts can present with mass effects or as incidental findings on imaging. Rupture is a rare event that presents most often with headache or seizure but can also cause aseptic chemical meningitis or hydrocephalus.² Head trauma can precipitate rupture, as in this case, however, spontaneous rupture is more usual.³

Contributors CT and KM cowrote the article. AS interpreted the scans for our article. BG took care of the patient and oversaw the writing of the article.

Competing interests None declared.

Patient consent Obtained.

Provenance and peer review Not commissioned; externally peer reviewed.

REFERENCES

- 1 Osborn AG, Preece MT. Intracranial cysts: radiologic-pathologic correlation and imaging approach. *Radiology* 2006;239:650–64.
- 2 Liu JK, Gottfried ON, Salzman KL, *et al.* Ruptured intracranial dermoid cysts: clinical, radiographic, and surgical features. *Neurosurgery* 2008;62:377–84; discussion 384.
- 3 El-Bahy K, Kotb A, Galal A, *et al.* Ruptured intracranial dermoid cysts. *Acta Neurochir (Wen)* 2006;148:457–62.

Copyright 2016 BMJ Publishing Group. All rights reserved. For permission to reuse any of this content visit <http://group.bmj.com/group/rights-licensing/permissions>.
BMJ Case Report Fellows may re-use this article for personal use and teaching without any further permission.

Become a Fellow of BMJ Case Reports today and you can:

- ▶ Submit as many cases as you like
- ▶ Enjoy fast sympathetic peer review and rapid publication of accepted articles
- ▶ Access all the published articles
- ▶ Re-use any of the published material for personal use and teaching without further permission

For information on Institutional Fellowships contact consortiasales@bmjgroup.com

Visit casereports.bmj.com for more articles like this and to become a Fellow