

Central retinal vein occlusion with cilioretinal artery occlusion in hyperhomocysteinemia

Vinod Kumar, Parijat Chandra, Atul Kumar

RP Centre, AIIMS, New Delhi, India

Correspondence to

Dr Vinod Kumar,
drvinod_agg@yahoo.com

Accepted 12 August 2015

DESCRIPTION

A healthy 27-year-old man presented with blurring in his right eye for 1 day. The left eye was normal. Visual acuity was 6/24 in the right eye with normal anterior segment. Fundus examination of the eye revealed mild disc oedema, retinal venous dilation and tortuosity and multiple retinal haemorrhages (figure 1A). A well-defined area of retinal whitening was seen in the macular area. Fluorescein angiogram (figure 1B) showed delayed venous filling and identified the cilioretinal artery (red arrow, figure 1B). A diagnosis of right eye central retinal vein occlusion (CRVO) with cilioretinal occlusion (CLAO) was made. Thorough systemic investigations and cardiac evaluation revealed no abnormality, but raised levels of serum homocysteine (23.2 $\mu\text{mol/L}$) were noted. The patient was advised intravitreal bevacizumab for macular oedema, in addition to vitamins B₁₂, B₆ and folic acid. At 1-month follow-up, the macular oedema had resolved and vision improved to 6/9.

CRVO in a patient older than 60 years of age with known systemic vascular risk factor does not warrant systemic work up. In a young patient with CRVO, however, an initial work up should consist of blood pressure, lipid profile, plasma glucose levels, erythrocyte sedimentation rate, antinuclear antibody and antiphospholipid antibody.

Hyperhomocysteinemia is an independent correctable risk factor for vascular disease and is a recognised risk factor for CRVO in young patients.¹ CLAO in the setting of CRVO is due to transient haemodynamic blockage resulting from increased pressure in the retinal capillary network.²

Learning points

- ▶ Hyperhomocysteinaemia is an important cause of central retinal vein occlusion (CRVO) in young patients and should be a part of systemic work up in such patients.
- ▶ Cilioretinal artery occlusion in the setting of CRVO is more of a physiological block than actual blockage of a blood vessel.

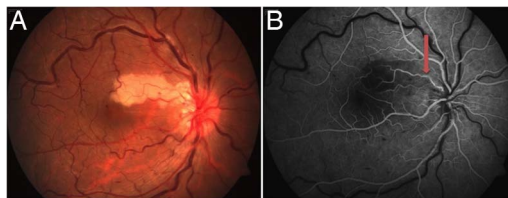


Figure 1 Fundus photograph of the right eye of the patient showing mild disc oedema, retinal venous dilation and tortuosity, scattered retinal haemorrhages, and well-defined area of retinal whitening between the disc and macula (A). Fluorescein angiogram of the right eye (B) showing area of hypofluorescence in relation to retinal whitening and normal filling of the cilioretinal artery (red arrow).

Competing interests None declared.

Patient consent Obtained.

Provenance and peer review Not commissioned; externally peer reviewed.

REFERENCES

- 1 Minniti G, Calevo MG, Giannattasio A *et al*. Plasma homocysteine in patients with retinal vein occlusion. *Eur J Ophthalmol* 2014;24:735–43.
- 2 Hayreh SS, Fraterrigo L, Jonas J. Central retinal vein occlusion associated with cilioretinal artery occlusion. *Retina* 2008;28:581–94.



CrossMark

To cite: Kumar V, Chandra P, Kumar A. *BMJ Case Rep* Published online: [please include Day Month Year] doi:10.1136/bcr-2015-212259

Copyright 2015 BMJ Publishing Group. All rights reserved. For permission to reuse any of this content visit <http://group.bmj.com/group/rights-licensing/permissions>.
BMJ Case Report Fellows may re-use this article for personal use and teaching without any further permission.

Become a Fellow of BMJ Case Reports today and you can:

- ▶ Submit as many cases as you like
- ▶ Enjoy fast sympathetic peer review and rapid publication of accepted articles
- ▶ Access all the published articles
- ▶ Re-use any of the published material for personal use and teaching without further permission

For information on Institutional Fellowships contact consortiasales@bmjgroup.com

Visit casereports.bmj.com for more articles like this and to become a Fellow