

# *Enterobius* granulomas as a cause of abdominal pain

Simon Rajendran,<sup>1</sup> Emma Carmody,<sup>2</sup> Micheal Murphy,<sup>3</sup> Brian Barry<sup>2</sup>

<sup>1</sup>Department of Surgery, Royal College of Surgeons, London, UK

<sup>2</sup>Department of Surgery, Bons Secours Hospital, Cork, Ireland

<sup>3</sup>Department of Radiology, Bons Secours Hospital, Cork, Ireland

## Correspondence to

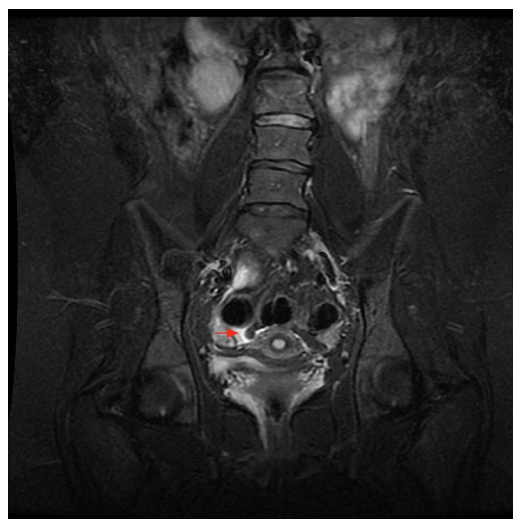
Dr Simon Rajendran,  
simonrajendran@gmail.com

Accepted 2 August 2015

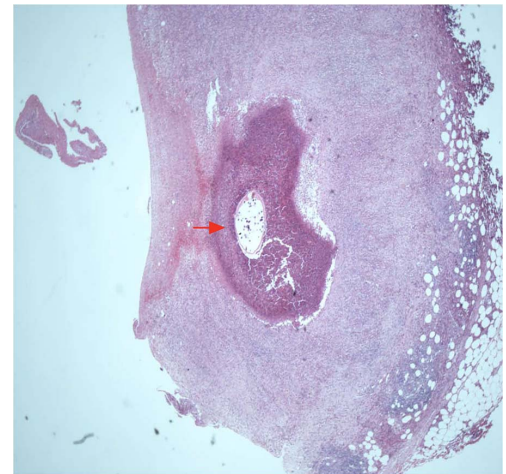
## DESCRIPTION

An 18-year-old woman presented with lower abdominal pain. Ultrasound (US) showed a dilated appendix. Laparoscopy revealed a mildly inflamed appendix with no other intra-abdominal abnormalities. Laparoscopic appendectomy was performed. Histology revealed serosal thickening with no transmural inflammation or intraluminal worms. The patient re-presented 9 days later. US showed a pericaecal collection and antibiotics were started. MRI demonstrated reduction in collection size. In addition, a small tubular structure deep in the pelvis, adjacent to the sigmoid colon, with no small bowel connection, was identified, with potential diagnosis of tortured appendix epiploicae (figure 1). Ongoing abdominal pain prompted laparoscopy, which confirmed a normal appendix stump and area of thickened fibrotic tissue, which was excised, in the pouch of Douglas. Histology revealed an inflamed fibrotic capsule containing inflammatory cells and pinworm (figure 2). Symptoms resolved following antihelminthic treatment.

*Enterobius vermicularis* species, or pinworms, are the most common infection-causing helminths. They predominantly colonise the gastrointestinal tract or, rarely, the female genital tract.<sup>1</sup> Pinworms are associated with appendicitis; however, obstruction of the appendiceal lumen remains controversial.<sup>2</sup> As pinworms cannot migrate through tissues, peritoneal cavity entry occurs either via fallopian tubes or during appendectomy.<sup>2</sup> Peritoneal cavity contamination can cause pelvic inflammatory disease, peritonitis or *Enterobius* granulomas.<sup>3</sup> The patient as well as all close contacts should be treated. This case highlights the usefulness of MRI in such cases, obviating radiation associated with



**Figure 1** Coronal fat suppressed MRI showing low signal tubular lesion (red arrow) deep in the pelvis, with surrounding high signal free fluid extending to contact the serosal surface of the sigmoid colon.



**Figure 2** Histological section showing *Enterobius vermicularis* (pinworm) present within intensely inflamed, fibrotic tissue containing eosinophils.

CT, and stresses the need for histological examination of all specimens and the need to consider pinworms, especially in endemic areas, during appendectomy, to minimise the risk of contamination and to initiate early treatment.

## Learning points

- ▶ *Enterobius vermicularis* infestation can mimic the symptoms of acute appendicitis.
- ▶ Peritoneal cavity contamination with pinworms can lead to pelvic inflammatory disease, abdominal peritonitis and *Enterobius* granulomas.
- ▶ The patient as well as all close contacts should be treated.

**Acknowledgements** The authors would like to thank Bons Secours Hospital, Cork, Ireland.

**Competing interests** None declared.

**Patient consent** Obtained.

**Provenance and peer review** Not commissioned; externally peer reviewed.

## REFERENCES

- 1 Gazvani MR, Emery SJ. Intra-peritoneal *Enterobius vermicularis* infection: a case report. *Infect Dis Obstet Gynecol* 1996;4:28–30.
- 2 Ariyathenam AV, Nachimuthu S, Tang TY, et al. *Enterobius vermicularis* infestation of the appendix and management at the time of laparoscopic appendectomy: case series and literature review. *Int J Surg* 2010;8:466–9.
- 3 Pampiglione S, Rivasi F. Enterobiasis in ectopic locations mimicking tumor-like lesions. *Int J Microbiol* 2009;2009:642481.



**To cite:** Rajendran S, Carmody E, Murphy M, et al. *BMJ Case Rep* Published online: [please include Day Month Year] doi:10.1136/bcr-2015-210464

Copyright 2015 BMJ Publishing Group. All rights reserved. For permission to reuse any of this content visit <http://group.bmj.com/group/rights-licensing/permissions>.  
BMJ Case Report Fellows may re-use this article for personal use and teaching without any further permission.

Become a Fellow of BMJ Case Reports today and you can:

- ▶ Submit as many cases as you like
- ▶ Enjoy fast sympathetic peer review and rapid publication of accepted articles
- ▶ Access all the published articles
- ▶ Re-use any of the published material for personal use and teaching without further permission

For information on Institutional Fellowships contact [consortiasales@bmjgroup.com](mailto:consortiasales@bmjgroup.com)

Visit [casereports.bmj.com](http://casereports.bmj.com) for more articles like this and to become a Fellow