

# Handstand induced visual loss: Valsalva retinopathy

Huw Oliphant, Christopher Holmes, Ali Hassan, Paul Baddeley

Department of Ophthalmology,  
Worthing Hospital, Worthing,  
West Sussex, UK

## Correspondence to

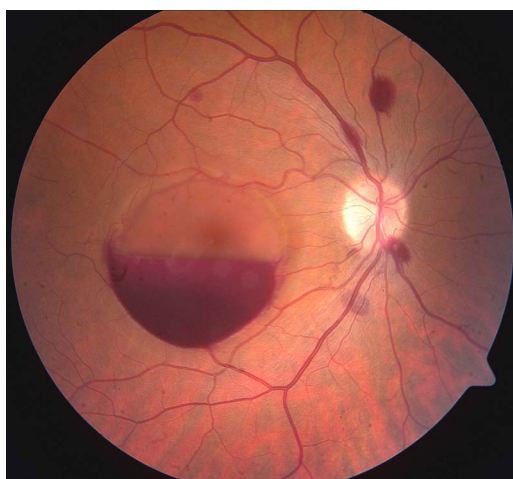
Dr Huw Oliphant,  
oliphanth@live.com

Accepted 18 November 2014

## DESCRIPTION

We present a case of a 32-year-old man who presented with a history of right-sided sudden visual loss, approximately 6 h following an intense workout session in the gymnasium. The patient had a history of having had refractive eye surgery approximately 18 months prior in both eyes. After completing a session of 'push-ups' in a handstand position, the patient subsequently developed a sudden visual loss in the right eye.

On presentation to the hospital eye service, he demonstrated visual acuity of 6/18 in the right eye, and vision of 6/5 in the left. The anterior segment was within normal limits, with no relative afferent papillary defect. Dilated funduscopy revealed a large pre-retinal macular haemorrhage and several scattered intraretinal haemorrhages (figure 1). A diagnosis of Valsalva retinopathy was made, and based on patient preference a decision was made to manage conservatively.



**Figure 1** Right fundus photograph, demonstrating Valsalva retinopathy. Large premacular haemorrhage and scattered intraretinal haemorrhages.

Valsalva retinopathy was first described in 1972, being a premacular haemorrhage following exhalation against a closed glottis.<sup>1</sup> This results in a sudden rise in intrathoracic pressure, which in turn leads to rupture of peri-foveal capillaries, giving the classic appearance demonstrated in figure 1. Valsalva retinopathy can often be managed conservatively, achieving favourable visual outcomes. Alternative management strategies can involve Nd:YAG laser to the posterior hyaloid, or vitrectomy.<sup>2</sup>

## Learning points

- ▶ To the best of our knowledge, this exact mechanism of developing Valsalva retinopathy has not previously been described.
- ▶ With 'boot-camp' style training sessions becoming ever more popular, it is a diagnosis non-specialists should consider following an intense physical exertion followed by sudden visual loss.
- ▶ Multiple management options are available, but ultimately conservative treatment will result in favourable visual outcome.

**Acknowledgements** The authors acknowledge Kevin Harrison for the retinal photograph.

**Contributors** HO came up with the idea for the manuscript, and was written in conjunction with AH and CH. PB was the supervising consultant.

**Competing interests** None.

**Patient consent** Obtained.

**Provenance and peer review** Not commissioned; externally peer reviewed.

## REFERENCES

- 1 Duane TD. Valsalva hemorrhagic retinopathy. *Trans Am Ophthalmol Soc* 1972;70:298–313.
- 2 Park JH, Sagong M, Chang W. Valsalva retinopathy following esophagogastroduodenoscopy under propofol sedation: a case report. *World J Gastroenterol* 2014;20:3056–8.



CrossMark

**To cite:** Oliphant H, Holmes C, Hassan A, et al. *BMJ Case Rep* Published online: [please include Day Month Year] doi:10.1136/bcr-2014-206733

Copyright 2014 BMJ Publishing Group. All rights reserved. For permission to reuse any of this content visit <http://group.bmj.com/group/rights-licensing/permissions>.  
BMJ Case Report Fellows may re-use this article for personal use and teaching without any further permission.

Become a Fellow of BMJ Case Reports today and you can:

- ▶ Submit as many cases as you like
- ▶ Enjoy fast sympathetic peer review and rapid publication of accepted articles
- ▶ Access all the published articles
- ▶ Re-use any of the published material for personal use and teaching without further permission

For information on Institutional Fellowships contact [consortiasales@bmjgroup.com](mailto:consortiasales@bmjgroup.com)

Visit [casereports.bmj.com](http://casereports.bmj.com) for more articles like this and to become a Fellow