

A rare cause of rash in elderly: diagnostic dilemma

Jagpal Singh Klair, Aneet Kaur, Latha M Achanta

Department of Internal Medicine, University of Arkansas for Medical Sciences, Little Rock, Arkansas, USA

Correspondence to
Dr Jagpal Singh Klair,
klairjagpal@yahoo.com

Accepted 14 June 2014

DESCRIPTION

Henoch-Schönlein purpura (HSP) is an immune-mediated vasculitis associated with IgA deposition within affected organs. It is the most common vasculitis in children; >90% of reported cases occurred in children <10 years old.¹ It is poorly described and under-recognised in adults. Approximately 70% of HSP cases in adults occur in men.¹ HSP is often preceded by an infection, such as a throat infection. The diagnostic criteria for HSP include palpable purpura plus (abdominal pain, biopsy showing predominant IgA deposition, arthritis/arthralgia or renal involvement (haematuria/proteinuria)).² The typical rash of HSP is

bilateral, symmetric, palpable purpura usually occurring on the legs and buttocks, but it can also be seen on the arms, face and trunk (figure 1A, B). Gastrointestinal symptoms, seen in up to 84% of patients, include nausea, vomiting and colicky abdominal pain.² Diagnosis is confirmed with a skin biopsy showing leucocytoclastic vasculitis with positive immunofluorescence of IgA (figure 1C, D), differentiating it from other causes of vasculitis in adults.¹ HSP is managed conservatively with hydration and NSAIDs for arthralgias. However, it does not prevent recurrence of the disease. The palpable purpura tends to relapse repeatedly over many months, but usually remits within 1 year of

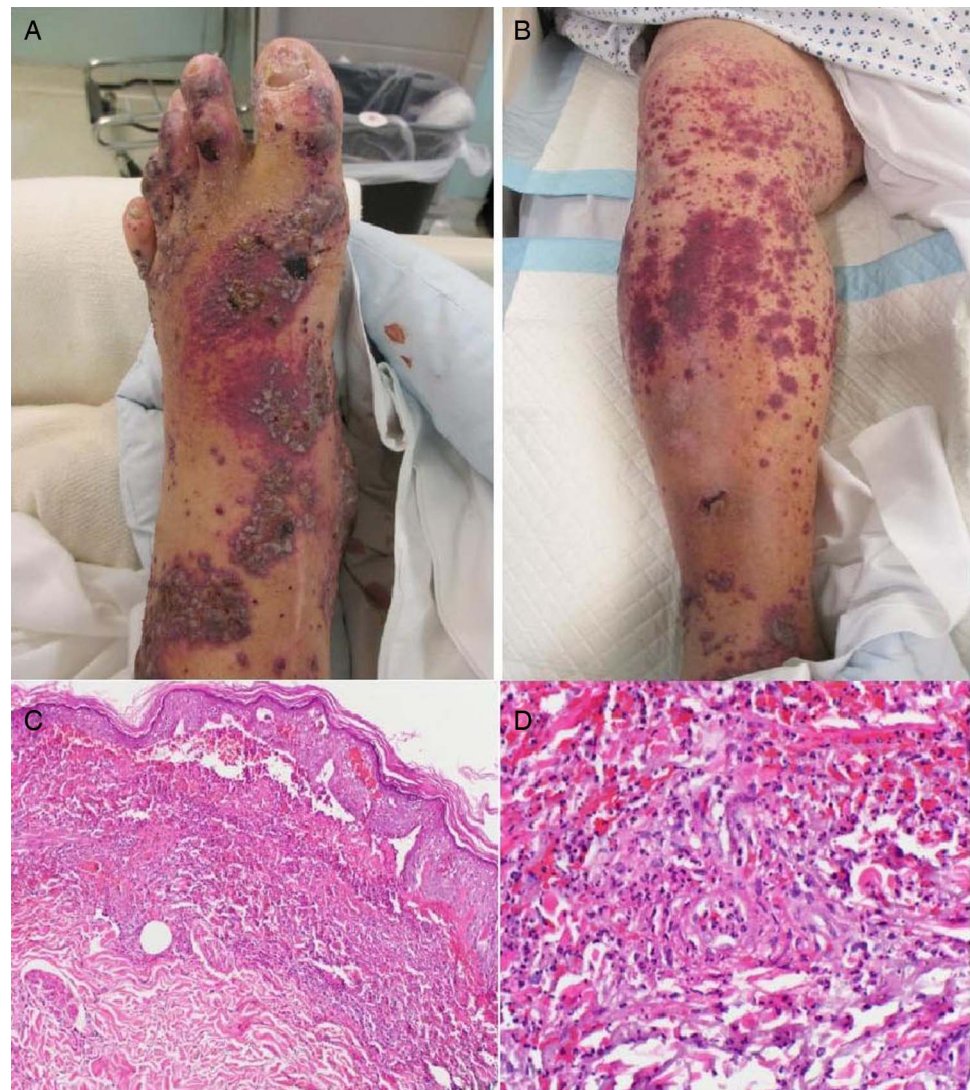


Figure 1 (A, B) Bilateral lower extremity purpuric rashes, some with necrotic centres, non-blanching lesions. (C, D) Bullous leucocytoclastic vasculitis; perivascular deposition of granular IgA and C3 with fibrin, consistent with IgA vasculitis Henoch-Schönlein purpura .



To cite: Klair JS, Kaur A, Achanta LM. *BMJ Case Rep* Published online: [please include Day Month Year] doi:10.1136/bcr-2014-205601

Learning points

- ▶ HSP is rare in adults and may be overlooked by practitioners who are unaware that this disease can occur at any age, thus leading to unnecessary investigations.
- ▶ HSP should be considered as a potential diagnosis in adults and the elderly presenting with skin vasculitis.
- ▶ Among adults, reported rates of end-stage renal disease range from 10—30% at 15 years and early diagnosis is required to prevent morbidity.

diagnosis. Systemic corticosteroids are used for the management of severe manifestations like renal or gastrointestinal disease as they can hasten recovery.³ Recurrence and relapse of HSP is

more common in adults and occurs in up to one-third of HSP patients; it is more likely among patients with renal involvement.³ Lastly, elderly patients with unexplained HSP should be screened for occult neoplasm or metastasis in known primary.²

Competing interests None.

Patient consent Obtained.

Provenance and peer review Not commissioned; externally peer reviewed.

REFERENCES

- 1 Reamy BV, Williams PM, Lindsay TJ. Henoch-Schönlein purpura. *Am Fam Phys* 2009;80:697–704.
- 2 Diehl MP, Harrington T, Olenginski T. Elderly-onset Henoch-Schönlein purpura: a case series and review of the literature. *J Am Geriatr Soc* 2008;56:2157–9.
- 3 Kellerman PS. Henoch-Schönlein purpura in adults. *Am J Kidney Dis* 2006;48:1009–16.

Copyright 2014 BMJ Publishing Group. All rights reserved. For permission to reuse any of this content visit <http://group.bmj.com/group/rights-licensing/permissions>.
BMJ Case Report Fellows may re-use this article for personal use and teaching without any further permission.

Become a Fellow of BMJ Case Reports today and you can:

- ▶ Submit as many cases as you like
- ▶ Enjoy fast sympathetic peer review and rapid publication of accepted articles
- ▶ Access all the published articles
- ▶ Re-use any of the published material for personal use and teaching without further permission

For information on Institutional Fellowships contact consortiasales@bmjgroup.com

Visit casereports.bmj.com for more articles like this and to become a Fellow