

'Doctor, treat your patient, not your monitor!' Tremor-induced ECG artefacts mimicking torsades de pointes

Antonio Mirijello, Mariella Fuorlo, Giovanni Addolorato, Raffaele Landolfi

Department of Internal Medicine, Catholic University of Rome, Rome, Italy

Correspondence to
Dr Antonio Mirijello,
antonio.mirijello@gmail.com

Accepted 3 April 2014

DESCRIPTION

A 70-year-old woman, affected by congestive heart failure, diabetes and chronic obstructive pulmonary disease, was admitted to our internal medicine unit because of dyspnoea. On physical examination a high-amplitude right upper extremity tremor was present. Blood electrolytes were normal.

ECG performed at admission showed wide QRS complexes, suggestive of ventricular tachycardia (VT) with the aspect of torsades de pointes (TdP;

figure 1). TdP is a polymorphic VT with the aspect of twisting QRS complex around the isoelectric baseline, clinically unstable. In this connection, intravenous magnesium-sulfate was administered. ECG electrodes were placed on the patient's shoulders. A subsequent ECG showed the disappearance of previous alterations (figure 2).

Ventricular arrhythmias are usually associated with haemodynamic instability (hypotension, chest pain, dyspnoea, syncope), while our patient did not show any of these signs.

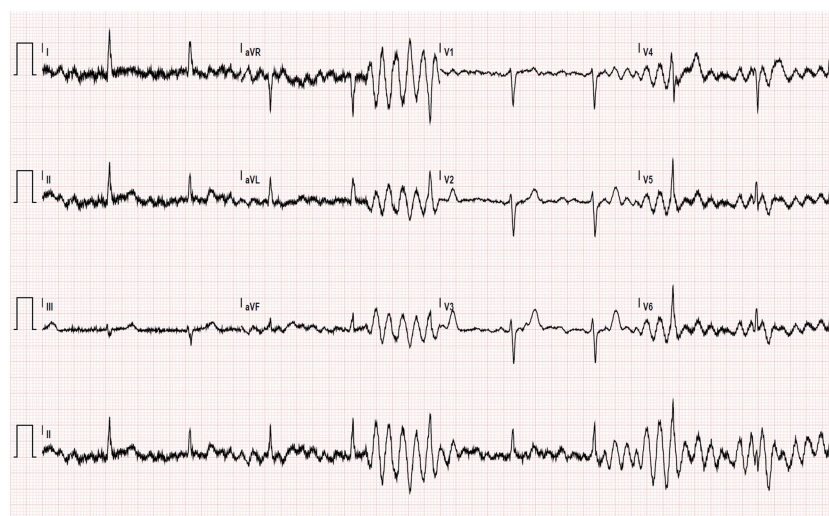

Figure 1 Twelve-leads ECG with the electrodes placed on arms extremities of the patient showing sinus rhythm with artefacts mimicking wide-QRS complex (torsades de pointes).

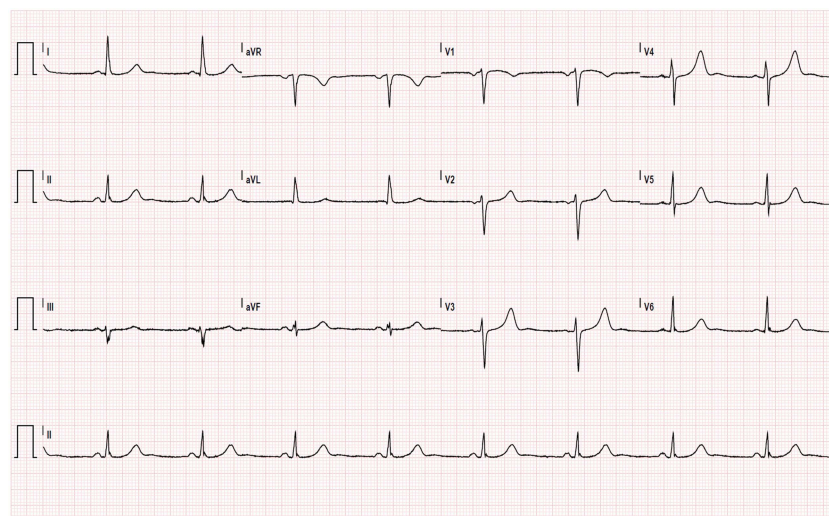
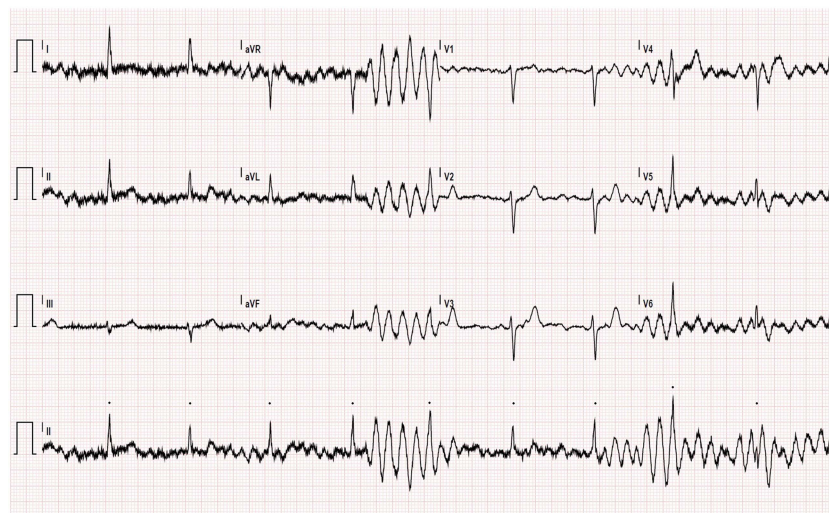

Figure 2 Twelve-leads ECG with the electrodes placed on shoulders of the patient showing sinus bradycardia.



To cite: Mirijello A, Fuorlo M, Addolorato G, et al. *BMJ Case Rep* Published online: [please include Day Month Year] doi:10.1136/bcr-2014-204735

Figure 3 Twelve-lead ECG showing rhythmic QRS complexes identifiable under the artefacts (bullets).



Abnormalities showed in figure 1 were ECG artefacts secondary to tremor; QRS complexes are identifiable under the artefacts (figure 3).

During the evaluation of an asymptomatic and haemodynamically stable patient, artefacts should always be considered as the cause of ECG abnormalities.

In our patient, a quick ECG overview suggested VT/TdP. However, on a deeper examination, QRS complexes were iden-

tifiable in the wide amplitude, repetitive electrical activity, particularly in lead II.

Tremor-induced ECG artefacts should always be considered when bizarre ECG changes are not associated with clinical signs or symptoms.¹ The concomitant auscultation with a stethoscope and palpation of the patient's pulse during ECG registration give clinical significance to ECG abnormalities.² In summary, physicians should treat the patient, not the monitor!

Contributors AM and MF managed the patient during hospitalisation. GA supervised the clinical management. All authors took part in the writing and revision process of the paper.

Competing interests None.

Patient consent Obtained.

Provenance and peer review Not commissioned; externally peer reviewed.

REFERENCES

- 1 Srikureja W, Darbar D, Reeder GS. Tremor-induced ECG artifact mimicking ventricular tachycardia. *Circulation* 2000;102:1337–8.
- 2 Smith RW, Unice RM, Chrisman L. Electrocardiographic artifact. *N Engl J Med* 2000;342:592.

Learning points

- ▶ ECG artefacts are frequently observed during ECG recording.
- ▶ Hearth auscultation and pulse palpation during ECG registration give clinical significance to ECG abnormalities (arrhythmia vs artefact).
- ▶ Physicians should treat the patient, not the monitor!

Copyright 2014 BMJ Publishing Group. All rights reserved. For permission to reuse any of this content visit <http://group.bmj.com/group/rights-licensing/permissions>. BMJ Case Report Fellows may re-use this article for personal use and teaching without any further permission.

Become a Fellow of BMJ Case Reports today and you can:

- ▶ Submit as many cases as you like
- ▶ Enjoy fast sympathetic peer review and rapid publication of accepted articles
- ▶ Access all the published articles
- ▶ Re-use any of the published material for personal use and teaching without further permission

For information on Institutional Fellowships contact consortiasales@bmjgroup.com

Visit casereports.bmj.com for more articles like this and to become a Fellow