

Spontaneous osteonecrosis of the knee: an unusual cause of knee pain

Raju Vaishya,¹ Vipul Vijay,¹ Abhishek Vaish²

¹Orthopaedic and Joint Replacement Surgery, Indraprastha Apollo Hospitals, New Delhi, India

²Department of Orthopaedics, Sancheti Hospital, Pune, Maharashtra, India

Correspondence to
Professor Raju Vaishya,
raju.vaishya@gmail.com

Accepted 9 April 2014

DESCRIPTION

A 40-year-old man presented with spontaneous onset of progressive pain in the left knee of 6 weeks duration which aggravated on strenuous activities. There was no history of trauma, steroids or alcohol intake. Local tenderness was elicited over the medial femoral condyle. Radiographs of the knee were unremarkable. MRI revealed a diffuse area of bone oedema which was hypointense on T1-weighted (figure 1) and hyperintense on T2-weighted images (figure 2). A diagnosis of spontaneous osteonecrosis of the knee (SONK) was made. He was advised non-weight bearing ambulation with crutches and diclofenac (150 mg/day) and sodium alendronate (70 mg once a week) for 8 weeks. The patient reported dramatic improvement.

SONK is characterised by sudden onset of spontaneous knee pain in the middle-aged and elderly. It was first described by Ahlbäck *et al* in 1968.¹ Recently, osteonecrosis of the knee has been further subclassified on the basis of its aetiology into three subcategories—spontaneous (idiopathic, no known risk factor), postsurgery (most commonly post arthroscopy) and secondary to systemic disease (eg, alcoholism, corticosteroid use, etc).² The final pathway in the development of SONK seems to be due to disturbance of microcirculation in the subchondral bone followed by necrosis and insufficiency fractures which lead to loss of support to the cartilage and collapse.³ Radiographs in early stages are unremarkable, but MRI shows a diffuse area of hyperintensity on T2-weighted images. Good outcomes have been reported with rest, use of bisphosphonates and non-steroidal anti-inflammatory drugs.⁴

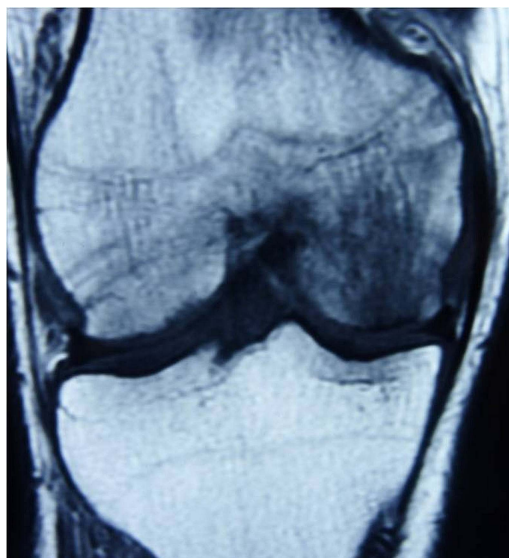


Figure 1 T1-weighted images of the MRI showing hypointense area involving the medial femoral condyle of the knee.

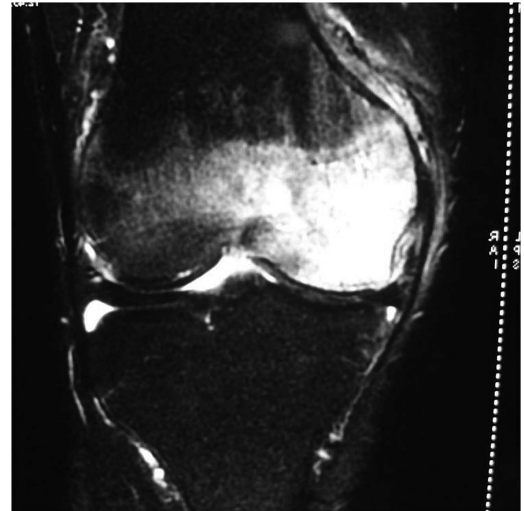

Figure 2 T2-weighted images of the MRI showing hyperintense area involving the medial femoral condyle of the knee and a visible fracture line in the subchondral bone.

Learning points

- ▶ Spontaneous osteonecrosis of the knee (SONK) is an uncommon cause of knee pain in middle-aged people, where plain radiographs are usually normal.
- ▶ MRI is the investigation of choice to diagnose SONK in the early stages.
- ▶ Rest to the knee, non-steroidal anti-inflammatory drugs and bisphosphonate therapy is usually effective in its management.

Contributors All the authors have contributed in preparing this manuscript.

Competing interests None.

Patient consent Obtained.

Provenance and peer review Not commissioned; externally peer reviewed.

REFERENCES

- 1 Ahlbäck S, Bauer GC, Bohne WH. Spontaneous osteonecrosis of the knee. *Arthritis Rheum* 1968;11:705–33.
- 2 Mont MA, Marker DR, Zywiell MG, *et al*. Osteonecrosis of the knee and related conditions. *J Am Acad Orthop Surg* 2011;19:482–94.
- 3 Yamamoto T, Bullough PG. Spontaneous osteonecrosis of the knee: the result of subchondral insufficiency fracture. *J Bone Joint Surg Am* 2000;82:858–66.
- 4 Meier C, Kraenzlin C, Friederich NF, *et al*. Effect of ibandronate on spontaneous osteonecrosis of the knee: a randomized, double-blind, placebo-controlled trial. *Osteoporos Int* 2014;25:359–66.



CrossMark

To cite: Vaishya R, Vijay V, Vaish A. *BMJ Case Rep* Published online: [please include Day Month Year] doi:10.1136/bcr-2014-204570

Copyright 2014 BMJ Publishing Group. All rights reserved. For permission to reuse any of this content visit <http://group.bmj.com/group/rights-licensing/permissions>.
BMJ Case Report Fellows may re-use this article for personal use and teaching without any further permission.

Become a Fellow of BMJ Case Reports today and you can:

- ▶ Submit as many cases as you like
- ▶ Enjoy fast sympathetic peer review and rapid publication of accepted articles
- ▶ Access all the published articles
- ▶ Re-use any of the published material for personal use and teaching without further permission

For information on Institutional Fellowships contact consortiasales@bmjgroup.com

Visit casereports.bmj.com for more articles like this and to become a Fellow