

Reverse redistribution pattern in rest Tl-201 and stress Tc-99m SPECT in patients undergoing coronary interventions

Naoya Matsumoto,¹ Shunichi Yoda,² Ken Nagao,¹ Atsushi Hirayama²

¹Department of Cardiology, Nihon University Surugadai Hospital, Tokyo, Japan

²Department of Cardiology, Nihon University School of Medicine, Tokyo, Japan

Correspondence to
Dr Naoya Matsumoto,
matsumoto.naoya@nihon-u.ac.jp

Accepted 27 March 2014

DESCRIPTION

A reverse redistribution pattern in rest thallium-201 (Tl)/stress technetium-99 m (Tc) tetrofosmin single photon emission CT (SPECT) is confusing. We present a myocardial perfusion SPECT in a 40-year-old patient undergoing coronary intervention in the left anterior descending coronary artery with an acute coronary syndrome. This pattern depicts a nearly normal perfusion in a resting Tl image and a perfusion defect in a stress Tc image, which indicates stress-induced ischaemia without significant coronary stenosis. This is frequently seen in patients who underwent an emergent reperfusion therapy. A nearly normal perfusion in a resting Tl image frequently changes into a perfusion defect mimicking a stress image in a 24 h delayed image (figure 1). This phenomenon can be explained by an excessive washout of Tl and Tc from the reperfused myocardium. Tl washout after reperfusion is well known as reverse redistribution.¹ Washout of Tc agent is also reported in reperfused myocardium.² In a rest Tl/stress Tc protocol, time course between the injection and imaging would be one of the reasons for reverse redistribution. A Tl/Tc protocol always requires rest-first imaging just after the Tl injection; this shorter time duration would not be enough for excessive washout. Therefore, a resting Tl image shows nearly normal perfusion. Conversely, post-stress images usually acquired 1 h after the injection for avoiding the emission of liver uptake. A 24 h delayed Tl image is enough to show reverse redistribution and it is an important

procedure which can prevent misinterpretation after emergent percutaneous coronary interventions.

Learning points

- ▶ Patients who underwent coronary interventions just after acute coronary syndrome show pseudoischaemic pattern in dual isotope single photon emission CT protocol.
- ▶ To avoid this technical misinterpretation, a 24 h delayed image of thallium is important.
- ▶ The reverse redistributed myocardium is usually recognised as a viable myocardium after reperfusion therapy.

Competing interests None.

Patient consent Obtained.

Provenance and peer review Not commissioned; externally peer reviewed.

REFERENCES

- 1 Akutsu Y, Kodama Y, Nishimura H, et al. Contractile reserve, thallium-201 reverse redistribution and mismatch between perfusion and metabolism in reperfused infarct-related myocardium with delayed and incomplete functional recovery. *Jpn Heart J* 2004;45:739–48.
- 2 Smith EJ, Hussain A, Manoharan M, et al. A reverse perfusion pattern during technetium-99m stress myocardial perfusion imaging does not predict flow limiting coronary artery disease. *Int J Cardiovasc Imaging* 2004;20:321–6.

Stress Tc, short axis

Rest Tl, short axis

24h-late Tl, short axis

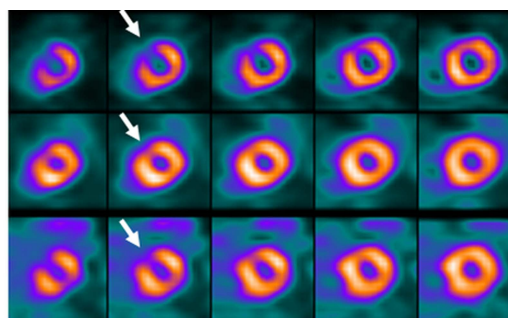


Figure 1 Upper line: technetium-99 m (Tc) short axis images at post-stress showing a distal anteroseptal perfusion defect. Middle line: thallium-201 (Tl) short axis images at rest showing nearly normal perfusion. These images are interpreted as an evidence of ischaemia. Lower line: 24 h late Tl images showing a reverse redistribution pattern in the same area of Tc short axis images. In comparison to the Tc images, the interpretation changed to non-reversible perfusion defect which indicated an infarcted myocardium without ischaemia.



CrossMark

To cite: Matsumoto N, Yoda S, Nagao K, et al. *BMJ Case Rep* Published online: [please include Day Month Year] doi:10.1136/bcr-2014-204325

Copyright 2014 BMJ Publishing Group. All rights reserved. For permission to reuse any of this content visit <http://group.bmj.com/group/rights-licensing/permissions>.
BMJ Case Report Fellows may re-use this article for personal use and teaching without any further permission.

Become a Fellow of BMJ Case Reports today and you can:

- ▶ Submit as many cases as you like
- ▶ Enjoy fast sympathetic peer review and rapid publication of accepted articles
- ▶ Access all the published articles
- ▶ Re-use any of the published material for personal use and teaching without further permission

For information on Institutional Fellowships contact consortiasales@bmjgroup.com

Visit casereports.bmj.com for more articles like this and to become a Fellow