

# A twist in the tale: epiploic appendagitis mimicking acute appendicitis

Adrian Matthew Shields,<sup>1</sup> Harry Dean,<sup>2</sup> Simon Atkinson<sup>2</sup>

<sup>1</sup>Department of Medicine, St Thomas' Hospital, London, UK

<sup>2</sup>Department of Surgery, St Thomas' Hospital, London, UK

## Correspondence to

Dr Adrian Matthew Shields, Department of Surgery, St Thomas' Hospital, London UK; adrianshields@doctors.org.uk

Accepted 8 May 2014

## DESCRIPTION

A 38-year-old woman with a history of endometriosis presented to hospital with a 24 h history of severe, stabbing right iliac fossa pain. On examination she was non-feverish and systemically well. Rebound tenderness was noted in the right iliac fossa without guarding. Urinalysis was positive for leucocytes but blood tests were unremarkable with the exception of a C reactive protein of 7.

CT of the abdomen was performed to elucidate the cause of her abdominal pain (figure 1). The CT revealed a 1.7 cm soft tissue nodule lying within the mesenteric fat anterior to the caecum with associated fat stranding. The appendix was seen to arise from the medial caecum and was not inflamed. The remaining viscera were of normal radiological appearance. A diagnosis of epiploic appendagitis was made.

The epiploic appendages are pedunculated, fat-filled outpouchings of the colon, averaging 3 cm in length. Epiploic appendagitis arises from torsion, ischaemia or haemorrhagic infarction of the epiploic appendages. Clinically, epiploic appendagitis presents as acute, localised abdominal pain without systemic symptoms. The diagnosis is typically made incidentally when CT is used to exclude other intra-abdominal pathologies.<sup>1</sup>

Epiploic appendages are not normally seen on CT. However, when inflamed they can appear as pericolic, fat density, oval lesions with surrounding inflammation. Occasionally, a central high-attenuation dot is visible representing haemorrhage. Fat stranding is generally more pronounced than adjacent colonic wall thickening. Right-sided or caecal appendagitis is comparatively rare with most presentations arising from the sigmoid colon, mimicking diverticulitis.<sup>2 3</sup>

The patient was managed conservatively and made a complete recovery.

## Learning points

- ▶ Epiploic appendagitis is an uncommon cause of acute abdominal pain but should be considered in patients without elevation in septic markers or systemic illness.
- ▶ Epiploic appendagitis is frequently diagnosed incidentally when CT of the abdomen is used to exclude other more serious causes of abdominal pain. CT findings are pathognomonic.
- ▶ Consideration of epiploic appendagitis in patients presenting with acute abdomen may help avoid unnecessary antibiotic therapy, laparoscopy and a prolonged hospital stay as management is most commonly conservative, with analgesia and anti-inflammatories.

**Contributors** AMS and HD were involved in writing the manuscript. SA was the consultant responsible for the patient's care and reviewed the manuscript.

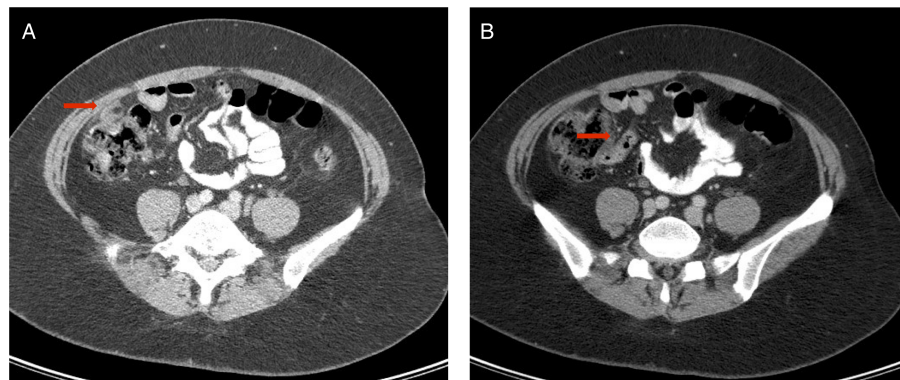
**Competing interests** None.

**Patient consent** Obtained.

**Provenance and peer review** Not commissioned; externally peer reviewed.

## REFERENCES

- 1 Legome EL, Belton AL, Murray RE, *et al*. Epiploic appendagitis: the emergency department presentation. *J Emerg Med* 2002;22:9–13.
- 2 Singh AK, Gervais DA, Hahn PF, *et al*. CT appearance of acute appendagitis. *AJR Am J Roentgenol* 2004;183:1303–7.
- 3 Almeida AT, Melao L, Viamonte B, *et al*. Epiploic appendagitis: an entity frequently unknown to clinicians—diagnostic imaging, pitfalls and look-alikes. *AJR Am J Roentgenol* 2009;193:1243–51.



**Figure 1** Axial CT of the abdomen performed on day 2 of admission. A fat density, 1.7 cm nodule can be seen overlying the anterior caecum with associated fat stranding corresponding to an inflamed epiploic appendage (A). The appendix is of normal radiological appearance and arises from the medial caecum (B).



**To cite:** Shields AM, Dean H, Atkinson S. *BMJ Case Rep* Published online: [please include Day Month Year] doi:10.1136/bcr-2013-203055

Copyright 2014 BMJ Publishing Group. All rights reserved. For permission to reuse any of this content visit <http://group.bmj.com/group/rights-licensing/permissions>.  
BMJ Case Report Fellows may re-use this article for personal use and teaching without any further permission.

Become a Fellow of BMJ Case Reports today and you can:

- ▶ Submit as many cases as you like
- ▶ Enjoy fast sympathetic peer review and rapid publication of accepted articles
- ▶ Access all the published articles
- ▶ Re-use any of the published material for personal use and teaching without further permission

For information on Institutional Fellowships contact [consortiasales@bmjgroup.com](mailto:consortiasales@bmjgroup.com)

Visit [casereports.bmj.com](http://casereports.bmj.com) for more articles like this and to become a Fellow