

# Infectious pacemaker exteriorisation

Uday Yanamandra,<sup>1</sup> Sushma Yanamandra,<sup>2</sup> Navreet Singh,<sup>3</sup> Velu Nair<sup>4</sup>

<sup>1</sup>Department of Internal Medicine, Armed Forces Medical College, Pune, Maharashtra, India

<sup>2</sup>Department of Medicine, CAIMS, Karimnagar, Andhra Pradesh, India

<sup>3</sup>Department of Cardiology, Army Hospital Research & Referral, New Delhi, India

<sup>4</sup>Armed Forces Medical College, Pune, Maharashtra, India

## Correspondence to

Dr Uday Yanamandra, udayj2@gmail.com

## DESCRIPTION

A 68-year-old man who 1 year previously had been fitted with a permanent pacemaker implantation (PPI) for symptomatic sinus bradycardia was admitted with recurrent syncope and intermittent moderate-grade fever for 2 months. He was on intermittent antibiotics from rural health centre for the same duration with no improvement in his condition.

On examination, he was frail with exteriorisation of the pacemaker (figure 1) with pus exuding from the pacemaker pocket. Transoesophageal echocardiography revealed subvalvular vegetation suggestive of subacute bacterial endocarditis (SBE). All other haematological and biochemical parameters were normal. Pus culture from the pocket revealed Gram-positive cocci in groups sensitive to  $\beta$ -lactams and vancomycin. Repeated blood cultures were sterile. He was managed with removal of pacemaker/leads, management of SBE with antibiotics (vancomycin with ceftriaxone) for 3 weeks, transient glycopyrrolate/external pacemaker management and replacement of pacemaker on a later date on opposite side.

Pacemaker pocket erosion caused by generator is usually a result of pocket infection which later leads to exteriorisation of the pacemaker. It is a rare complication of PPI (incidence <1%) commonly seen in elderly patients with decreased subcutaneous fat/fragile skin, PPI in a small pocket, use of harsh/strong disinfectants with increased

scrubbing and prolonged steroid intake.<sup>1</sup> Exteriorisation obligates intense antibiotics therapy and removal of the pacemaker owing to bacterial contamination and its intravascular/intracardiac spread through pacemaker leads.<sup>2</sup>

Prophylactic anti-staphylococcal antibiotic treatment during implantation may prevent not only PPI infections but also pacemaker exteriorisation linked to hidden infections.<sup>3</sup>

## Learning points

- ▶ Pacemaker exteriorisation is commonly an aftermath of implantation site infection.
- ▶ Infection can spread through the leads of exteriorised pacemaker to blood stream.
- ▶ Immediate removal of the device is essential in such cases.

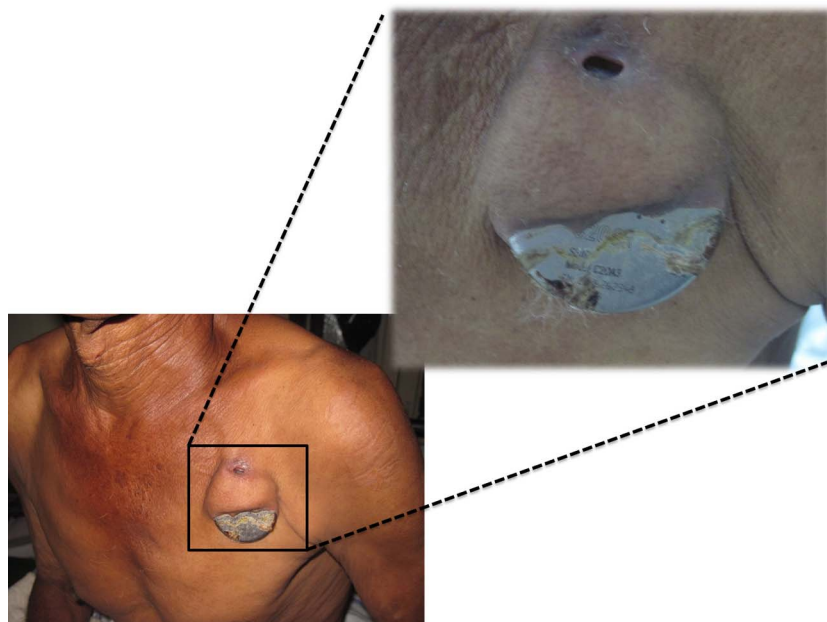
**Acknowledgements** We would like to thank the O/o DGAFMS for all the cooperation.

**Contributors** All authors were involved in managing and preparing the manuscript.

**Competing interests** None.

**Patient consent** Obtained.

**Provenance and peer review** Not commissioned; externally peer reviewed.



**Figure 1** Exteriorised pacemaker in a case of implantation site infection leading to skin necrosis.



**To cite:** Yanamandra U, Yanamandra S, Singh N, et al. *BMJ Case Rep* Published online: [please include Day Month Year] doi:10.1136/bcr-2013-202893

## REFERENCES

- 1 Kabayadondo MG, de Meester A. Early complications after pacemaker implantations, cardiac pacemakers—biological aspects, clinical applications and possible complications, Edited by Mart M; 2011:161–80. InTech, doi:10.5772/20091. Available from: <http://www.intechopen.com/books/cardiac-pacemakers-biological-aspects-clinical-applications-and-possible-complications/> early-complications-after-pacemaker-implantations. ISBN 978-953-307-639-3.
- 2 Bru P, Cointe R, Metge M, *et al.* Value of systematic preventive antibiotherapy in cardiac pacemaker implantation. *Ann Cardiol Angeiol (Paris)* 1991;40:171–4.
- 3 Klug D, Wallet F, Lacroix D, *et al.* Local symptoms at the site of pacemaker implantation indicate latent systemic infection. *Heart* 2004;90:882–6.

Copyright 2014 BMJ Publishing Group. All rights reserved. For permission to reuse any of this content visit <http://group.bmj.com/group/rights-licensing/permissions>.

BMJ Case Report Fellows may re-use this article for personal use and teaching without any further permission.

Become a Fellow of BMJ Case Reports today and you can:

- ▶ Submit as many cases as you like
- ▶ Enjoy fast sympathetic peer review and rapid publication of accepted articles
- ▶ Access all the published articles
- ▶ Re-use any of the published material for personal use and teaching without further permission

For information on Institutional Fellowships contact [consortiasales@bmjgroup.com](mailto:consortiasales@bmjgroup.com)

Visit [casereports.bmj.com](http://casereports.bmj.com) for more articles like this and to become a Fellow