



Editor's choice  
Scan to access more  
free content

## CASE REPORT

## Amoeboma: resurfacing of a vanishing illness

Vinoth Boopathy,<sup>1</sup> Thomas Alexander,<sup>1</sup> Padhmini Balasubramanian,<sup>2</sup> Manjiri Phansalkar<sup>3</sup>

<sup>1</sup>Department of Gastroenterology, Pondicherry Institute of Medical Sciences, Pondicherry, India

<sup>2</sup>Department of Radiology, Pondicherry Institute of Medical Sciences, Pondicherry, India

<sup>3</sup>Department of Pathology, Pondicherry Institute of Medical Sciences, Pondicherry, India

**Correspondence to**  
Dr Vinoth Boopathy,  
drvinoth@gmail.com

Accepted 11 April 2014

## SUMMARY

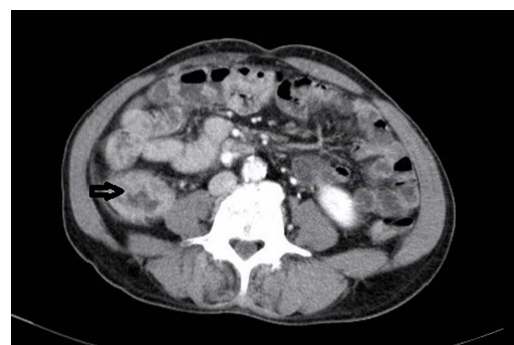Amoeboma is a rare manifestation of intestinal amoebiasis. More than 90% of patients with intestinal amoebiasis have a history of diarrhoea. This report describes the case of a 60-year-old patient who presented with a right iliac fossa (RIF) mass with normal bowel habits and was eventually diagnosed with an amoeboma. In developing countries, a traditional differential diagnosis for an RIF mass is an amoeboma, but its incidence is declining. Hence this treatable condition is often overlooked in the differential diagnosis of an RIF mass. This case report emphasises that amoeboma still exists and should be considered in a patient with an RIF mass.

## BACKGROUND

Amoeboma is a tumour-like mass involving the whole thickness of the bowel wall and is a rare manifestation of amoebiasis. Many case reports describe amoeboma diagnosed only in the surgical specimen after surgery to treat malignancy. Hence it is extremely important to consider the possibility of amoeboma in any patient with a right iliac fossa mass, although its incidence seems to be declining. Furthermore, it is essential to keep the differential diagnosis of amoebiasis in mind even among those without colonic symptoms, as in our patient.

## CASE PRESENTATION

A 60-year-old man attended our outpatient clinic with the chief complaints of right lower quadrant pain and fever of 4 days' duration. There was no history of diarrhoea or the passage of blood or mucus in the stools. General examination was unremarkable, but physical examination of the abdomen revealed a 4×3 cm firm, tender, mobile lump in the right lower quadrant. Blood investigations showed an elevated leucocyte count of 12 900. Ultrasonography (USG) of the abdomen, which had been performed elsewhere, showed thickening of the caecal and ascending colon wall. A contrast-enhanced CT of the abdomen at our institution confirmed the USG findings (figure 1). Colonoscopy showed ulcerations starting from the hepatic flexure and extending down to involve the ascending colon, caecum and the ileocaecal valve, with yellowish white exudates overlying the ulcers (figure 2). The rest of the colon including the rectum was normal. Biopsy of the involved areas of the colon revealed multiple trophozoites of *Entamoeba histolytica* (figure 3). The patient was started on treatment with parenteral metronidazole and within 48 h there was a dramatic response with resolution of symptoms and the beginning of a



**Figure 1** CT scan of the abdomen showing irregular wall thickening of the caecum.

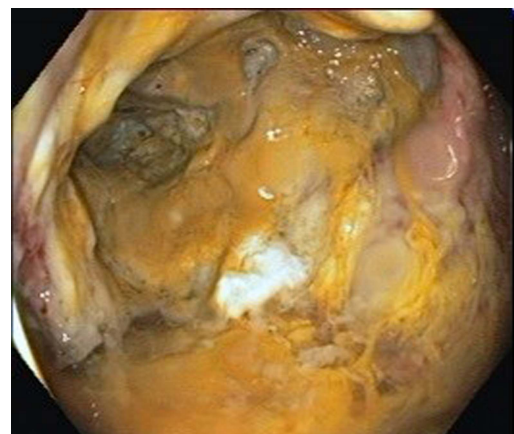
decrease in mass size; the mass had completely disappeared by discharge 7 days later. Despite repeated questioning until discharge, the patient was emphatic that he had never experienced an episode of diarrhoea during the previous year.

## OUTCOME AND FOLLOW-UP

Patient is still being followed up and has been totally asymptomatic for the past 2 years.

## DISCUSSION

Amoebiasis is caused by the protozoan parasite *E. histolytica*. The infection is acquired by ingestion of food and water contaminated with cysts of the organism. Each cyst after ingestion develops into eight trophozoites in the small intestine. The trophozoites then invade the colonic epithelium and can access the blood stream and infect various organs. Most infections are either mild or

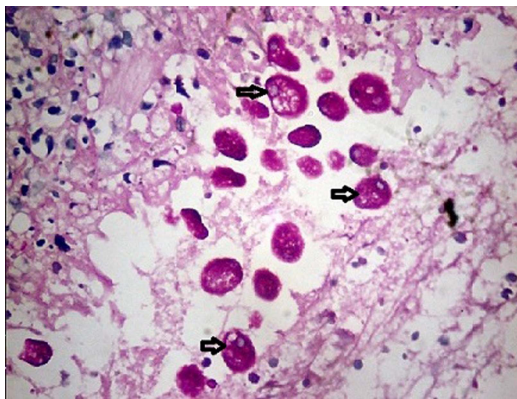


**Figure 2** Colonoscopic image showing ulcerations with yellowish white exudations in the caecum.



CrossMark

**To cite:** Boopathy V, Alexander T, Balasubramanian P, et al. *BMJ Case Rep* Published online: [please include Day Month Year] doi:10.1136/bcr-2013-202616



**Figure 3** Periodic acid–Schiff stain depicting multiple trophozoites of *Entamoeba histolytica* (arrows).

asymptomatic, with only 10% of patients developing invasive amoebiasis. Some of the risk factors identified for the development of invasive amoebiasis include young age, pregnancy, glucocorticosteroid ingestion, malignancy, malnutrition and alcoholism.<sup>1 2</sup> The colon and the liver are the most commonly affected organs. In the colon, trophozoites of the parasite generally invade the mucosa and cause ulceration, which is typically described as flask-shaped because of lateral extension. Rarely, an exophytic, ulcerated inflammatory mass mimicking a malignancy can develop. This is known as an amoeboma and was a well-known, although infrequent clinical entity that appears to be declining in frequency. In a study by Cardoso *et al*,<sup>3</sup> the incidence of amoeboma was found to be 1.5% among patients with invasive amoebiasis. However, recent references to an amoeboma are extremely scarce and only in the form of anecdotal case reports. A possible reason for this decline might be improved sanitation and hygiene and also the indiscriminate use of imidazoles.

The commonest location for an amoeboma is the caecum. The most common clinical differential diagnoses include an appendicular mass, colonic malignancy or Crohn's disease. Although the history was very short and hence atypical, a caecal malignancy was the working diagnosis in our patient. Colonoscopic findings in intestinal amoebiasis are non-diagnostic; erythaema, oedema, myriad ulcers as in ulcerative colitis, and punctate ulcers separated by relatively normal mucosa and with a 'poached egg' appearance, can be seen.<sup>4 5</sup> The gold standard for diagnosing amoebic colitis is the performance a colonoscopy and demonstration of trophozoites of *E. histolytica* in tissue biopsies taken from the lesions seen on endoscopy. Identification of the organism is better on periodic acid–Schiff staining of the biopsy specimen, which stains trophozoites magenta. Other non-invasive methods for diagnosing intestinal amoebiasis include demonstration of trophozoites with ingested erythrocytes (haematophagous trophozoites) in stool

samples, serum anti-amoebic antibody, PCR and ELISA that can detect amoebic lectin antigen in stool samples, and a stool culture with isoenzyme analysis. Stool ELISA for amoebic lectin is the most specific clinically available test and has a sensitivity of 85% and specificity of 90% in a freshly prepared stool sample. Stool microscopy is unreliable (sensitivity of 60%) and is affected by storage of the stool sample.

Amoeboma can be managed medically with a course of amoebicidal drugs such as metronidazole given for 10–14 days. However, amoebomas are most often diagnosed only in the surgical specimens of patients following surgery for a presumptive diagnosis of malignancy. Hence it is extremely important that amoeboma should always diagnosed preoperatively so that surgery can be avoided in most of these medically treatable cases.<sup>6</sup> In our patient, the mass completely disappeared within 7 days of initiation of a 14-day course of metronidazole, which the patient completed.

### Learning points

- ▶ Amoeboma is a rare entity that is seldom considered nowadays in patients presenting with an abdominal mass.
- ▶ Our case demonstrates that amoeboma stills exists and should be a differential diagnosis in any patient with an abdominal mass.
- ▶ The diagnosis of amoebiasis should be considered even in patients without a recent history of diarrhoea.

**Acknowledgements** We would like to acknowledge Dr George Kurian, the head of the Department of Gastroenterology and the faculties of radiology and pathology who helped us with this patient.

**Contributors** TA and VB are the treating physicians. TA wrote the manuscript with help of PB and MP. VB edited and finalised the manuscript.

**Competing interests** None.

**Patient consent** Obtained.

**Provenance and peer review** Not commissioned; externally peer reviewed.

### REFERENCES

- 1 Leder K, Weller PF. Intestinal *Entamoeba histolytica* amebiasis. *UpToDate*, 11 Sept 2012. <http://www.uptodate.com/contents/intestinal-entamoeba-histolytica-amebiasis>
- 2 Mhlanga BR, Lanoie LO, Norris HJ, Lack EE, *et al*. Amoebiasis complicating carcinomas: a diagnostic dilemma. *AMJ Trop Med Hyg* 1992;46:759–64.
- 3 Cardoso JM, Kimura K, Stooen M, *et al*. Radiology of invasive amoebiasis of the colon. *Am J Roentgenol* 1977;128:935–41.
- 4 Misra SP, Misra V, Dwivedi M. Ileocaecal masses in patients with amebic liver abscess: etiology and management. *World J Gastroenterol* 2006;12:1933–6.
- 5 Upadhyay R, Gupta N, Gogia P, *et al*. Poached egg appearance in intestinal amebiasis. *Gastrointest Endosc* 2012;76:189–90.
- 6 Zapata L, Flores R, Jurado JJ, *et al*. Success of medical therapy in a rare case of cecal ameboma. *Rev Gastroenterol Mex* 2011;76:55–9.

Copyright 2014 BMJ Publishing Group. All rights reserved. For permission to reuse any of this content visit <http://group.bmj.com/group/rights-licensing/permissions>.  
BMJ Case Report Fellows may re-use this article for personal use and teaching without any further permission.

Become a Fellow of BMJ Case Reports today and you can:

- ▶ Submit as many cases as you like
- ▶ Enjoy fast sympathetic peer review and rapid publication of accepted articles
- ▶ Access all the published articles
- ▶ Re-use any of the published material for personal use and teaching without further permission

For information on Institutional Fellowships contact [consortiasales@bmjgroup.com](mailto:consortiasales@bmjgroup.com)

Visit [casereports.bmj.com](http://casereports.bmj.com) for more articles like this and to become a Fellow