

A solitary osteochondroma of the scapula

Raju Vaishya,¹ Shankar Dhakal,² Abhishek Vaish³

¹Department of Orthopaedic and Joint Replacement Surgery, Indraprastha Apollo Hospitals, New Delhi, India

²Department of Orthopaedics, Chitwan Medical College, Bharatpur, Nepal

³Department of Orthopaedics, Sancheti Hospital, Pune, Maharashtra, India

Correspondence to
Professor Raju Vaishya,
raju.vaishya@gmail.com

Accepted 3 February 2014

DESCRIPTION

Osteochondromas (exostosis) are commonly found benign tumours (35–46%) of the bone.^{1 2} These are mostly found in the metaphyseal region of long bones and the scapula is involved rarely in 3–4.6% of cases.³ These scapular tumours may present with winging of the scapula.⁴

We present a case of an 18-year-old male with a large, symptomatic osteochondroma of the scapula. He presented with a painless deformity of the right scapula for the past 3 years. Local examination revealed winging of the right scapula (figure 1) and a bony prominence at the medial border of the right scapula. Terminal abduction of glenohumeral joint was restricted. An X-ray of the chest revealed a bony outgrowth from the medial margin of the right scapula. A CT scan revealed an anteriorly directed bone growth at superomedial portion of the scapula, measuring 5.2×2.9×3.2 cm (figures 2–4).

A bony hard tumour (5×3 cm) was excised in toto (figure 5) from the right scapula under general anaesthesia, by a longitudinal incision parallel to the medial scapular border. Histology confirmed the diagnosis of osteochondroma with no evidence of malignancy (figure 6). The patient's deformity disappeared completely and he had full range of glenohumeral and scapulothoracic movements at 3 months, postoperatively.

The growing potential of osteochondromas usually ends by the time of closure of growth plate (physis), and if the growth continues into adulthood, it should alarm the surgeon for possible malignancy.

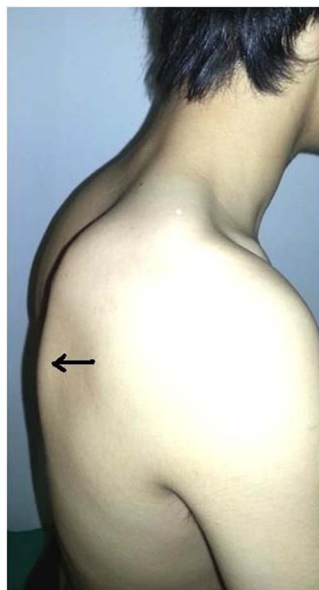

Figure 1 Clinical photograph showing pseudo-winging and deformity of the right scapula.

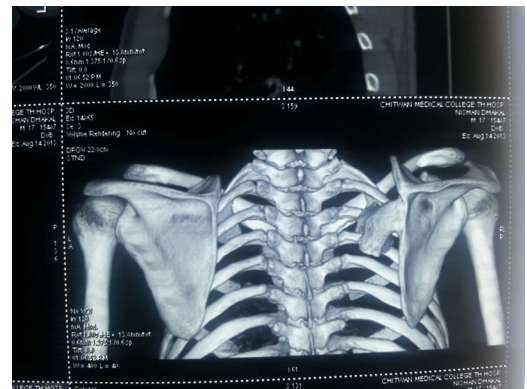

Figure 2 Three-dimensional CT scan images (reconstructed) showing a large bony tumour arising from the medial border of the body of the right scapula.

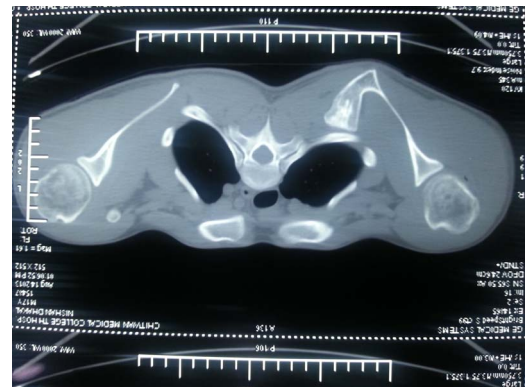


Figure 3 Three-dimensional CT scan images (reconstructed) showing a large bony tumour arising from the medial border of the body of the right scapula.

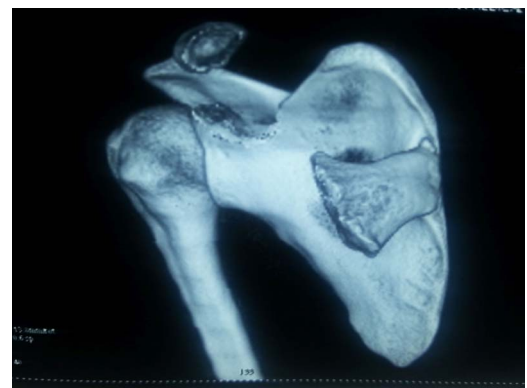

Figure 4 Three-dimensional CT scan images (reconstructed) showing a large bony tumour arising from the medial border of the body of the right scapula.



To cite: Vaishya R, Dhakal S, Vaish A. *BMJ Case Rep* Published online: [please include Day Month Year] doi:10.1136/bcr-2013-202273

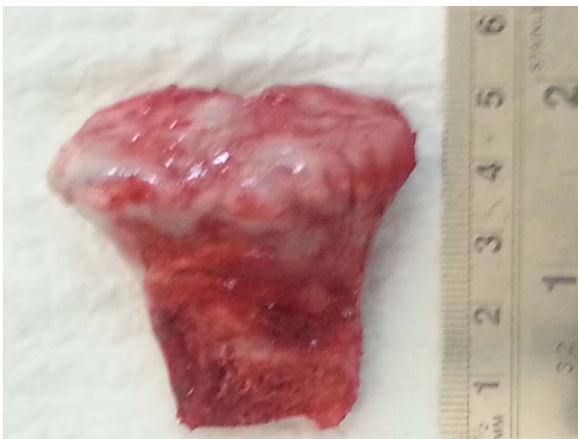

Figure 5 Excised specimen showing the bony tumour with cartilaginous cap.

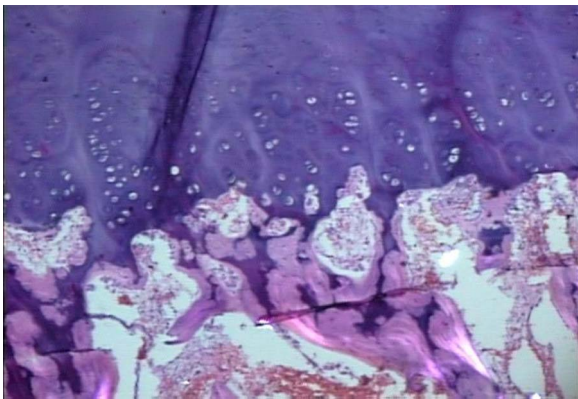


Figure 6 Histopathological section of the tumour showing a well-formed cartilage cap on the surface with a prominent enchondral ossification at the base, which continues into trabeculae of mature lamellar bone.

Treatment for symptomatic osteochondromas of the scapula is surgical excision of the mass. The prognosis is mostly good following excision; recurrence may, however, occur, if the excision is incomplete.

Learning points

- ▶ Osteochondromas arising from the scapula are rare presentation of a common benign bone tumour.
- ▶ Its diagnosis on plain X-rays may be difficult due to overlying lung, heart and rib cage shadows. However, CT scan can easily give the clue to its presence.
- ▶ The treatment of symptomatic tumours is surgical excision.

Competing interests None.

Patient consent Obtained.

Provenance and peer review Not commissioned; externally peer reviewed.

REFERENCES

- 1 Tomo H, Ito Y, Aono M, *et al*. Chest wall deformity associated with osteochondroma of the scapula: a case report and review of the literature. *J Shoulder Elbow Surg* 2005;14:103–6.
- 2 Mohsen MS, Moosa NK, Kumar P. Osteochondroma of the scapula associated with winging and large bursa formation. *Med Princ Pract* 2006;15:387–90.
- 3 Danielsson LG, el-Haddad I. Winged scapula due to osteochondroma. Report of 3 children. *Acta Orthop Scand* 1989;60:728–9.
- 4 Chillemi C, Franceschini V, Ippolito G, *et al*. Osteochondroma as a cause of scapular winging in an adolescent: a case report and review of the literature. *J Med Case Rep* 2013;7:220.

Copyright 2014 BMJ Publishing Group. All rights reserved. For permission to reuse any of this content visit

<http://group.bmj.com/group/rights-licensing/permissions>.

BMJ Case Report Fellows may re-use this article for personal use and teaching without any further permission.

Become a Fellow of BMJ Case Reports today and you can:

- ▶ Submit as many cases as you like
- ▶ Enjoy fast sympathetic peer review and rapid publication of accepted articles
- ▶ Access all the published articles
- ▶ Re-use any of the published material for personal use and teaching without further permission

For information on Institutional Fellowships contact consortiasales@bmjgroup.com

Visit casereports.bmj.com for more articles like this and to become a Fellow