

An unusual cause of acute abdominal pain in a young man

Abdul-Wahed Nasir Meshikhes

Department of Surgery, King Fahad Specialist Hospital, Dammam, Eastern Province, Saudi Arabia

Correspondence to
Dr Abdul-Wahed Nasir Meshikhes,
meshikhes@gmail.com

DESCRIPTION

A 19-year-old boy presented with a sudden onset of severe lower abdominal pain which was associated with nausea and vomiting, but no change in bowel habits, fever or weight loss. He gave a 2-year history of recurrent mild colicky lower abdominal pain, but no history of previous abdominal surgery. Clinical examination revealed low-grade fever (37.9°C) with generalised lower abdominal peritonism (tenderness with guarding, rigidity and rebound). Blood investigations showed leukocytosis ($13.8 \times 10^3/L$), normal renal and liver panels, but negative hydatid serology. The CT scan revealed an 8.3×8 cm right hepatic cystic mass with split-membrane sign consistent with complicated hydatid cyst (figure 1A). There were also multiple pelvic cystic masses of variable sizes (figure 1B).

At laparotomy, an infected right hepatic hydatid cyst and another smaller cyst in the lesser sac were drained after taking the standard precautions against spillage. Multiple hydatid cysts were found attached to the greater omentum and in the pelvic

cavity. Some were infected and one was already leaking its infected contents (figure 2A). All omental cysts were completely excised (figure 2B) and the others were drained. He was discharged on three cycles of albendazole (400 mg twice daily for 28 days, repeated thrice with 2-week drug-free interval after each cycle). He remained well 5 years later with no recurrence.

Spontaneous or traumatic rupture of a hepatic hydatid cyst is not always associated with anaphylactic shock and sometimes remains silent and the patient presents many years later with disseminated peritoneal hydatidosis.¹ Hence, hydatidosis is almost always secondary to hepatic hydatid disease. It may remain silent and asymptomatic for many years, or it may present with an acute abdominal pain whenever one of the cysts is complicated by either infection or leakage. Treatment in such patients requires careful surgical excision.^{2 3} However, surgery is associated with a high recurrence rate that can be reduced by the use of drug therapy such as albendazole.

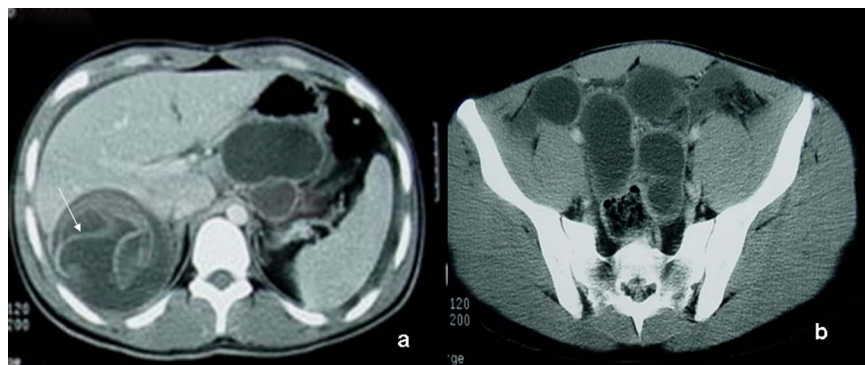


Figure 1 A CT scan showing the right hepatic cystic mass with the split-membrane sign (A; arrow) and multiple pelvic cystic masses of variable sizes (B).

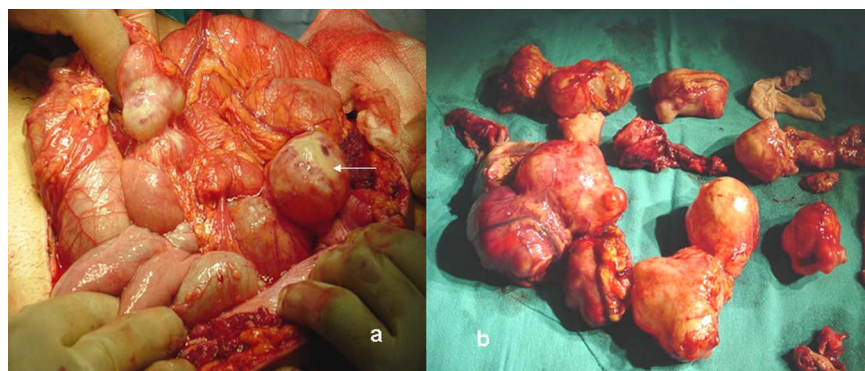


Figure 2 An operative view showing multiple peritoneal hydatid cysts; some were infected and one already leaking contents (A; arrow) and (B) showing the excised cysts.

To cite: Meshikhes A-WN. *BMJ Case Rep* Published online: [please include Day Month Year] doi:10.1136/bcr-2013-200285

Learning points

- ▶ Disseminated abdominal hydatidosis may occur as a result of a hepatic hydatid cyst rupture.
- ▶ It may remain asymptomatic, but occasionally present with an acute abdomen due to either cyst infection or leakage.
- ▶ Surgical treatment is associated with a high recurrence rate that can be reduced by the use of albendazole.

Competing interests None.

Patient consent Obtained.

Provenance and peer review Not commissioned; externally peer reviewed.

REFERENCES

- 1 Wani RA, Malik AA, Chowdri NA, *et al.* Primary extrahepatic abdominal hydatidosis. *Int J Surg* 2005;3:125–7.
- 2 Shah NJ, Vithalani NK, Chaudhary RK, *et al.* Disseminated peritoneal hydatidosis following blunt abdominal trauma: a case report. *Cases J* 2008;1:118.
- 3 Limas C, Soultanidis C, Kirmanidis MA, *et al.* Management of abdomen hydatidosis after rupture of a hydatid splenic cyst: a case report. *Cases J* 2009;2:8416.

Copyright 2013 BMJ Publishing Group. All rights reserved. For permission to reuse any of this content visit <http://group.bmj.com/group/rights-licensing/permissions>.

BMJ Case Report Fellows may re-use this article for personal use and teaching without any further permission.

Become a Fellow of BMJ Case Reports today and you can:

- ▶ Submit as many cases as you like
- ▶ Enjoy fast sympathetic peer review and rapid publication of accepted articles
- ▶ Access all the published articles
- ▶ Re-use any of the published material for personal use and teaching without further permission

For information on Institutional Fellowships contact consortiasales@bmjgroup.com

Visit casereports.bmj.com for more articles like this and to become a Fellow