

Giant vulvar basal cell carcinoma

Manish Garg,¹ Pradeep Sharma,¹ Suhasini Gupta,² Satya Narayan Sankhwar¹

¹Department of Urology, King George Medical University, Lucknow, Uttar Pradesh, India
²Department of Obstetrics and Gynaecology, Maharishi Markendeshwar Institute of Medical Sciences and Research, Mullana, Ambala, Haryana, India

Correspondence to

Dr Manish Garg,
 dr_manugarg@yahoo.co.in

DESCRIPTION

We report a case of 30-year-old woman presented with giant, foul smelling ulcerated growth involving the vulva. The growth was involving the whole of labia majora, minora and adjacent skin associated with itching, bleeding and discharge (figure 1). The lesion was atypical in its large size and gross morphology. Structures such as clitoris, vagina and urethral meatus were found to be uninvolved (figure 2). Owing to embarrassment, the patient did not present in earlier stage of disease. Inguinal lymph nodes were not palpable and pelvic CT showed no abnormality. Histopathology showed closely packed uniform basaloid cells with scant cytoplasm along with spherical or oval dark nuclei suggestive of basal cell carcinoma (BCC; figure 3). The patient was managed by radical local excision with skin grafting and was asymptomatic in follow-up period.

BCC accounts for 1–2% of vulvar cancers and usually affect the elderly.¹ Typically, BCC are small elevated lesions with clinical appearance that mimics eczema or psoriasis that rarely metastasise.²

BCC may be confused with basaloid squamous cell carcinoma (BSCC) or other basaloid tumours but may be differentiated clinically, as BSCC are more aggressive tumours and capable of deep invasion and distant metastases. On histopathology, BSCC usually show mitotic figures and comedonecrosis along with palisading basaloid cells. Careful search may also reveal intercellular bridges or keratin formation.³ Nevertheless, immunocytochemistry stainings are required for accurate diagnosis as BCCs are negative for epithelial membrane antigen and are positive for BCL2 and two Ber-EP4 while BSCCs are positive for 34βE12 and EMA markers.

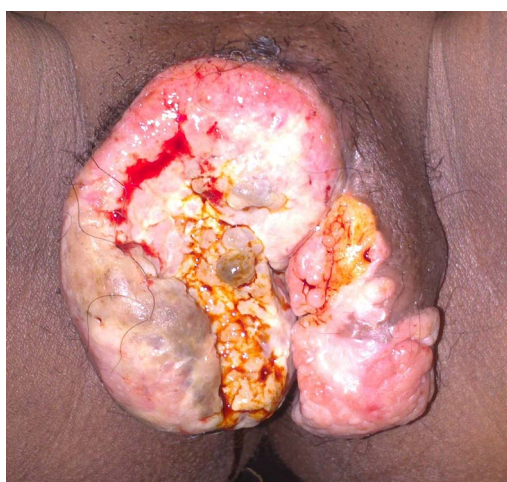

Figure 1 Large ulcerated growth involving both the lips of labia majora, labia minora and adjacent skin.

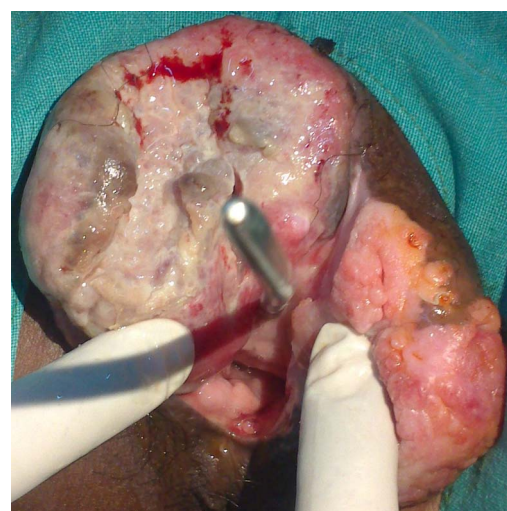


Figure 2 Vulval growth with sparing of vagina and uninvolved urethra calibrated with Hegar dilator.

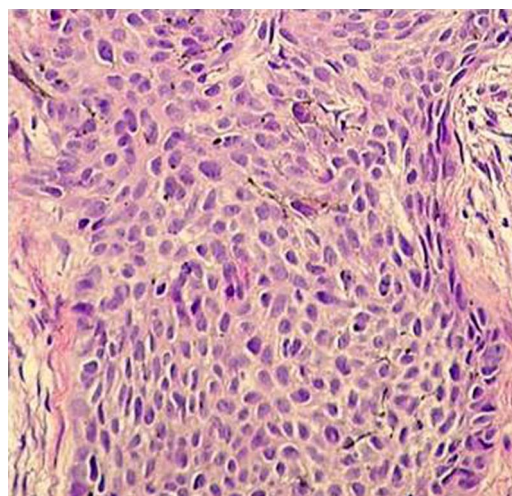


Figure 3 Histology showed closely packed uniform basaloid cells with scant cytoplasm with spherical or oval dark nuclei suggestive of basal cell carcinoma.

Learning points

- ▶ Signs and symptoms of vulvar malignancies are usually similar, but may present with non-specific and indolent clinical appearance.
- ▶ Adequate biopsy and careful pathological evaluation of vulvar lesions is important for proper diagnosis and management.

To cite: Garg M, Sharma P, Gupta S, et al. *BMJ Case Rep* Published online: [please include Day Month Year] doi:10.1136/bcr-2013-200180

Contributors All authors have made a significant contribution to the findings and methods in the paper. And have read and approved the final manuscript.

Competing interests None.

Patient consent Obtained.

Provenance and peer review Not commissioned; externally peer reviewed.

REFERENCES

- 1 Finan MA, Barre G. Bartholin's gland carcinoma, malignant melanoma and other rare tumours of the vulva. *Best Pract Res Clin Obstet Gynaecol* 2003;17:609–33.
- 2 Giorgi V, Salvini C, Massi D, *et al.* Vulvar basal cell carcinoma: retrospective study and review of literature. *Gynecol Oncol* 2005;97:192–4.
- 3 Vasudev P, Boutross-Tadross O, Radhi J. Basaloid squamous cell carcinoma: two case reports. *Cases J* 2009;2:9351.

Copyright 2013 BMJ Publishing Group. All rights reserved. For permission to reuse any of this content visit <http://group.bmj.com/group/rights-licensing/permissions>.
BMJ Case Report Fellows may re-use this article for personal use and teaching without any further permission.

Become a Fellow of BMJ Case Reports today and you can:

- ▶ Submit as many cases as you like
- ▶ Enjoy fast sympathetic peer review and rapid publication of accepted articles
- ▶ Access all the published articles
- ▶ Re-use any of the published material for personal use and teaching without further permission

For information on Institutional Fellowships contact consortiasales@bmjgroup.com

Visit casereports.bmj.com for more articles like this and to become a Fellow