

# Acute splenic infarction in a hiker with previously unrecognised sickle cell trait

Monica Gupta, S S Lehl, Kamal Singh, Ram Singh

Department of Medicine,  
Government Medical College  
and Hospital, Chandigarh,  
India

## Correspondence to

Dr Monica Gupta,  
monicamanish2001@gmail.  
com

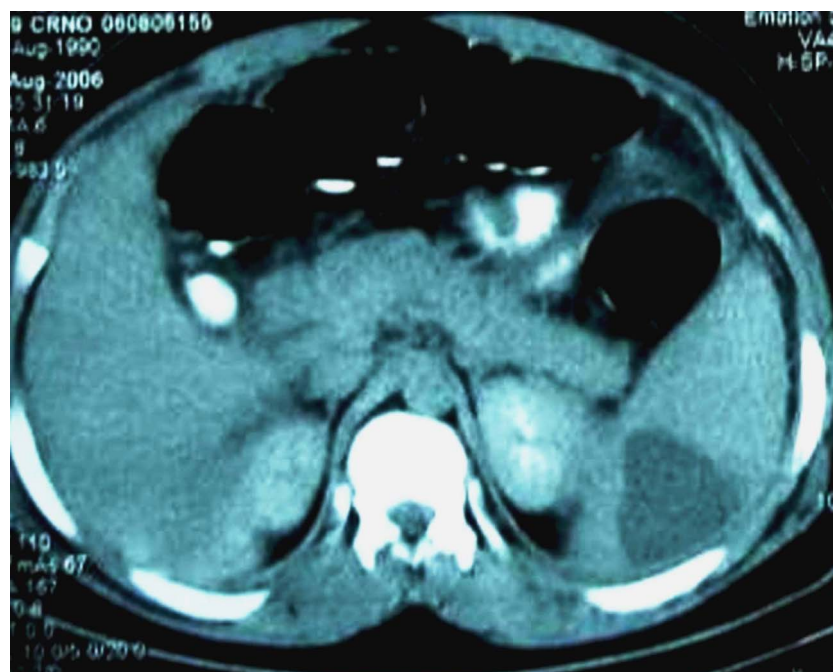
## DESCRIPTION

Acute splenic infarction in otherwise asymptomatic individuals harbouring sickle cell trait (SCT) may occur when they are exposed to low oxygen tension at high altitudes.<sup>1</sup> The first ever case report of splenic infarction in SCT was published way back in 1954 by Cooley *et al.*<sup>2</sup> Since then many similar cases have been reported worldwide and discussed at length.<sup>3</sup> The case we are highlighting here is that of a young healthy 21-year-old man, born in Punjab, India who went mountain climbing (for the first time) at Nanda devi, Garhwal Himalayas (Uttarakhand), with an altitude of 5025 m above sea level. After rapidly ascending to around 3500 m he suddenly experienced acute left upper quadrant discomfort, shortness of breath and left-sided pleuritic chest pain followed by fever. He was initially assessed and misinterpreted as being pneumonic by a local hospital and was then referred to us. During the course of investigations at our centre, a contrast-enhanced abdominal CT scan was done. It showed a classic pyramidal, wedge-shaped hypodensity of the affected splenic tissue with the apex pointing towards the splenic hilum, and the base overlying the splenic capsule, indicative of splenic infarct (figure 1). In addition mild pleural reaction was also present.

Splenic infarcts are seen commonly in haematological disorders (leukaemia, lymphoma,

polycythaemia vera, sickle cell disease) and embolic events (atrial fibrillation, infective endocarditis, HIV-associated mycobacterial infection). However, other conditions affecting the arterial supply, venous drainage or primary splenic pathology could present radiologically as splenic infarct. These conditions include splenic vascular disease, splenic arterial aneurysms, anatomical abnormalities of spleen, collagen vascular disease, pancreatitis, non-haematological malignancies or rarely blunt abdominal trauma. Contrast-enhanced CT (CECT) is often regarded as the preferred investigation and is performed during portal venous phase. Occasionally, in the hyperacute infarct stage, it may just show localised mottling (hyperdense) suggesting haemorrhagic infarction. Other atypical representations of acute infarct could be in the form of multiple, irregular, heterogeneous lesions of patchy enhancement or total splenic infarction (as in splenic torsion) or infarction of splenunculus. As the infarct enters the chronic phase, it gets fibrosed, contracted or may liquefy.

The haematological workup of this index case revealed that he was a heterozygous carrier of the sickle cell trait (HbA: 58%, HbS: 38.7%). He was managed with intravenous fluids, supplemental oxygen and pain control and improved without sequelae/surgical intervention. Although splenic infarction with SCT is not uncommon, it is often



**Figure 1** Axial contrast-enhanced abdominal CT scan of the patient showing classic pyramidal wedge-shaped hypodensity of the affected splenic tissue with the apex pointing towards the splenic hilum, and the base overlying the splenic capsule indicative of splenic infarct.

**To cite:** Gupta M, Lehl SS, Singh K, *et al.* *BMJ Case Rep* Published online: [please include Day Month Year] doi:10.1136/bcr-2013-008931

initially misdiagnosed and mismanaged. Our case reiterates the importance of clinical decision-making, keeping in mind the environmental exposures, patient's ethnicity and demographic predispositions. Timely supportive treatment can save lives and avoid unnecessary surgery.

### Learning points

- ▶ Although splenic infarction is rare in clinical practice, it is a well-recognised complication of sickle cell trait and requires a high index of suspicion for diagnosis.
- ▶ Early diagnosis is as crucial as timely therapy. It is essential to focus on adequate hydration, oxygenation, along with attempts to evacuate the individual to a lower altitude.
- ▶ The burden of unrecognised haemoglobinopathies may have huge demographic, public health, social and ethical implications and there is a need to frame screening guidelines for at-risk populations.

**Contributors** MG and SSL are the physicians who have seen and managed the case in an emergency and have drafted the initial version of this manuscript. RS and KS have provided valuable inputs into case management and presentation. All the authors have critically analysed the text, images and contributed significantly in shaping the final manuscript.

**Competing interests** None.

**Patient consent** Obtained.

**Provenance and peer review** Not commissioned; externally peer reviewed.

### REFERENCES

- 1 Frisancho OE, Ichianagui Rodríguez C. Spleen infarction and haemoglobinopathies in the high altitude lands. *Rev Gastroenterol Peru* 2012;32:68–78.
- 2 Cooley JC, Peterson WL, Engel CE, *et al.* Clinical triad of massive splenic infarction, sickle cell trait, and high altitude flying. *J Am Med Assoc* 1954;154:111–3.
- 3 Funakoshi H, Takada T, Miyahara M, *et al.* Sickle cell trait as a cause of splenic infarction while climbing Mt Fuji. *Intern Med* 2010;49:1827–9.

Copyright 2013 BMJ Publishing Group. All rights reserved. For permission to reuse any of this content visit <http://group.bmj.com/group/rights-licensing/permissions>.  
BMJ Case Report Fellows may re-use this article for personal use and teaching without any further permission.

Become a Fellow of BMJ Case Reports today and you can:

- ▶ Submit as many cases as you like
- ▶ Enjoy fast sympathetic peer review and rapid publication of accepted articles
- ▶ Access all the published articles
- ▶ Re-use any of the published material for personal use and teaching without further permission

For information on Institutional Fellowships contact [consortiasales@bmjgroup.com](mailto:consortiasales@bmjgroup.com)

Visit [casereports.bmj.com](http://casereports.bmj.com) for more articles like this and to become a Fellow