

Isolated double-orifice mitral valve: an extremely rare and interesting anomaly

Ashish Agarwal, Tarun Kumar, Shivakumar Bhairappa, Nanjappa C Manjunath

Department of Cardiology,
Sri Jayadeva Institute of
Cardiovascular Sciences and
Research, Bengaluru,
Karnataka, India

Correspondence to

Dr Ashish Agarwal,
medashish@rediffmail.com

DESCRIPTION

A 23-year-old asymptomatic man was referred for cardiac evaluation. A clinical examination was normal. Transthoracic 2D echocardiography showed double-orifice mitral valve (DOMV) in parasternal short-axis view at the level of mitral valve (figure 1, video 1). Apical four-chamber view showed a normally functioning valve without stenosis and/or regurgitation (video 2). Suprasternal long-axis view showed no evidence of coarctation (video 3). Rest of the echocardiographic examination was normal.

Greenfield reported the first case of DOMV in 1876.¹ It is characterised by the presence of two separate orifices in the mitral valve, each having independent chordal attachment to the papillary

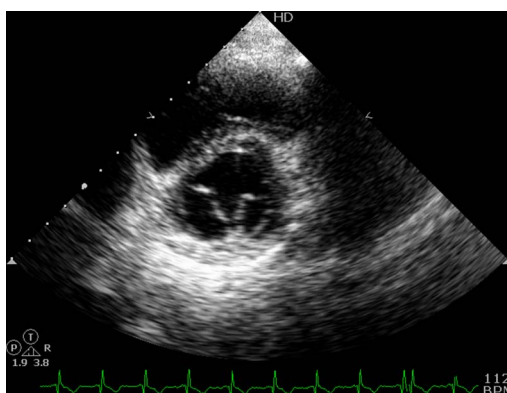
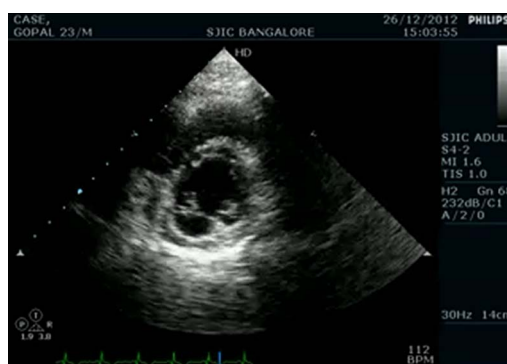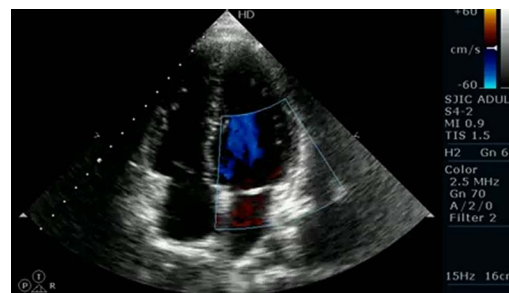


Figure 1 Parasternal short-axis view at the level of mitral valve showing two separate orifices of the double-orifice mitral valve.

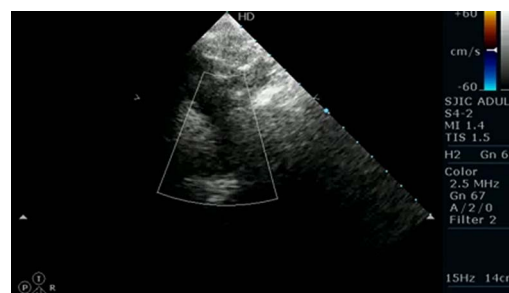

Video 1 Parasternal short-axis view at the level of mitral valve showing two separate orifices of the double-orifice mitral valve.



Video 2 Apical four-chamber view with colour Doppler at the mitral valve showing competent and non-stenotic mitral valve.

muscles at times creating an appearance of double parachute mitral valve. It is an extremely rare congenital anomaly which is usually found in association with other congenital heart diseases especially atrioventricular septal defect (most common), coarctation of aorta, interrupted aortic arch, patent ductus arteriosus and ventricular septal defect. Isolated DOMV, without other associated defects, is an extremely rare anomaly and the exact incidence is not known. It can present as mitral regurgitation (most common), incidental finding or uncommonly mitral stenosis.² Abnormalities of the subvalvular apparatus are almost always present. It has been classified by Trowitzsch *et al*³ in 1985 into three types: complete bridge, incomplete bridge and hole type. DOMV usually comes to attention as an incidental finding with other congenital defects. However, isolated DOMV can be easily missed in apical four-chamber and parasternal long-axis views. Parasternal short-axis view is the best to diagnose this entity and should be carefully interrogated even in the absence of other defects.



Video 3 Suprasternal long-axis view showing absence of coarctation.

To cite: Agarwal A, Kumar T, Bhairappa S, *et al*. *BMJ Case Rep* Published online: [please include Day Month Year] doi:10.1136/bcr-2013-008856

Learning points

- ▶ Isolated double-orifice mitral valve without other associated defects is an extremely rare anomaly which may be diagnosed as an incidental finding.
- ▶ Comprehensive echocardiographic examination should be performed as it can be easily missed in most of the echocardiographic views.
- ▶ Parasternal short-axis view is the best view to diagnose the anomaly.

REFERENCES

- 1 Greenfield WS. Double mitral valve. *Trans Path Soc London* 1876;27:128–9.
- 2 Zalstein E, Hamilton R, Zucker N, *et al*. Presentation, natural history, and outcome in children and adolescents with double orifice mitral valve. *Am J Cardiol* 2004;93:1067–9.
- 3 Trowitzsch E, Bano-Rodrigo A, Burger BM, *et al*. Two-dimensional echocardiographic findings in double orifice mitral valve. *J Am Coll Cardiol* 1985;6:383–7.

Competing interests None.

Patient consent Obtained.

Provenance and peer review Not commissioned; externally peer reviewed.

Copyright 2013 BMJ Publishing Group. All rights reserved. For permission to reuse any of this content visit <http://group.bmj.com/group/rights-licensing/permissions>.
BMJ Case Report Fellows may re-use this article for personal use and teaching without any further permission.

Become a Fellow of BMJ Case Reports today and you can:

- ▶ Submit as many cases as you like
- ▶ Enjoy fast sympathetic peer review and rapid publication of accepted articles
- ▶ Access all the published articles
- ▶ Re-use any of the published material for personal use and teaching without further permission

For information on Institutional Fellowships contact consortiasales@bmjgroup.com

Visit casereports.bmj.com for more articles like this and to become a Fellow