

Muscle MRI in Bethlem myopathy

Jasper M Morrow,¹ Robert D S Pitceathly,¹ Ros M Quinlivan,¹ Tarek A Yousry²

¹MRC Centre for Neuromuscular Diseases, UCL Institute of Neurology, London, UK

²Academic Neuroradiological Unit, UCL Institute of Neurology, London, UK

Correspondence to
Dr Jasper M Morrow,
j.morrow@ucl.ac.uk

DESCRIPTION

A 44-year-old man presented with progressive limb girdle weakness from 10 years of age. The inheritance pattern was autosomal dominant; two siblings, his mother and maternal grandfather were similarly affected. On examination there was an exaggerated lumbar lordosis, wasting of proximal limb musculature, and contractures at elbows, wrists and finger flexors. There was moderate symmetrical proximal upper and lower limb weakness without facial weakness or cardiorespiratory involvement. Previous investigations included electromyography which was myopathic, creatine kinase 2–4× normal and dystrophic muscle biopsy but no definitive diagnosis had been made.

The differential diagnosis is of a collagen VI myopathy (Bethlem), laminopathy or limb girdle muscular dystrophy. This differential diagnosis can be narrowed with lower limb muscle MRI¹ which was performed. The pattern (figure 1) was typical of Bethlem myopathy. The muscle biopsy was sent for further analysis which showed marked reduction of collagen VI at the basal lamina of most fibres. Subsequent genetic studies identified a heterozygous missense mutation in *COL6A2*.

Bethlem myopathy is the mild end of the collagen-VI-related myopathy spectrum. Although symptoms start in childhood, ambulation is typically maintained into adulthood. Contractures and mildly elevated creatine kinase are also typical.² Bethlem myopathy has a highly specific pattern of muscle involvement on imaging with 90% sensitivity.^{1–3} The peripheral involvement of the vasti muscles and antero-central involvement of rectus femoris^{1–3} is particularly striking and once seen easily recognised subsequently, facilitating definitive genetic diagnosis.

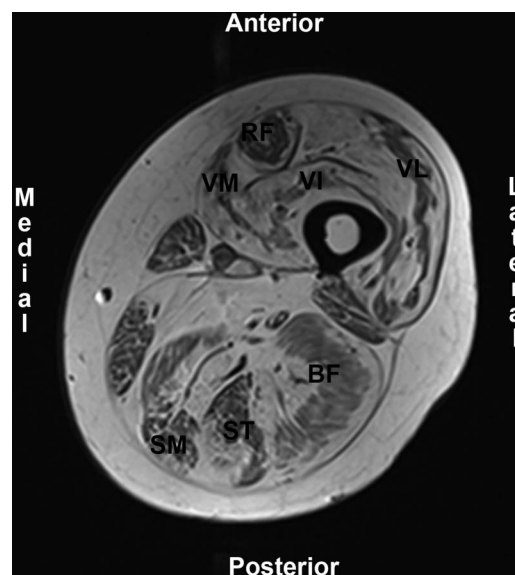


Figure 1 T1-weighted MRI, transverse slice at mid left thigh. Normal muscle has low-signal intensity, fat has high-signal intensity. The quadriceps muscle shows the typical pattern for Bethlem myopathy: peripheral fat infiltration with central sparing of the vasti muscles (VM, vastus medialis; VI, vastus intermedius; VL, vastus lateralis) and both peripheral and antero-central infiltration of rectus femoris (RF) leaving a 'U' shape of less-affected muscle. Central sparing of the hamstring muscles (BF, biceps femoris; ST, semitendinosus; SM, semimembranosus) is also apparent.

Competing interests None.

Patient consent Obtained.

Provenance and peer review Not commissioned; externally peer reviewed.

Learning points

- ▶ Consider Bethlem myopathy in adults with progressive myopathy and contractures.
- ▶ A highly specific pattern of muscle involvement may be seen on lower limb MRI in Bethlem myopathy and guide definitive genetic testing.

REFERENCES

- 1 Mercuri E, Clements E, Offiah A, *et al*. Muscle magnetic resonance imaging involvement in muscular dystrophies with rigidity of the spine. *Ann Neurol* 2010;67:201–8.
- 2 Mercuri E, Lampe A, Allsop J, *et al*. Muscle MRI in Ullrich congenital muscular dystrophy and Bethlem myopathy. *Neuromuscul Disord* 2005;15:303–10.
- 3 Ten Dam L, van Der Kooij AJ, van Wattigen M, *et al*. Reliability and accuracy of skeletal muscle imaging in limb-girdle muscular dystrophies. *Neurology* 2012;79:1716–23.

To cite: Morrow JM, Pitceathly RDS, Quinlivan RM, *et al*. *BMJ Case Rep* Published online: [please include Day Month Year] doi:10.1136/bcr-2013-008596

Copyright 2013 BMJ Publishing Group. All rights reserved. For permission to reuse any of this content visit <http://group.bmj.com/group/rights-licensing/permissions>.
BMJ Case Report Fellows may re-use this article for personal use and teaching without any further permission.

Become a Fellow of BMJ Case Reports today and you can:

- ▶ Submit as many cases as you like
- ▶ Enjoy fast sympathetic peer review and rapid publication of accepted articles
- ▶ Access all the published articles
- ▶ Re-use any of the published material for personal use and teaching without further permission

For information on Institutional Fellowships contact consortiasales@bmjgroup.com

Visit casereports.bmj.com for more articles like this and to become a Fellow