

## Images in...

## 'Where am I?' – An unusual stroke presentation

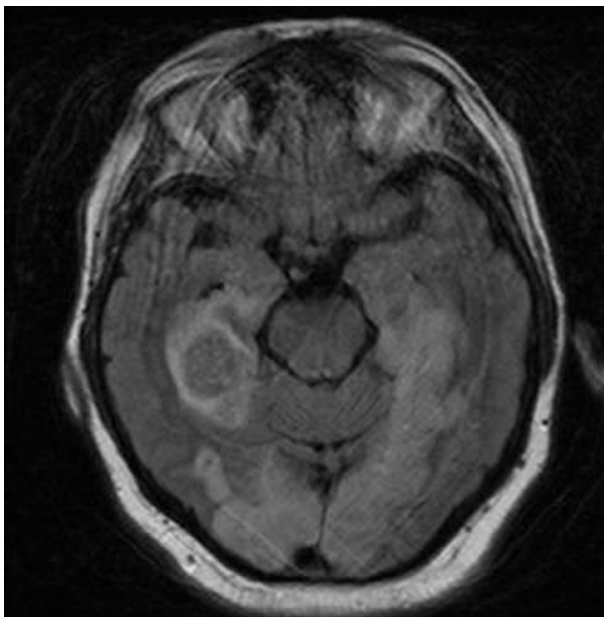
Joanna Lobaz,<sup>1</sup> Jonathan Richard White<sup>2</sup><sup>1</sup>Elderly Medicine Department, St James's University Teaching Hospital, Leeds, UK;<sup>2</sup>Gastroenterology Department, Derby Royal Hospital, Derby, UK;

Correspondence to Dr Jonathan Richard White, whitj@doctors.org.uk

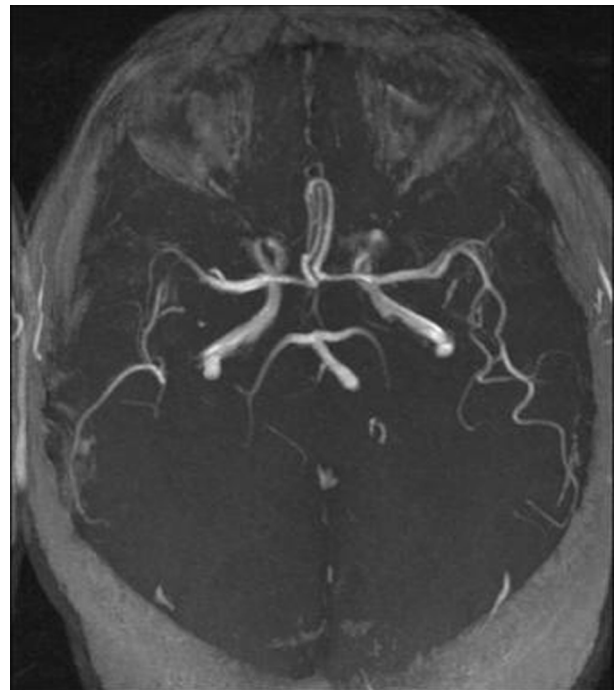
## DESCRIPTION

A 66-year-old taxi-driver presented with a 1 day history of frontal headache, confusion, amnesic episodes and declining eye sight. On examination, despite his cheery disposition he had no recollection of events of the past decade, his vision was limited to light perception and he had an ataxic gait. His medical history included ischaemic heart disease, hypertension, hypercholesterolaemia and an ex-smoking habit. His 'stroke protocol' CT scan and subsequent MRI and MR angiography revealed that he had suffered bilateral posterior cerebral artery infarcts supplying the occipital lobes and that the right-sided infarct had also resulted in haemorrhagic transformation in the hippocampal region of the temporal lobe (figures 1 and 2). A 24-h tape also revealed runs of atrial fibrillation. Formal neuropsychological assessment confirmed his cortical visual loss and short term memory deficit. Occupational therapy and physiotherapy assessment revealed that his difficulty with coordination was multifactorial, for example: poor vision, poor lighting in some areas of the ward, an inability

to remember the ward layout and where he had last put important possessions such as hearing aid and glasses. This case demonstrates the importance of recognising stroke symptoms that do not meet the clear cut F.A.S.T campaign criteria but that also require prompt recognition and management. This case study is also a good example of clinical anatomy in action: the occipital and temporal location of this gentleman's lesions correlates with the expected 'text book' neurological symptoms of visual impairment and memory loss respectively. In conclusion, this patient did experience some improvement with both his vision and memory. With regard to secondary prevention, this gentleman was started on warfarin and had his vascular risk factors minimised. Adaptations at home were also made to help with activities of daily living. However, this patient was discharged with a significant functional impairment. Unfortunately, this is not an uncommon outcome post-stroke despite the best efforts of stroke rehabilitation teams across the country.<sup>1</sup>



**Figure 1** MRI scan: infarction in the posteromedial temporal lobes and occipital lobes bilaterally. Also evidence of some haemorrhagic transformation in right temporal region.



**Figure 2** MR angiography scan: bilateral occlusion of the distal posterior cerebral arteries.

**Competing interests** None.

**Patient consent** Obtained.

## REFERENCES

1. Reducing Brain Damage: faster access to better stroke care. National Audit Office Report. Department of Health, 2005.

This pdf has been created automatically from the final edited text and images.

Copyright 2012 BMJ Publishing Group. All rights reserved. For permission to reuse any of this content visit <http://group.bmj.com/group/rights-licensing/permissions>.  
BMJ Case Report Fellows may re-use this article for personal use and teaching without any further permission.

Please cite this article as follows (you will need to access the article online to obtain the date of publication).

Lobaz J, White JR. 'Where am I?' – An unusual stroke presentation. *BMJ Case Reports* 2012;10.1136/bcr.12.2011.5296, Published XXX

Become a Fellow of BMJ Case Reports today and you can:

- ▶ Submit as many cases as you like
- ▶ Enjoy fast sympathetic peer review and rapid publication of accepted articles
- ▶ Access all the published articles
- ▶ Re-use any of the published material for personal use and teaching without further permission

For information on Institutional Fellowships contact [consortiasales@bmjgroup.com](mailto:consortiasales@bmjgroup.com)

Visit [casereports.bmj.com](http://casereports.bmj.com) for more articles like this and to become a Fellow

Keep up to date with all published cases by signing up for an alert (all we need is your email address) <http://casereports.bmj.com/cgi/alerts/etoc>