

Images in...

Multiple arthritis: three in one

Celia Coelho Henriques, Filipa Lourenço, Begoña Lopéz, António Panarra, Nuno Riso

Department of Internal Medicine 2, Curry Cabral Hospital, Lisbon, Lisbon, Portugal

Correspondence to Dr Celia Coelho Henriques, celia.c.henriques@gmail.com

DESCRIPTION

The authors describe a first report of three types of arthritis in the same patient: rheumatoid arthritis, psoriatic arthritis and gouty arthritis. A male patient, 56-year-old, Caucasian, with a known history of essential hypertension and gout was presented. The diagnosis of gout was made by isolation of monosodium urate crystals in synovial liquid when he was 45-years-old. He was diagnosed with psoriasis when he was 32-years-old, initially with extensive cutaneous and nail involvement (scalp, trunk and limbs). Associated with psoriatic changes, he had thickening of both legs skin with multiple nodules of hard consistency (figure 1). The patient presented with joint complaints

that included inflammatory, bilateral and asymmetric polyarthritis of the wrists, metacarpal-phalangeal joints and conditioning articular deformity (figure 2). He also had tophi in forearms, hands, feet and ears (figure 3). Blood tests performed showed a serum uric acid level of 4.5 mg/dl, elevated inflammatory markers (erythrocyte sedimentation rate 56 mm/h and C reactive protein 2.8 mg/dl), positive antinuclear antibody titres of 1/320, positive rheumatoid factor of 53 and anticitrullinated protein antibody weakly positive – 25 U/ml. Hands radiography revealed exuberant joint destruction predominantly in carpal and proximal interphalangeal joints, juxta-articular new bone formation and enthesitis (figure 4). A biopsy of a cutaneous nodule was compatible with a rheumatoid nodule.

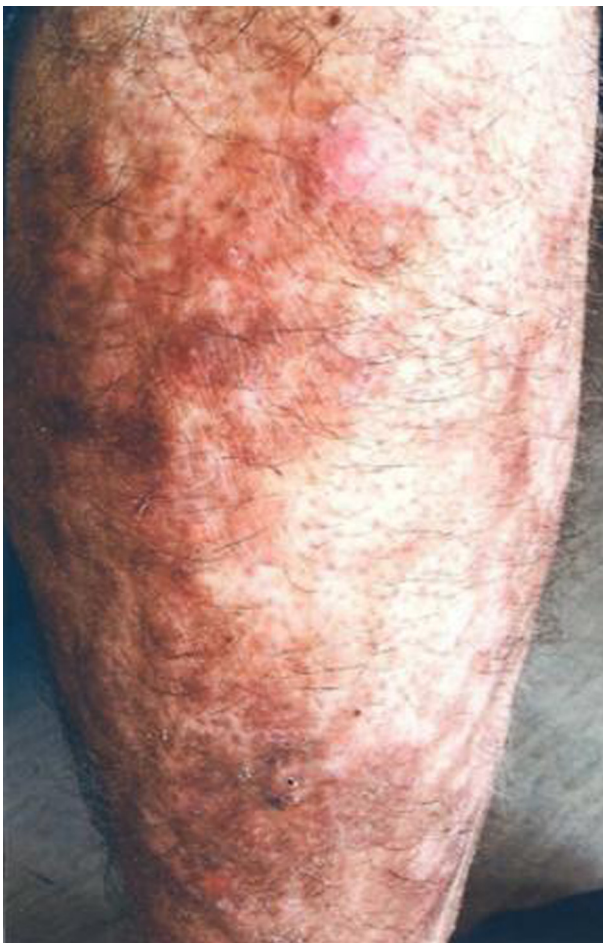

Figure 1 Rheumatoid nodules; thickening of both legs skin with multiple nodules of hard consistency.

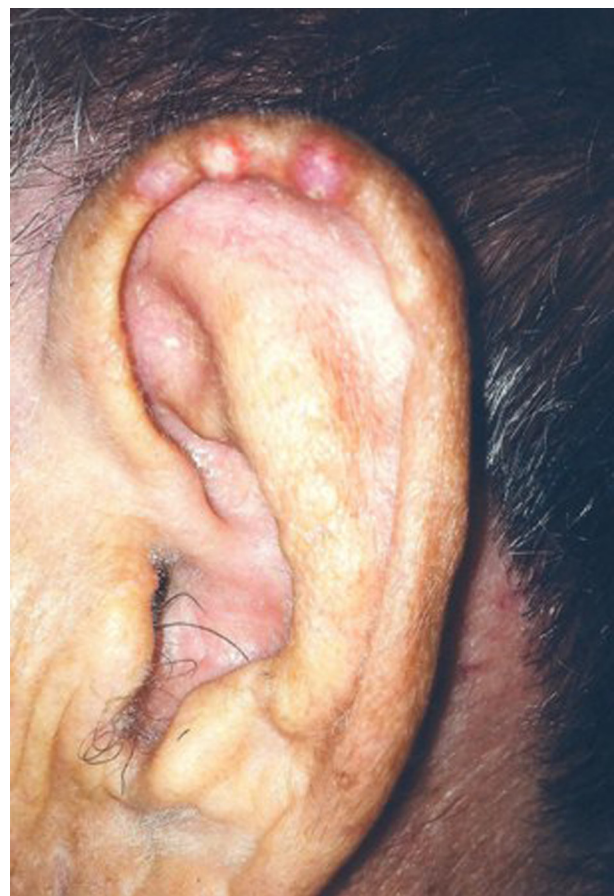

Figure 3 Multiple tophi in the curved ridge along the edge of the outer ear.

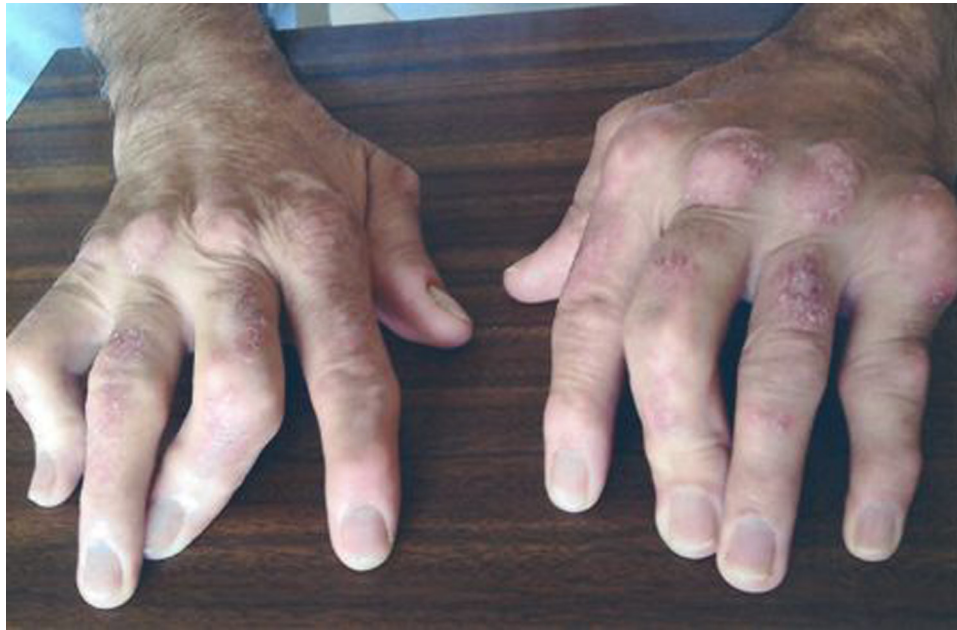

Figure 2 Exuberant articular deformity of both hands; multiple juxta-articular nodules in metacarpophalangeal joints.

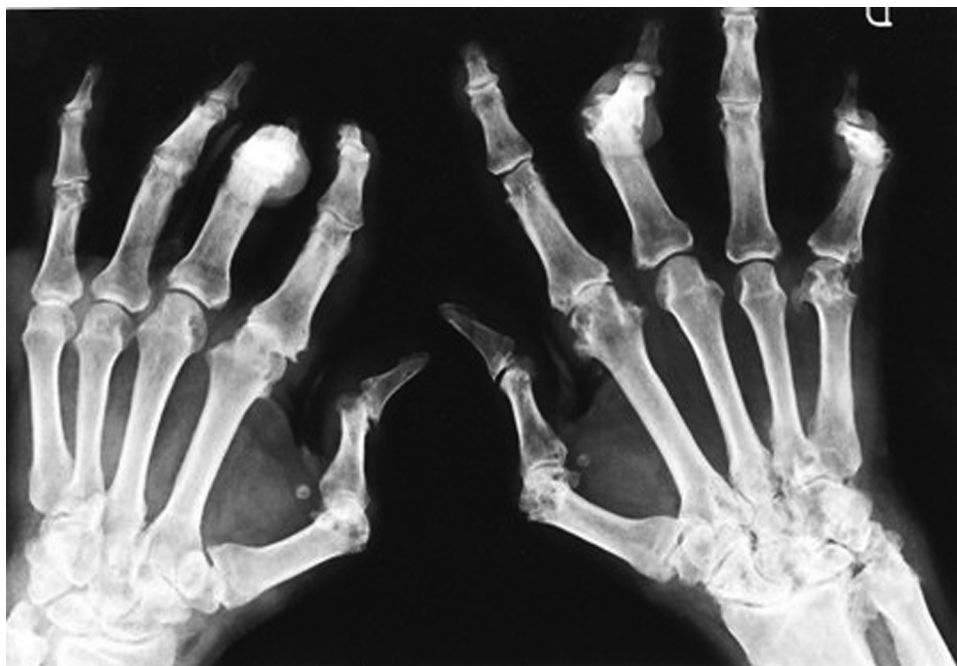


Figure 4 Hands radiography revealing exuberant joint destruction in carpal and proximal interphalangeal joints, juxta-articular new bone formation and enthesitis.

Given these data, beyond gouty arthritis, it was possible to include this patient in another two distinct autoimmune entities, according to the criteria of current classification – psoriatic arthritis (PA) (CASPAR criteria 2006) and rheumatoid arthritis (RA) (ACR criteria/EULAR 2010).^{1 2} The classification in overlap syndromes and the distinction between primary and secondary diseases reveal the immunological common basis of the autoimmune diseases

(ADs). Clinically, it is useful to define overlap syndromes to clarify prognosis and facilitate disease management.³ Certain drugs (particularly antitumour necrosis factor α) can successfully treat an AD (for example RA or PA) and paradoxically exacerbate others, including psoriasis (for which conditions are known to be effective).⁴ In this context the early identification and classification of an overlap AD is of the utmost importance.

Learning points

- ▶ The presence of more than one type of arthritis can have a prognostic significance, conditioning, in some cases a more aggressive clinical course.
- ▶ The coexistence of ADs should be identified early, given that the therapeutic approach may be more complex, considering that some of the drugs used to treat an AD can be unexpectedly harmful in another AD.

Competing interests None.

Patient consent Obtained.

REFERENCES

1. **Aletaha D**, Neogi T, Silman AJ, *et al*. 2010 rheumatoid arthritis classification criteria: an American College of Rheumatology/European League Against Rheumatism collaborative initiative. *Ann Rheum Dis* 2010;**69**:1580–8.
2. **Taylor W**, Gladman D, Helliwell P, *et al*.; CASPAR Study Group. Classification criteria for psoriatic arthritis: development of new criteria from a large international study. *Arthritis Rheum* 2006;**54**:2665–73.
3. **Alarcón-Segovia D**. Shared autoimmunity: a concept for which the time has come. *Autoimmunity* 2005;**38**:201–3.
4. **Kary S**, Worm M, Audring H, *et al*. New onset or exacerbation of psoriatic skin lesions in patients with definite rheumatoid arthritis receiving tumour necrosis factor alpha antagonists. *Ann Rheum Dis* 2006;**65**:405–7.

This pdf has been created automatically from the final edited text and images.

Copyright 2012 BMJ Publishing Group. All rights reserved. For permission to reuse any of this content visit <http://group.bmj.com/group/rights-licensing/permissions>.

BMJ Case Report Fellows may re-use this article for personal use and teaching without any further permission.

Please cite this article as follows (you will need to access the article online to obtain the date of publication).

Henriques CC, Lourenço F, Lopéz B, Panarra A, Riso N. Multiple arthritis: three in one. *BMJ Case Reports* 2012;10.1136/bcr.11.2011.5151, Published XXX

Become a Fellow of BMJ Case Reports today and you can:

- ▶ Submit as many cases as you like
- ▶ Enjoy fast sympathetic peer review and rapid publication of accepted articles
- ▶ Access all the published articles
- ▶ Re-use any of the published material for personal use and teaching without further permission

For information on Institutional Fellowships contact consortiasales@bmjgroup.com

Visit casereports.bmj.com for more articles like this and to become a Fellow

Keep up to date with all published cases by signing up for an alert (all we need is your email address) <http://casereports.bmj.com/cgi/alerts/etoc>