

Images in...

Fetus in fetu in the back

Baogan Peng, Duanming Li

Department of Spinal Surgery, General Hospital of Armed Police Force, Beijing, China

Correspondence to Professor Baogan Peng, pengbaogan@163.com

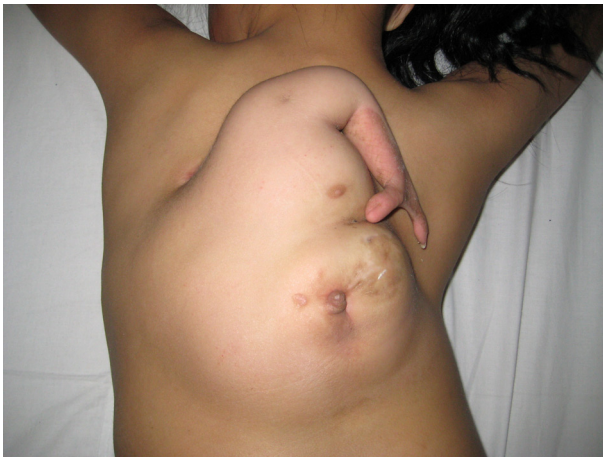

Figure 1 An 11-year-old girl had a large fetus in fetu in her back

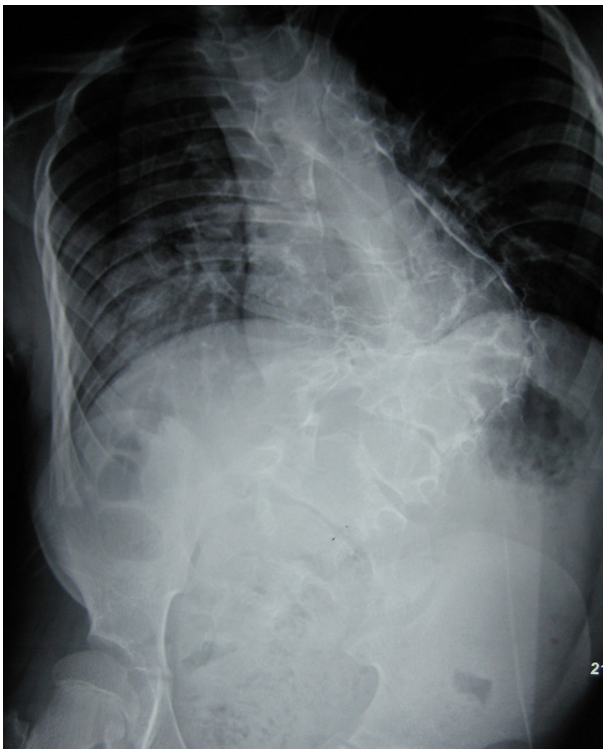

Figure 2 Anteroposterior spine radiograph showed congenital scoliosis anomalies

DESCRIPTION

An 11-year-old girl was hospitalised because of a large mass in her back (figure 1). She was the second child in her family where there was neither twin pregnancy nor fetal malformation. The large mass has two parts where the upper part consists of a mammary gland and an attached upper limb including a scapular, humerus and two fingers, and where the lower part contains a thick-walled sac which endlessly secreted mucosal fluid. There was not a clear cleavage plane between the autosite and the parasite. The anteroposterior spine radiograph showed congenital scoliosis anomalies (figure 2), and the CT scan showed diastematorrhachia and diastematomyelia in the thoracolumbar region (figure 3). Based on above-mentioned physical examination and imaging findings, a diagnosis of fetus in fetu was thus made preoperatively. A surgical excision of the fetus in fetu was performed successfully. Histological sections of the excised sac specimen showed stratified squamous epithelium and digestive tract mucosa. Fetus in fetu is a very rare condition, with a reported incidence of one in 5000 000 live births.¹ It is a malformed parasitic monozygotic diamniotic twin that is found inside the body of the living child or adult.² Hoeffel *et al*² provide an excellent and very complete literature review of 88 cases including their own a case. The mass is located in the retroperitoneum in 80% of cases. It also occurs in other locations, such as

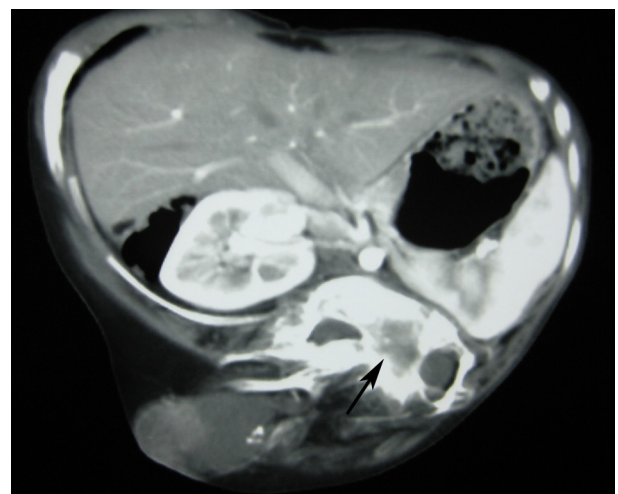


Figure 3 CT scan showed diastematorrhachia and diastematomyelia in the thoracolumbar region (arrow).

skull, sacrum, scrotum and mouth. However, it has never been reported in the back.

Learning points

- ▶ Fetus in fetu is a very rare condition, with a reported incidence of one in 5000 000 live births.
- ▶ It is a malformed parasitic monozygotic diamniotic twin that is found inside the body of the living child or adult. The mass is located in the retroperitoneum in 80% of cases. It also occurs in other locations, such as skull, sacrum, scrotum and mouth.
- ▶ Fetus in fetu first was reported to occur in the back.

Competing interests None.

Patient consent Obtained.

REFERENCES

1. **Hoeffel CC**, Nguyen KQ, Phan HT, *et al*. Fetus in fetu: a case report and literature review. *Pediatrics* 2000;**105**:1335–44.
2. **Varanelli MJ**, Jamal Bokhari SA, Katai FM, *et al*. Case 55: fetus in fetu. *Radiology* 2003;**226**:517–20.

This pdf has been created automatically from the final edited text and images.

Copyright 2012 BMJ Publishing Group. All rights reserved. For permission to reuse any of this content visit <http://group.bmj.com/group/rights-licensing/permissions>.
BMJ Case Report Fellows may re-use this article for personal use and teaching without any further permission.

Please cite this article as follows (you will need to access the article online to obtain the date of publication).

Peng B, Li D. Fetus in fetu in the back. *BMJ Case Reports* 2012;10.1136/bcr.03.2012.6150, Published XXX

Become a Fellow of BMJ Case Reports today and you can:

- ▶ Submit as many cases as you like
- ▶ Enjoy fast sympathetic peer review and rapid publication of accepted articles
- ▶ Access all the published articles
- ▶ Re-use any of the published material for personal use and teaching without further permission

For information on Institutional Fellowships contact consortiasales@bmjgroup.com

Visit casereports.bmj.com for more articles like this and to become a Fellow

Keep up to date with all published cases by signing up for an alert (all we need is your email address) <http://casereports.bmj.com/cgi/alerts/etoc>