

Images in...

# Typhlitis: a neutropenic complication

Lokesh Shahani

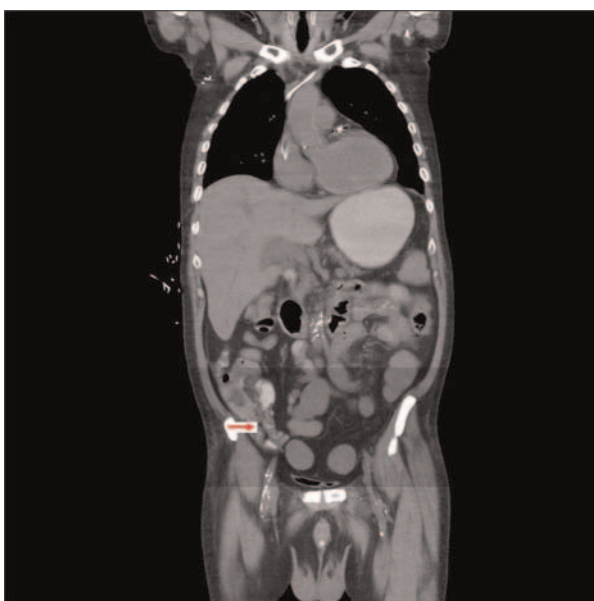
Department of Internal Medicine, Southern Illinois University School of Medicine, Springfield, Illinois, USA

Correspondence to Dr Lokesh Shahani, lokesh83@hotmail.com

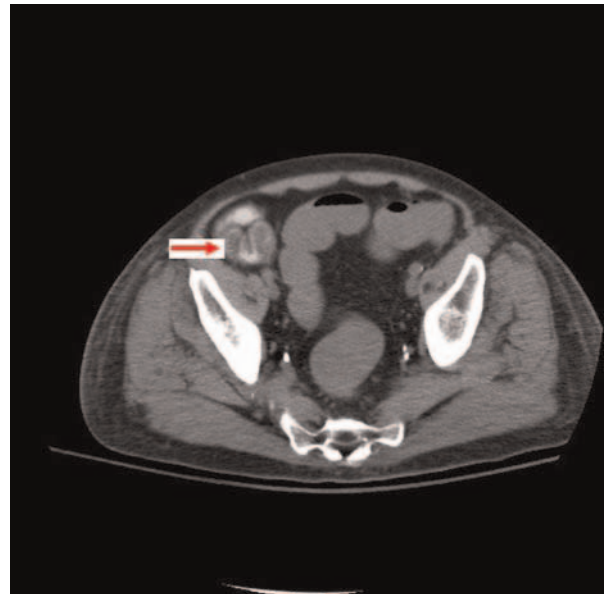
## DESCRIPTION

'Typhlitis' describes enterocolitis of the ileocaecal region seen commonly in neutropenic patients. As compared with other malignant conditions, acute myeloid leukaemia (AML) is most often associated with typhlitis.<sup>1</sup> The pathogenesis of typhlitis probably involves a combination of factors, including mucosal injury by cytotoxic drugs, profound neutropenia and impaired host defence to invasion by microorganisms.<sup>2</sup> The most common chemotherapeutics associated with typhlitis are cytarabine and daunorubicin.<sup>1</sup> Peritonitis and perforation are common complications of typhlitis and surgical intervention is indicated for these patients.<sup>3</sup>

The author reports a 59-year-old man diagnosed with AML and had completed induction chemotherapy consisting of cytarabine and daunorubicin. The patient presented to the hospital with fever and right lower quadrant abdominal pain. Laboratory investigations showed the presence of granulocytopenia with white cell count of 220 cells/mm<sup>3</sup> and the absence of neutrophils. The CT scan of the abdomen performed to investigate the abdominal pain demonstrated inflammatory stranding in the mesenteric fat surrounding the small bowel along with a small amount of fluid around the loops of the small bowel (figure 1). Luminal narrowing and mucosal irregularity were evident



**Figure 1** CT scan of abdomen showing inflammatory stranding in the mesenteric fat surrounding the small bowel.



**Figure 2** CT scan of abdomen showing mucosal thickening.

in the terminal ileum and the caecum (figure 2). These radiological findings have been shown to be highly suggestive of typhlitis.<sup>4</sup> Pseudomembranous colitis was differentiated from typhlitis because of localized small bowel involvement, as seen in the later along with negative stool study.<sup>4</sup> The patient was treated non-surgically with bowel rest, intravenous fluids, nutritional support and a broad spectrum of antibiotics including antifungal agents. The granulocyte colony-stimulating factor was used to speed up leucocyte recovery and the patient's abdominal condition recovered with improvement in neutrophil count.

## Learning points

- ▶ Typhlitis' describes enterocolitis of the ileocaecal region seen commonly in neutropenic patients.
- ▶ The pathogenesis of typhlitis probably involves a combination of factors, including mucosal injury by cytotoxic drugs, profound neutropenia and impaired host defence to invasion by microorganisms.
- ▶ Imaging studies suggestive of Typhlitis include diffuse cecal wall thickening; presence of intramural edema and inflammatory stranding in the mesenteric fat surrounding the small bowel.

**Competing interests** None.

**Patient consent** Obtained.

## REFERENCES

1. **Gray TL**, Ooi CY, Tran D, *et al*. Gastrointestinal complications in children with acute myeloid leukemia. *Leuk Lymphoma* 2010;**51**:768–77.
2. **Urbach DR**, Rotstein OD. Typhlitis. *Can J Surg* 1999;**42**:415.
3. **Wade DS**, Nava HR, Douglass HO Jr. Neutropenic enterocolitis. Clinical diagnosis and treatment. *Cancer* 1992;**69**:17.
4. **Kirkpatrick ID**, Greenberg HM. Gastrointestinal complications in the neutropenic patient: characterization and differentiation with abdominal CT. *Radiology* 2003;**226**:668–74.

This pdf has been created automatically from the final edited text and images.

Copyright 2012 BMJ Publishing Group. All rights reserved. For permission to reuse any of this content visit

<http://group.bmj.com/group/rights-licensing/permissions>.

BMJ Case Report Fellows may re-use this article for personal use and teaching without any further permission.

Please cite this article as follows (you will need to access the article online to obtain the date of publication).

Shahani L. Typhlitis: a neutropenic complication. *BMJ Case Reports* 2012;10.1136/bcr.02.2012.5815, Published XXX

Become a Fellow of BMJ Case Reports today and you can:

- ▶ Submit as many cases as you like
- ▶ Enjoy fast sympathetic peer review and rapid publication of accepted articles
- ▶ Access all the published articles
- ▶ Re-use any of the published material for personal use and teaching without further permission

For information on Institutional Fellowships contact [consortiasales@bmjgroup.com](mailto:consortiasales@bmjgroup.com)

Visit [casereports.bmj.com](http://casereports.bmj.com) for more articles like this and to become a Fellow