

Images in...

Abdominal cocoon in peritoneal dialysis – a fatal outcome

Mohamed Saleem Noormohamed, Najib Kadi

Department of Renal Transplant Surgery, Southmead Hospital, Bristol, UK

Correspondence to Mr Mohamed Saleem Noormohamed, smithnsal@yahoo.co.uk**DESCRIPTION**

Sclerosing peritonitis (SP, encapsulating peritoneal sclerosis or abdominal cocooning) is an inflammatory process affecting the peritoneum diffusely and constitutes a rare but life-threatening (figure 1), serious complication in patients on long-term continuous ambulatory peritoneal dialysis (CAPD).^{1 2} An overall prevalence of 0.7%² has been described in literature. The pathogenicity of this condition still remains unclear. Predisposing factors described in the literature include episodes of infective peritonitis, prolonged duration on CAPD, the use of chlorhexidine in alcohol-sterilising sprays, acetate and hyperosmolar dialysate.^{2 3} SP is a wide-spread evolution involving the accumulation of new fibrous tissue that encapsulate and limit the viscera, thereby compromising the bowel motility.³ A slow reduction of peritoneal permeability by the fibrous tissue leads to ultrafiltration failure of CAPD. This slow evolving process causes malnutrition to worsen. Abdominal discomfort with evidence

of complete or partial bowel obstruction is the usual clinical presentation.^{2 3} Classical CT findings (figures 2 and 3) include thickened adhered bowel loops, loculated ascites and peritoneal enhancement. Initial management involves the removal of dialysis catheter, discontinuation of CAPD, bowel rest and total parental nutritional support.⁴ The use of steroids, immunosuppressives and tamoxifen has been reported to be beneficial, but needs to be validated. Surgery is high risk for fistula formation and anastomotic leakage. Despite various therapeutic modalities, the death rate is 56–93%.⁴

Learning points

- ▶ A rare but life-threatening.
- ▶ Slow evolving process.
- ▶ Complete or partial bowel obstruction is the usual clinical presentation.

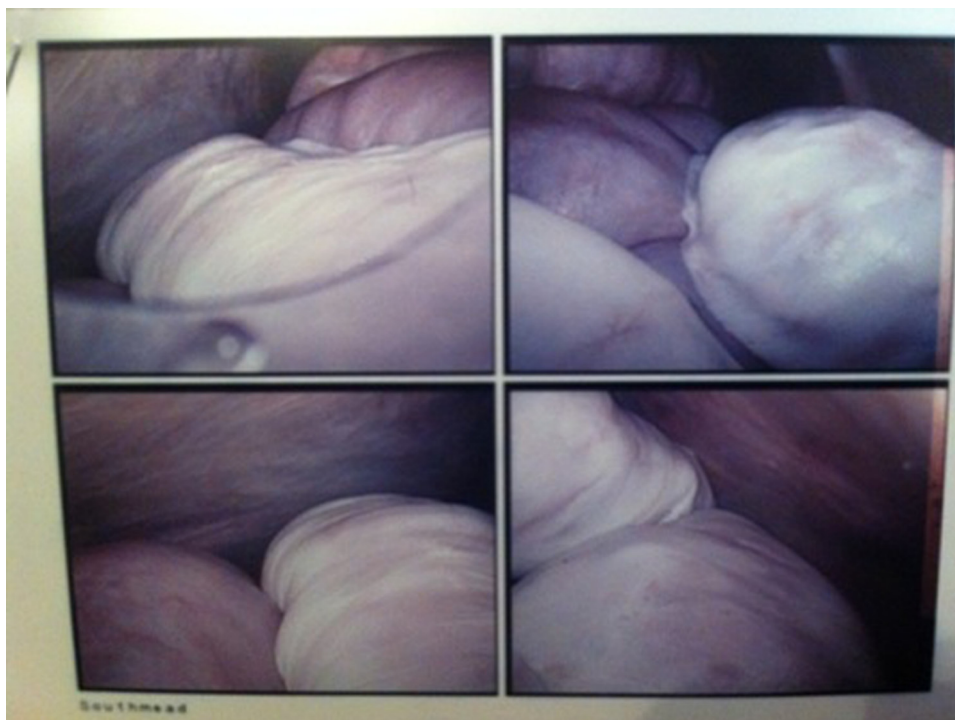


Figure 1 Laparoscopic view of abdominal cocoon.

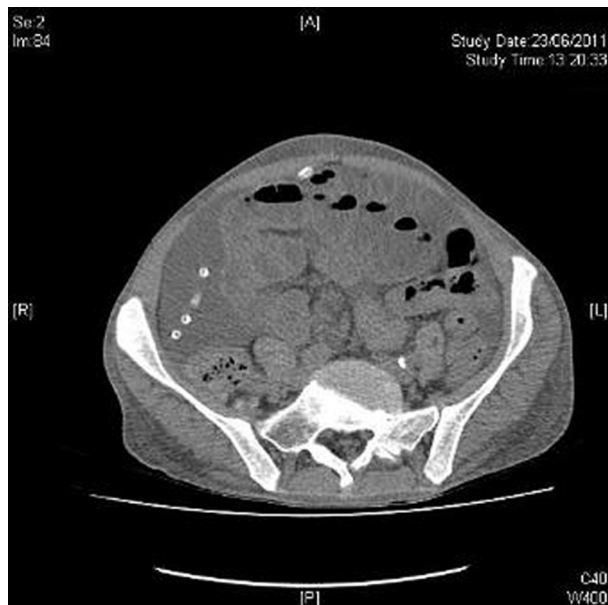


Figure 2 Non-contrast CT showing dilated bowel loops with continuous ambulatory peritoneal dialysis catheter.

Competing interests None.

Patient consent Not obtained.

REFERENCES

1. **Kawanishi H**, Kawaguchi Y, Fukui H, *et al*. Encapsulating peritoneal sclerosis in Japan: a prospective, controlled, multicenter study. *Am J Kidney Dis* 2004;**44**:729–37.

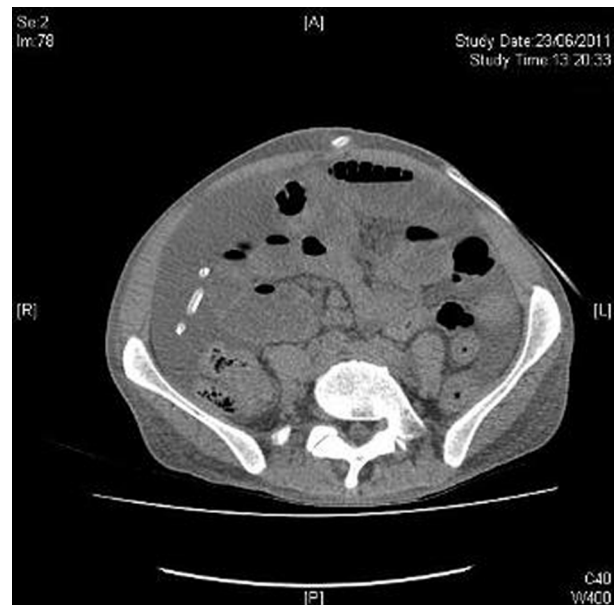

Figure 3 Non-contrast CT image showing multiple bowel loops with thickened peritoneum.

2. **Rigby RJ**, Hawley CM. Sclerosing peritonitis: the experience in Australia. *Nephrol Dial Transplant* 1998;**13**:154–9.
3. **Dobbie JW**. Pathogenesis of peritoneal fibrosis syndromes (sclerosing peritonitis) in peritoneal dialysis. *Perit Dial Int* 1992;**12**:14–27.
4. **Turagam M**, Are C, Velagapudi P, *et al*. Abdominal cocoon: a case of sclerosing encapsulating peritonitis. *ScientificWorldJournal* 2009;**9**:201–3.

This pdf has been created automatically from the final edited text and images.

Copyright 2012 BMJ Publishing Group. All rights reserved. For permission to reuse any of this content visit <http://group.bmj.com/group/rights-licensing/permissions>.

BMJ Case Report Fellows may re-use this article for personal use and teaching without any further permission.

Please cite this article as follows (you will need to access the article online to obtain the date of publication).

Noormohamed MS, Kadi N. Abdominal cocoon in peritoneal dialysis – a fatal outcome. *BMJ Case Reports* 2012;10.1136/bcr.01.2012.5581, Published XXX

Become a Fellow of BMJ Case Reports today and you can:

- ▶ Submit as many cases as you like
- ▶ Enjoy fast sympathetic peer review and rapid publication of accepted articles
- ▶ Access all the published articles
- ▶ Re-use any of the published material for personal use and teaching without further permission

For information on Institutional Fellowships contact consortiasales@bmjgroup.com

Visit casereports.bmj.com for more articles like this and to become a Fellow

Keep up to date with all published cases by signing up for an alert (all we need is your email address) <http://casereports.bmj.com/cgi/alerts/etoc>