

Images in...

Diffuse epidermolytic palmoplantar keratoderma (Unna-Thost-)

Louisa Hinterberger, Claudia Pföhler, Thomas Vogt, Cornelia S L Müller

Department of Dermatology, Saarland University, Homburg/Saar, Germany

Correspondence to Dr Cornelia S L Müller, cornelia.mueller@uks.eu

DESCRIPTION

We report the case of a 28-year-old man presenting to our hospital with refractory diffuse hyperkeratosis of palms and soles. He reported first appearance in early childhood. His first-born daughter also developed hyperkeratosis on palms and soles directly after birth. No other family member seems to be affected by similar skin lesions.

Clinically, our patient presented diffuse hyperkeratotic palms and soles with sharp red margins on the side of feet and back of the hands (figure 1).

To assure our suspicion an excisional skin biopsy of the palm was taken. Histologically epidermolytic hyperkeratosis was found (figure 2). In synopsis of clinical and histological data and family history we diagnosed Vörner type of palmoplantar keratoderma (PPK).

We started a treatment with acitretin 20 mg/day and a local treatment consisting of tretinoin and urea twice a day. Under this treatment the hyperkeratotic palms and soles slowly improved and so far no side effects have been noticed except for dry lips.

As it is already known, the PPK follows autosomal-dominant inheritance with a mutation in the keratin 1 and 9 genes.¹ Recently, it has been shown that epidermolytic PPK due to keratin 9 mutation can lead to digital mutilation.¹ In a study from 1992, the family originally described by Thost showed typical histological features of epidermolytic hyperkeratosis very similar to Vörner's PPK.² In 2002, Küster *et al*³ identified mutations in the same part of the keratin 9 gene. Hence, genetically PPK Unna-Thost and Vörner are the same entity.

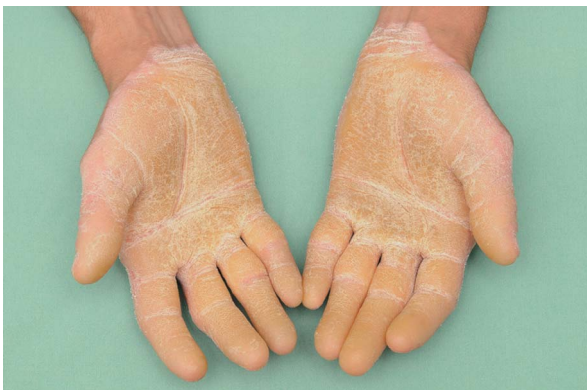

Figure 1 Clinical features with hyperkeratotic skin on both palms with red sharp margins.

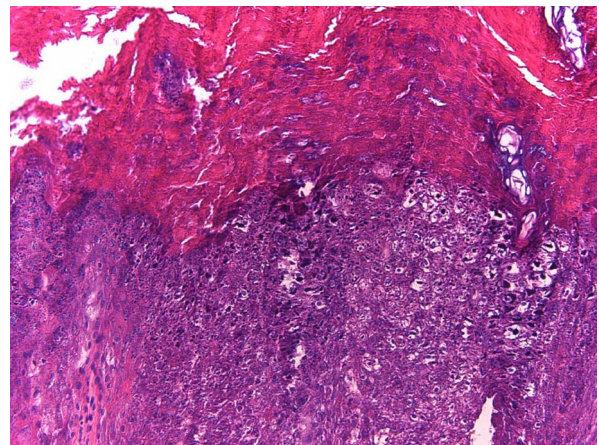


Figure 2 H&E stain displaying epidermolytic hyperkeratosis.

Learning points

- ▶ The Vörner-type palmoplantar keratoderma (PPK) follows autosomal-dominant inheritance with a causal mutation of the keratin 9 gene on chromosome 17q21.
- ▶ Several reports state that the previous historical classification of PPKs needs reconsideration.
- ▶ The PPK Unna-Thost and Vörner can be summarised as one type.

Competing interests None.

Patient consent Obtained.

REFERENCES

1. Umegaki N, Nakano O, Tamai K, *et al*. Vörner type palmoplantar keratoderma: novel KRT9 mutation associated with knuckle pad-like lesions and recurrent mutation causing digital mutilation. *Br J Dermatol* 2011;**165**:199–201.
2. Küster W, Becker A. Indication for the identity of palmoplantar keratoderma type Unna-Thost with type Vörner. Thost's family revisited 110 years later. *Acta Derm Venereol* 1992;**72**:120–2.
3. Küster W, Reis A, Hennies HC. Epidermolytic palmoplantar keratoderma of Vörner: re-evaluation of Vörner's original family and identification of a novel keratin 9 mutation. *Arch Dermatol Res* 2002;**294**:268–72.

Copyright 2012 BMJ Publishing Group. All rights reserved. For permission to reuse any of this content visit <http://group.bmj.com/group/rights-licensing/permissions>.
BMJ Case Report Fellows may re-use this article for personal use and teaching without any further permission.

Please cite this article as follows (you will need to access the article online to obtain the date of publication).

Hinterberger L, Pföhler C, Vogt T, Müller CSL. Diffuse epidermolytic palmoplantar keratoderma (Unna-Thost-). *BMJ Case Reports* 2012;10.1136/bcr-2012-006443, Published XXX

Become a Fellow of BMJ Case Reports today and you can:

- ▶ Submit as many cases as you like
- ▶ Enjoy fast sympathetic peer review and rapid publication of accepted articles
- ▶ Access all the published articles
- ▶ Re-use any of the published material for personal use and teaching without further permission

For information on Institutional Fellowships contact consortiasales@bmjgroup.com

Visit casereports.bmj.com for more articles like this and to become a Fellow