

Images in...

Extensive thrombophlebitis with gas associated with continuous infusion of vancomycin through a central venous catheter

Sandrine Leroy,¹ Pierre Piquet,² Christian Chidiac,^{1,3,4} Tristan Ferry^{1,3,4}

¹Hospices Civils de Lyon, Service de Maladies Infectieuses et Tropicales, Lyon, France

²Hospices Civils de Lyon, Service d'Exploration Vasculaire, Lyon, France

³Université Claude Bernard Lyon 1, Lyon, France

⁴INSERM U851, Lyon, France

Correspondence to Dr Tristan Ferry, tristan.ferry@univ-lyon1.fr

DESCRIPTION

A 48-year-old caucasian woman with a history of trauma was treated for osteomyelitis of the left ankle with ceftriaxone and continuous perfusion of vancomycin through a central venous catheter. After 2 months of therapy, the patient suddenly presented with fever, chills, neck and basithoracic pain. Basic observation revealed tachycardia, without any focus of infection. Extensive thrombophlebitis with gas was diagnosed on a thoracic CT scan (figure 1). The catheter was removed and vancomycin was switched to teicoplanin (administration through a peripheral catheter). The blood cultures (four pairs, incubated for 6 days) remained sterile, as did the culture of the catheter. The symptoms were resolved with curative anticoagulation (stopped at 6 months) only. No control CT was performed. Genetic tests revealed a heterozygous factor V Leiden.

Vancomycin is known to cause thrombophlebitis, which frequently occurs when this drug is administered through a peripheral catheter, but not when using a

central venous catheter, even if the central venous catheter is a predisposing factor for upper-extremity deep-vein thrombosis.^{1 2} Presence of gas bubbles in a thrombus is usually associated with septic thrombophlebitis, such as during intraabdominal pylephlebitis or Lemierre's syndrome, owing to intraluminal fermentation of carbohydrates due to anaerobic bacteria.³ In the case presented here, we ruled out the diagnosis of septic thrombophlebitis. This extensive aseptic thrombophlebitis with gas was, at least in part, due to continuous vancomycin therapy. The pathophysiology of gas production remained unclear. Hypercoagulability due to heterozygous factor V Leiden may participate in the thrombus formation, but the increased risk of thrombosis in such patients remains controversial.²

Learning points

- ▶ Continuous infusion of vancomycin through a central venous catheter could be associated with extensive superior vena cava thrombosis.
- ▶ Extensive thrombophlebitis induced by vancomycin could be associated with gas, without being septic.
- ▶ Further studies are required to determine whether heterozygous factor V Leiden facilitates profound thrombophlebitis during vancomycin therapy.

Acknowledgements We acknowledge Dr Thomas Perpoint, Dr André Boibieux and Dr Agathe Sénéchal who participated in patient care.

Competing interests None.

Patient consent Obtained.

REFERENCES

1. Sorrell TC, Collignon PJ. A prospective study of adverse reactions associated with vancomycin therapy. *J Antimicrob Chemother* 1985;**16**:235–41.
2. Mai C, Hunt D. Upper-extremity deep venous thrombosis: a review. *Am J Med* 2011;**124**:402–7.
3. Riordan T. Human infection with *Fusobacterium necrophorum* (Necrobacillosis), with a focus on Lemierre's syndrome. *Clin Microbiol* 2007;**20**:622–59.

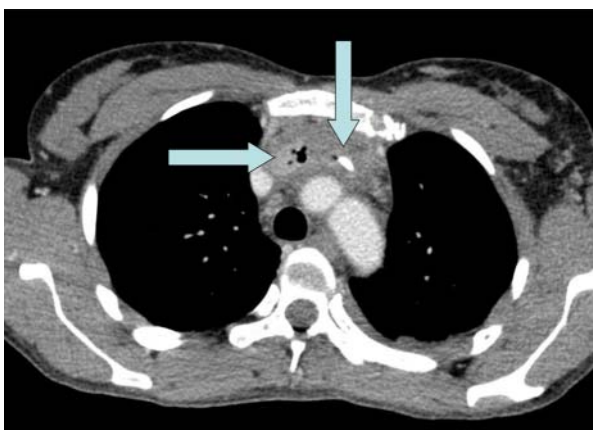


Figure 1 A thoracic CT scan revealing catheter-related (vertical arrow) partial superior vena cava thrombosis and complete innominate vein thrombosis, associated with gas bubbles (horizontal arrow).

This pdf has been created automatically from the final edited text and images.

Copyright 2012 BMJ Publishing Group. All rights reserved. For permission to reuse any of this content visit <http://group.bmj.com/group/rights-licensing/permissions>.

BMJ Case Report Fellows may re-use this article for personal use and teaching without any further permission.

Please cite this article as follows (you will need to access the article online to obtain the date of publication).

Leroy S, Piquet P, Chidiac C, Ferry T. Extensive thrombophlebitis with gas associated with continuous infusion of vancomycin through a central venous catheter. *BMJ Case Reports* 2012;10.1136/bcr-2012-006347, Published XXX

Become a Fellow of BMJ Case Reports today and you can:

- ▶ Submit as many cases as you like
- ▶ Enjoy fast sympathetic peer review and rapid publication of accepted articles
- ▶ Access all the published articles
- ▶ Re-use any of the published material for personal use and teaching without further permission

For information on Institutional Fellowships contact consortiasales@bmjgroup.com

Visit casereports.bmj.com for more articles like this and to become a Fellow