

Images in...

Spontaneous pneumomediastinum

Aizuri A Murad

Department of General Medicine, St. James's Hospital, Dublin, Ireland

Correspondence to Aizuri A Murad, aiz100@hotmail.com

DESCRIPTION

A 17-year-old male patient presented with non-exertional central chest tightness with gradual onset. There was no history of trauma. Physical examination was normal. CT scan of his thorax showed a pneumomediastinum with no other abnormalities. Further questioning revealed that he was doing vigorous sit-up exercises a few days before his presentation (figure 1). A repeat chest x-ray a few days later showed a resolution of his pneumomediastinum. He was completely well on follow-up a few weeks later without

any intervention.¹ The patient was reassured about the benign nature of this uncommon condition.

Competing interests None.

Patient consent Obtained.

REFERENCES

1. **Al-Mufarrej F**, Badar J, Gharagozloo F, *et al.* Spontaneous pneumomediastinum: diagnostic and interventions. *J Cardiothorac Surg* 2008;**3**:1–4.

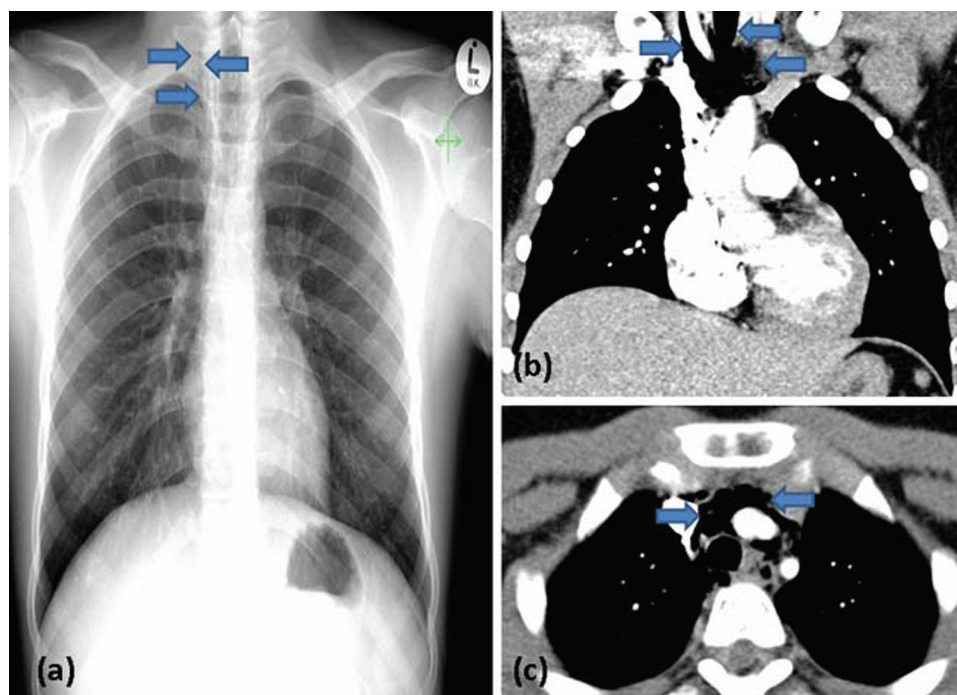


Figure 1 (A) Chest x-ray with mild signs of pneumomediastinum as shown by arrows. (B, C) Chest CT scan clearly demonstrating air within the superior mediastinum. No abnormalities were identified in the lung fields.

This pdf has been created automatically from the final edited text and images.

Copyright 2011 BMJ Publishing Group. All rights reserved. For permission to reuse any of this content visit <http://group.bmj.com/group/rights-licensing/permissions>.
BMJ Case Report Fellows may re-use this article for personal use and teaching without any further permission.

Please cite this article as follows (you will need to access the article online to obtain the date of publication).

Murad AA. Spontaneous pneumomediastinum. *BMJ Case Reports* 2011;10.1136/bcr.12.2010.3655, date of publication

Become a Fellow of BMJ Case Reports today and you can:

- ▶ Submit as many cases as you like
- ▶ Enjoy fast sympathetic peer review and rapid publication of accepted articles
- ▶ Access all the published articles
- ▶ Re-use any of the published material for personal use and teaching without further permission

For information on Institutional Fellowships contact consortiasales@bmjgroup.com

Visit casereports.bmj.com for more articles like this and to become a Fellow