

Images in...

Henoch—Schönlein purpura

S Moore,¹ A Bowden,¹ S Afify²¹Department of Rheumatology, Fairfield Hospital, Bury, UK;²Rochdale Infirmary, Rochdale, UK

Correspondence to S Moore, sarahswfc@hotmail.com

DESCRIPTION

A 63-year-old man with a history of intermittent vasculitic rash presented with an acute abdomen. Findings at laparotomy were consistent with patchy serosal small vessel vasculitis. The patient was well and walking around the ward 24 h later after intravenous methylprednisolone.

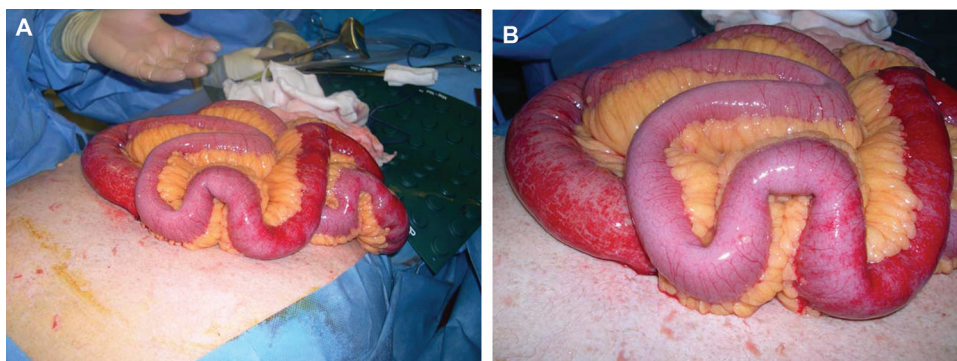
In this case no biopsy was taken. The diagnosis was made clinically given the history of intermittent vasculitic

rash and the classic appearance of the bowel at laparotomy (figure 1A,B). The prompt and complete response to steroids backed up the clinical impression.

Henoch—Schönlein purpura is uncommon in adults and gastrointestinal manifestations are rarely severe enough to require surgical intervention.

Competing interests None.

Patient consent Not obtained.



Figures 1 (A, B) Surgical images showing classic patchy serosal small vessel vasculitis of the bowel seen in Henoch—Schönlein purpura.

This pdf has been created automatically from the final edited text and images.

Copyright 2011 BMJ Publishing Group. All rights reserved. For permission to reuse any of this content visit

<http://group.bmj.com/group/rights-licensing/permissions>.

BMJ Case Report Fellows may re-use this article for personal use and teaching without any further permission.

Please cite this article as follows (you will need to access the article online to obtain the date of publication).

Moore S, Bowden A, Afify S. Henoch—Schönlein purpura. *BMJ Case Reports* 2011;10.1136/bcr.07.2010.3132, date of publication

Become a Fellow of BMJ Case Reports today and you can:

- ▶ Submit as many cases as you like
- ▶ Enjoy fast sympathetic peer review and rapid publication of accepted articles
- ▶ Access all the published articles
- ▶ Re-use any of the published material for personal use and teaching without further permission

For information on Institutional Fellowships contact consortiasales@bmjgroup.com

Visit casereports.bmj.com for more articles like this and to become a Fellow