

## Images in...

## Calcinosis cutis

Miguel F Carrascosa,<sup>1</sup> Francisco Pascual Velasco,<sup>1</sup> Alfonso Corrales Martínez,<sup>2</sup> Marta Fernández-Ayala Novo,<sup>1</sup> Elena Casuso Sáenz,<sup>1</sup> José-Ramón Salcines Caviedes<sup>1</sup>

<sup>1</sup>Internal Medicine Department, Hospital of Laredo-IFIMAV, Cantabria, Spain;

<sup>2</sup>Service of Rheumatology, University Hospital Marqués de Valdecilla-IFIMAV, Avda de, Santander, Cantabria, Spain

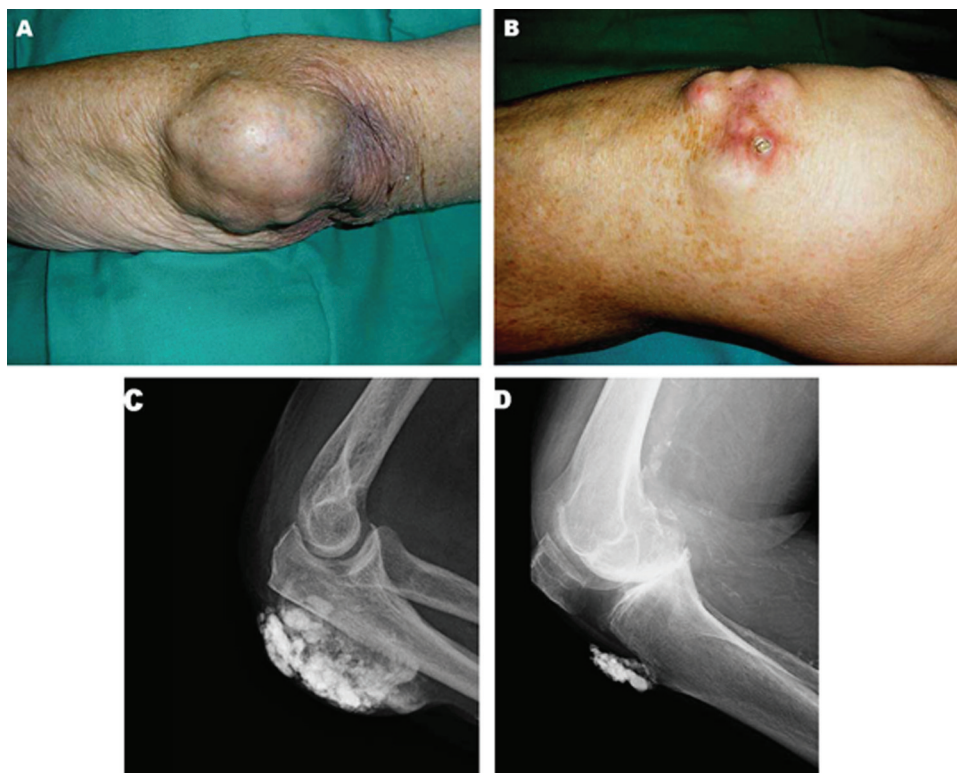
**Correspondence to** Dr Miguel F Carrascosa, miguel.carrascosa@scsalud.es

**DESCRIPTION**

An 87-year-old woman with a history of hypertension, atrial fibrillation, and mixed connective tissue disease was admitted to hospital because of heart failure. Besides clinical signs of ventricular dysfunction, physical examination showed painless, subcutaneous nodules that had developed during the past 10 years on her left elbow (figure 1A) and knees (figure 1B, right knee; note a large deposit breaking through the skin). A radiograph of the left elbow (figure 1C) and right knee (figure 1D) demonstrated multiple, heterogeneous soft-tissue calcified masses suggestive of calcinosis cutis. Her serum level of calcium, phosphate, intact parathyroid hormone and rheumatoid factor as well as renal function parameters were within normal limits. She afterwards died due to hospital-acquired pneumonia.

Calcinosis cutis, described by Virchow<sup>1</sup> in 1855, refers to the deposition of insoluble calcium salts into the skin and subcutaneous tissue. It has been divided into four

groups: metastatic, iatrogenic, idiopathic and dystrophic.<sup>2</sup> Metastatic calcification is related to abnormal calcium or phosphate metabolism and is generally associated with hypercalcaemia and/or hyperphosphatemia. Iatrogenic calcinosis cutis arises as complication of a therapeutic<sup>3</sup> or diagnostic procedure. It has been associated with subcutaneous injection of calcium-containing heparins,<sup>3</sup> extravasation of calcium gluconate and use of calcium-containing electrode compounds for electromyographic or electroencephalographic examination. Idiopathic calcinosis cutis occurs in the absence of known tissue injury or systemic metabolic defect. Finally, the dystrophic form is the most commonly described. Various conditions can cause this type of calcinosis, including connective tissue diseases, infection, other inflammatory processes, chronic venous stasis, cutaneous neoplasm, trauma and inherited disorders. The exact mechanism remains unclear although local inflammation may have a role in its pathogenesis.<sup>4</sup>



**Figure 1** Appearance of the left elbow (A) and the right knee (B) on clinical examination. Left elbow (C) and right knee (D) radiograph.

Treatment of calcinosis cutis in this setting have only marginal benefit, diltiazem and aluminum hydroxide antacids having been used.<sup>4</sup> However, early, effective management of the underlying disorder could reduce the development of such abnormality. Given that there was no other predisposing condition for calcinosis besides mixed connective tissue disease, we believe our patient had dystrophic calcinosis related to such disorder. The lack of any of the other diagnostic criteria for rheumatoid arthritis and the fact that almost all rheumatoid nodule formers have positive tests for rheumatoid factor made the diagnosis of rheumatoid nodules very unlikely. In addition, these nodules usually appear as non-calcified subcutaneous masses.

**Competing interests** None.

**Patient consent** Obtained.

## REFERENCES

1. **Virchow R.** Kalk-metastasen. *Virchows Arch Path Anat* 1855;**8**:103–13.
2. **Walsh JS,** Fairley JA. Calcifying disorders of the skin. *J Am Acad Dermatol* 1995;**33**:693–706; quiz 707–10.
3. **Boccaro O,** Prost-Squarcioni C, Battistella M, *et al.* Calcinosis cutis: a rare reaction to subcutaneous injections of calcium-containing heparin in patients with renal failure. *Am J Dermatopathol* 2010;**32**:52–5.
4. **Boorugu HK,** Chrispal A. Calcinosis cutis. *J Assoc Physicians India* 2008;**56**:870.

This pdf has been created automatically from the final edited text and images.

Copyright 2011 BMJ Publishing Group. All rights reserved. For permission to reuse any of this content visit <http://group.bmj.com/group/rights-licensing/permissions>.  
BMJ Case Report Fellows may re-use this article for personal use and teaching without any further permission.

Please cite this article as follows (you will need to access the article online to obtain the date of publication).

Carrascosa MF, Velasco FP, Martínez AC, Novo MF-A, Sáenz EC, Caviedes J-RS. Calcinosis cutis. *BMJ Case Reports* 2011;10.1136/bcr.01.2011.3732, date of publication

Become a Fellow of BMJ Case Reports today and you can:

- ▶ Submit as many cases as you like
- ▶ Enjoy fast sympathetic peer review and rapid publication of accepted articles
- ▶ Access all the published articles
- ▶ Re-use any of the published material for personal use and teaching without further permission

For information on Institutional Fellowships contact [consortiasales@bmjgroup.com](mailto:consortiasales@bmjgroup.com)

Visit [casereports.bmj.com](http://casereports.bmj.com) for more articles like this and to become a Fellow