

'Bubble sign': gas-forming bacteria from an odontogenic infection

Charlotte Richards,¹ Tom WM Walker,¹ Sarah Girgis,¹ Serryth Colbert²

¹Oral and Maxillofacial Surgery, University Hospitals Bristol NHS Foundation Trust, Bristol, UK
²Oral and Maxillofacial Surgery, Royal United Hospital Bath NHS Trust, Bath, UK

Correspondence to

Dr Charlotte Richards;
 charlotteannrichards@gmail.com

Accepted 8 May 2020

DESCRIPTION

A 64-year-old Caucasian woman presented to the emergency department with a 6-day history of dental pain and significant right-sided facial swelling. She had seen her general practitioner twice in the previous days and was prescribed oral metronidazole. There was a history of asthma, epilepsy and high blood pressure. She reported allergy to penicillin. On examination, she was tachycardic at 132 beats/min and tachypneic at 22 breaths/min. She was febrile at 39.7°C, her blood pressure was 147/65 mmHg and oxygen saturation's 95%. Her blood results showed a raised C-reactive protein (660), raised white cell count ($29.1 \times 10^9/L$) and raised neutrophils ($24.4 \times 10^9/L$). Clinically, there was high suspicion of sepsis, and the sepsis six pathway was initiated. A panoramic radiograph showed periapical radiolucencies associated with her carious lower right first premolar (LR5) and second molar (LR7) (figure 1). A diagnosis of a rapidly progressing odontogenic abscess was made.

Initial management involved intravenous fluids, intravenous paracetamol, intravenous 500mg metronidazole and intravenous 500mg clindamycin. CT revealed an extensive abscess with gas pockets adjacent to the right mandible, indicative of the severity of the infection (figure 2). She was taken to emergency theatre for dental extractions and drain placement.

Given the swelling extent, it was not surprising that frank pus was expressed through the extraction socket into the oral cavity following removal of LR7. What was surprising, however, was the presence of bubbles, representing escaped gas from the widespread subcutaneous emphysema passing through the pus (video 1).

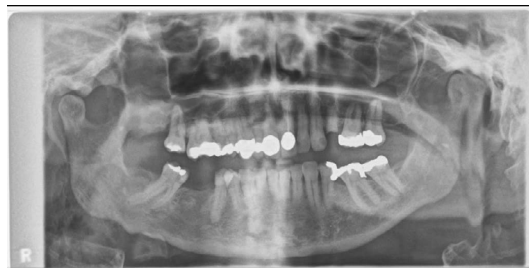

Figure 1 Panoramic radiograph showing carious lower right 5 and lower right 7, with periapical pathology associated with both teeth. The radiopacities in the right mandible reveal a chronic sclerosing osteitis, indicative of a long standing infection. Gas is also seen in the soft tissues around the right ramus.

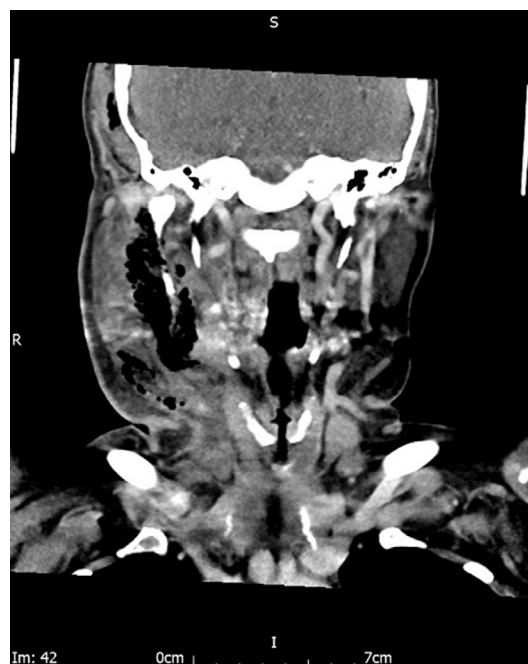
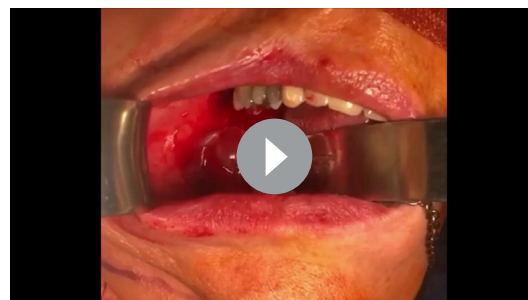

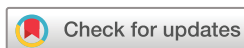Figure 2 Coronal CT slice revealing extensive subcutaneous gas in tissue spaces.

This previously undescribed clinical phenomenon indicates the presence of infection-related subcutaneous emphysema and is clearly useful to the surgeon working in a resource-poor clinical setting, or in the patient with severe odontogenic sepsis who is unsafe for cross-sectional imaging.

Following the initial drainage, there was continued pus production from all drain sites necessitating a further surgical intervention involving two general anaesthetics, two intravenous sedations and two local anaesthetic drainage procedures. She remained an inpatient for 25 days, with use of 5 antibiotics under advice of microbiology (clindamycin, metronidazole, vancomycin, doxycycline



Video 1 Intraoperative video of gas escaping during drainage of abscess.



© BMJ Publishing Group Limited 2020. No commercial re-use. See rights and permissions. Published by BMJ.

To cite: Richards C, Walker TWM, Girgis S, et al. *BMJ Case Rep* 2020;**13**:e233946. doi:10.1136/bcr-2019-233946

Images in...

and teicoplanin). Seven pus swabs were sent for micro, culture and sensitivity testing. Some unusual flora was cultured, including heavy growth of *Enterococcus faecalis*. Two further LA procedures were required during her 3-week outpatient follow-up.

The majority of the cultures were sensitive to penicillin, which highlights the importance of ensuring documentation of 'true' penicillin allergy and raises the question of whether an oral penicillin challenge may have reduced this patient's morbidity.¹ This was considered at day 10, but the patient did not consent. Oral provocation tests should be undertaken with medical supervision and involve incremental doses of the antibiotic.²

Those working in head and neck surgery should keep an eye out for this sign. It is clear that it demonstrates the severity of sepsis, and if encountered should alert the operator to a likely prolonged inpatient stay. The patient was fortunate; there are

many documented cases where odontogenic sepsis has resulted in death.^{3,4}

With many patients unable to access primary care dentistry, education for the entire medical profession is essential for rapid referral to a maxillofacial unit. Unfortunately, severe odontogenic infections fall into an educational gap between medicine and dentistry. Maxillofacial surgery is poorly represented in both the undergraduate medical and dental curriculum. Shanks *et al* determined that undergraduate medical students were poor at examination of the oral cavity.⁵ Furthermore, in the UK, general practice specifically precludes the assessment and treatment of dental disease, as doctors are not insured to carry out this work.

Acknowledgements The authors thank the patient for their consent to publish this case report.

Contributors CR and SG were responsible for writing and redrafting the report. TW provided the clinical video and idea for the case report, operated on the patient and advised on drafts. SC was the consultant in charge and has provided advice for improvement on drafts.

Funding The authors have not declared a specific grant for this research from any funding agency in the public, commercial or not-for-profit sectors.

Competing interests None declared.

Patient consent for publication Obtained.

Provenance and peer review Not commissioned; externally peer reviewed.

REFERENCES

- 1 National Institute for Health and Care Excellence. *Drug allergy: diagnosis and management of drug allergy in adults, children and young people*. NICE guideline, 2014: (CG183).
- 2 Drug and Therapeutics Bulletin. Penicillin allergy-getting the label right. *BMJ* 2017;358:j3402.
- 3 Carter L, Lewis E. Death from overwhelming odontogenic sepsis: a case report. *Br Dent J* 2007;203:241–2.
- 4 Dalla Torre D, Brunold S, Kisielesky I, *et al*. Life-Threatening complications of deep neck space infections. *Wien Klin Wochenschr* 2013;125:680–6.
- 5 Shanks LA, Walker TWM, McCann PJ, *et al*. Oral cavity examination: beyond the core curriculum? *Br J Oral Maxillofac Surg* 2011;49:640–2.

Patient's perspective

I felt frightened of all the procedures that I had done, and was scared because of the length of time I spent in hospital.

Learning points

- Bubbles forming in pus is a useful clinical sign which indicates a rapidly developing infection in the head and neck.
- Dental infections can quickly lead to airway compromising and potentially life-threatening sepsis, and education of the entire medical profession is essential.
- For this patient, surgical intervention alone was unsuccessful and involvement of medical microbiologists was essential for patient survival, and there may have been a place for a penicillin challenge.

Copyright 2020 BMJ Publishing Group. All rights reserved. For permission to reuse any of this content visit <https://www.bmj.com/company/products-services/rights-and-licensing/permissions/>
BMJ Case Report Fellows may re-use this article for personal use and teaching without any further permission.

Become a Fellow of BMJ Case Reports today and you can:

- Submit as many cases as you like
- Enjoy fast sympathetic peer review and rapid publication of accepted articles
- Access all the published articles
- Re-use any of the published material for personal use and teaching without further permission

Customer Service

If you have any further queries about your subscription, please contact our customer services team on +44 (0) 207111 1105 or via email at support@bmj.com.

Visit casereports.bmj.com for more articles like this and to become a Fellow