



OPEN ACCESS

Case report

Family cluster of three recovered cases of pneumonia due to severe acute respiratory syndrome coronavirus 2 infection

Yong Xiong,¹ Shihui Song,¹ Guangming Ye,² Xinghuan Wang³

¹Department of Infectious Disease, Zhongnan Hospital of Wuhan University, Wuhan, China

²Department of Laboratory, Zhongnan Hospital of Wuhan University, Wuhan, China

³Center for Evidence-Based and Translational Medicine, Zhongnan Hospital of Wuhan University, Wuhan, China

Correspondence to

Dr Xinghuan Wang;
wangxinghuan@whu.edu.cn

Accepted 17 April 2020

SUMMARY

The coronavirus disease (COVID-19) outbreak caused by severe acute respiratory syndrome coronavirus 2 (SARS-CoV-2) was first reported in Wuhan, China, in late 2019 and has affected more than 1 270 000 people worldwide. The numbers of reported cases continue to rise and threaten global health. Transmissions among family members are frequently observed, although the route of transmission is partially known. Here we report three cases of SARS-CoV-2 infection within one family. Sequencing of the S gene of the viral genome showed 100% identity among samples, suggesting that the same strain caused the infection. Following treatment with oseltamivir and short-term methylprednisolone combined with symptomatic management, all three patients recovered within 3 weeks, as evidenced by the disappearance of their symptoms, clearance of pulmonary infiltrates and consecutive negative molecular diagnostic test findings. Our observations suggest the importance of preventing family transmission and the efficacy of current integrated treatment for mild/moderate pneumonia in COVID-19 cases.

BACKGROUND

Severe acute respiratory syndrome coronavirus 2 (SARS-CoV-2) is the pathogen responsible for the ongoing outbreak of pneumonia in Wuhan, China. Since the first cluster of atypical pneumonia cases was reported on 31 December 2019,¹ the disease has spread with surprising speed. While much attention has been focused on viral transmission dynamics and the spectrum of clinical illness, these aspects are not yet completely understood.^{2–8} This report describes the epidemiological and clinical features of coronavirus disease (COVID-19) among three members of a family following SARS-CoV-2 infection. Owing to the unavailability of effective vaccines for the prevention of SARS-CoV-2, most preventive measures aim to reduce the risk of infection.⁹ Despite several recommended drugs, including the combination of lopinavir/ritonavir, nelfinavir and interferon-beta-1b, effective treatment options are scarce.² Hence, prevention of infection is of utmost importance. We provide evidence to support the increasing concerns regarding person-to-person transmission of SARS-CoV-2.

CASE PRESENTATION

On 10 and 11 January 2020, a family of three, comprising the father (65 years), the mother (61

years) and the son (38 years), were admitted to the Department of Infectious Disease at the Zhongnan Hospital of Wuhan University with symptoms of cough and fever. On 21 December 2019, the mother had started coughing with expectoration. Five days later, the father also developed a cough; he developed fever 7 days prior to admission. He had a history of hypertension and coronary heart disease, for which he had received a stent. Both had symptoms of restricted breathing. On 3 January 2020 (12 days after the mother's illness), the son developed a cough. Prior to admission, all three patients experienced fatigue and intermittent fever (37.9°C–39.1°C) for at least 1 day (figure 1). They had no shortness of breath or chest pain.

Physical examination revealed some degree of tonsil enlargement in the father and the son. Lung auscultation revealed rhonchi in the father and the mother. Other examination findings were generally unremarkable. None of the patients had visited the Huanan Seafood Wholesale Market in Wuhan or the surrounding area in the previous 2 weeks. They denied any contact with diagnosed patients with similar symptoms.

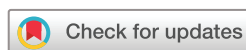INVESTIGATIONS

On admission, haemograms revealed lymphocyte counts reduced by nearly 50% in the mother and near-to-low-normal in the father and the son. Other parameters such as white cell count, neutrophil and blood platelet counts were near-to-low-normal, suggesting not only lymphopaenia but also a haematological regeneration abnormality following infection. Moreover, all of these parameters doubled on discharge of the patients from the hospital. None of the patients had abnormal haemoglobin values. Oxygen saturation values were normal. Additional laboratory investigations in these three patients showed no abnormalities except for increased C reactive protein levels (table 1).

Pneumonia was diagnosed based on chest CT scans. The mother's lung showed a peripheral lesion with increased intensity and bilateral patchy shadows in the outer zone of the lungs. Numerous patchy or segmental ground-glass opacities were observed in both lungs of the father and the son.¹⁰ The lung opacities started to clear after 10 days of hospitalisation (figure 2).

DIFFERENTIAL DIAGNOSIS

Rapid nucleic acid amplification tests for respiratory syncytial virus, adenovirus, influenza virus A



© BMJ Publishing Group Limited 2020. Re-use permitted under CC BY-NC. No commercial re-use. See rights and permissions. Published by BMJ.

To cite: Xiong Y, Song S, Ye G, et al. *BMJ Case Rep* 2020;**13**:e235302. doi:10.1136/bcr-2020-235302

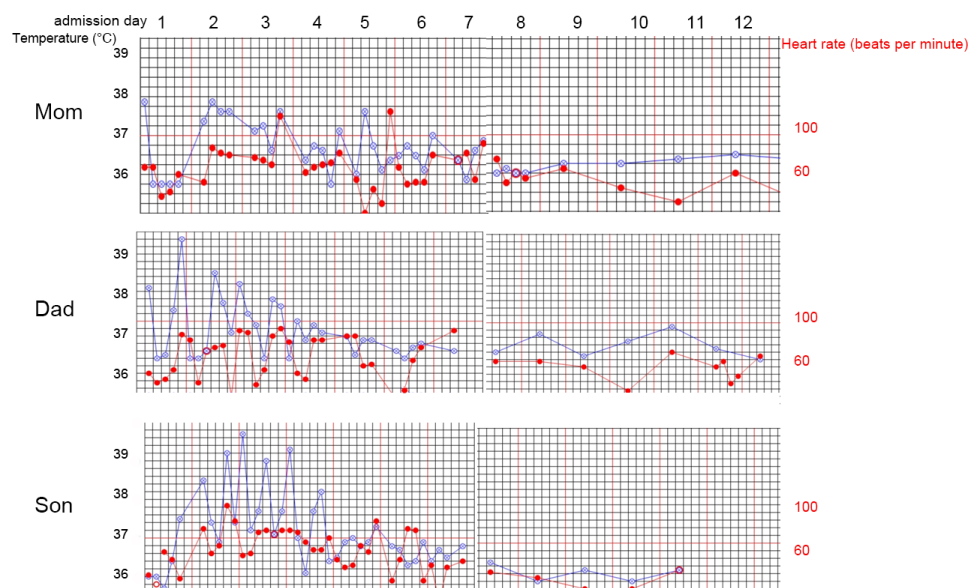


Figure 1 Body temperature (blue) and heart rate (red) values after hospitalisation. The temperature of all three patients decreased within 3–5 days. The mother experienced only occasional febrile episodes, while the son had moderate-to-high fever for 4 days after admission.

and B, parainfluenza virus, *Chlamydomphila*, and *Mycoplasma* were all negative. On admission day 10, real-time reverse transcription PCR (RT-PCR) assay for SARS-CoV-2 tested positive in all three patients (table 2).

TREATMENT

The treatment during hospitalisation was largely supportive. The patients intermittently received supplemental oxygen through a nasal cannula at a rate of 2 L per minute. Owing to the difficulties in early diagnosis, all three patients were initially treated for suspected influenza with 75 mg oseltamivir phosphate capsules two times per day for the first 5 days of hospitalisation. The patients received 80 mg of methylprednisolone sodium succinate per day for the first 3 days, followed by 40 mg per day during the following 3 days, and 20 mg per day for another 3 days before being discontinued. The father received methylprednisolone at a dose of 40 mg per day for 5 days and 20 mg per day for another 5 days.

Considering the possibility of bacterial coinfection, the mother and the father were administered amoxicillin sodium-flucloxacillin sodium (6 g, intravenous infusion every 12 hours) for 2 weeks. The son received ceftriaxone-tazobactam (2 g, intravenous infusion, every 12 hours) for 3 days, followed by biapenem (0.3 g, intravenous infusion every 8 hours) for another 9 days.

Additionally, the mother and the son were administered levofloxacin (0.4 g, intravenous infusion, daily) starting on admission day 6 until day 14. The father received moxifloxacin (0.4 g, intravenous infusion, daily) for 2 weeks starting on admission day 1.

The fever disappeared in all three patients approximately 5–7 days following admission and their clinical conditions further improved thereafter. After approximately 3 weeks of hospitalisation, lung inflammation had largely resolved, as indicated by CT scans, and two consecutive throat swab samples tested negative for SARS-CoV-2 with the RT-PCR test performed for each

Table 1 Changes in the key indicators of laboratory results in the three patients

Indicators	White cell count ($\times 10^9/L$)	Neutrophils ($\times 10^9/L$)	Lymphocytes ($\times 10^9/L$)	Haemoglobin (g/L)	Blood platelet ($\times 10^9/L$)	Procalcitonin (ng/mL)
Reference range	3.5–9.5	1.8–6.3	1.1–3.2	130–175	125–350	<0.05
Patient/date						
Mother/11 January	3.85	2.78	0.59	120	198	<0.05
Mother/14 January	4.56	3	0.99	122	266	ND
Mother/20 January	7.94	4.92	2.13	126	376	<0.05
Father/11 January	3.89	2.45	1.03	143	113	<0.05
Father/14 January	5.75	3.78	1.34	139	139	ND
Father/20 January	7.96	4.53	2.52	140	312	<0.05
Father/29 January	5.5	3.28	1.53	155	221	<0.05
Son/10 January	5.83	4.1	1.23	118	170	<0.05
Son/13 January	7.36	6.19	0.78	112	247	<0.05
Son/15 January	5.86	5.02	0.52	114	402	ND
Son/20 January	15.2	10.11	3.31	132	618	<0.05
Son/23 January	11.8	7.9	2.6	120	417	ND

ND, not detected.

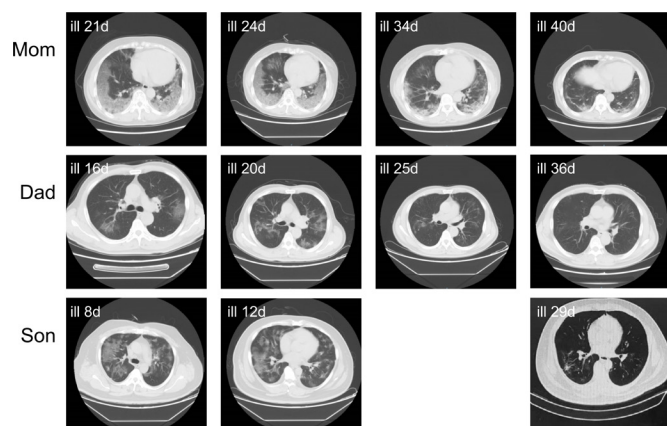


Figure 2 Chest CT scans of the three patients. The mother's lung shows a peripheral lesion with increased intensity and bilateral patchy shadows in the outer zones. Multiple patchy or segmental ground-glass opacities were observed in both lungs of the father and the son.

patient. The patients were discharged from hospital and were required to stay home for further recovery. They have reported no new symptoms.

OUTCOME AND FOLLOW-UP

Results of quantitative RT-PCR testing for SARS-CoV-2

Due to the initial shortage of testing kits for SARS-CoV-2, the cases were not diagnosed until 20 January 2020. Throat swabs obtained from all three patients on admission day 9 tested positive. Subsequently, throat swabs obtained from them on admission days 18 and 20 tested negative for SARS-CoV-2 (figure 1).

Genetic sequencing of the viral S gene

The genetic sequences of the viral S gene from samples collected from each family member were identical (data not shown) to each other and also were 100% identical to the reported viral strain (WHU01) currently spreading in Wuhan.

Table 2 Results of reverse transcription PCR assay for severe acute respiratory syndrome coronavirus 2

	Specimen	Admission day 9	Admission day 18	Admission day 20
Mother	Throat swab	Positive	Negative	Negative
Father	Throat swab	Positive	Negative	Negative
Son	Throat swab	Positive	Negative	Negative

DISCUSSION

Our results not only support human-to-human transmission but also suggest that close contact within families is a high-risk factor. Effective intervention measures for the prevention of family transmission need to be adopted.

Learning points

- Severe acute respiratory syndrome coronavirus 2 transmission among family members was confirmed.
- The patients recovered after treatment with oseltamivir and methylprednisolone.
- Prevention of family transmission is important.
- The current integrated treatment for mild/moderate pneumonia is effective in COVID-19.

Acknowledgements We thank all the doctors and nurses who cared for these three patients.

Contributors The case report was written by YX and SS and edited by GY and XW.

Funding This study was funded by the Medical Science Advancement Program (Clinical Medicine) of Wuhan University (grant number TFLC2018002).

Competing interests None declared.

Patient consent for publication Obtained.

Provenance and peer review Not commissioned; externally peer reviewed.

Open access This is an open access article distributed in accordance with the Creative Commons Attribution Non Commercial (CC BY-NC 4.0) license, which permits others to distribute, remix, adapt, build upon this work non-commercially, and license their derivative works on different terms, provided the original work is properly cited and the use is non-commercial. See: <http://creativecommons.org/licenses/by-nc/4.0/>.

REFERENCES

- 1 World Health Organization. Pneumonia of unknown cause China, 2020. Available: www.who.int/csr/don/05-january-2020-pneumonia-of-unknown-cause-china/en/ [Accessed 16 Apr 2020].
- 2 Li X, Zai J, Wang X, et al. Potential of large "first generation" human-to-human transmission of 2019-nCoV. *J Med Virol* 2020;92:448–54.
- 3 Chen N, Zhou M, Dong X, et al. Epidemiological and clinical characteristics of 99 cases of 2019 novel coronavirus pneumonia in Wuhan, China: a descriptive study. *Lancet* 2020;395:507–13.
- 4 Chan JF-W, Yuan S, Kok K-H, et al. A familial cluster of pneumonia associated with the 2019 novel coronavirus indicating person-to-person transmission: a study of a family cluster. *Lancet* 2020;395:514–23.
- 5 Phan LT, Nguyen TV, Luong QC, et al. Importation and human-to-human transmission of a novel coronavirus in Vietnam. *N Engl J Med* 2020;382:872–4.
- 6 Rothe C, Schunk M, Sothmann P, et al. Transmission of 2019-nCoV infection from an asymptomatic contact in Germany. *N Engl J Med* 2020;382:970–1.
- 7 Li Q, Guan X, Wu P, et al. Early transmission dynamics in Wuhan, China, of novel coronavirus-infected pneumonia. *N Engl J Med* 2020;382:1199–207.
- 8 Zhu N, Zhang D, Wang W, et al. A novel coronavirus from patients with pneumonia in China, 2019. *N Engl J Med* 2020;382:727–33.
- 9 Liu X, Wang X-J. Potential inhibitors against 2019-nCoV coronavirus M protease from clinically approved medicines. *J Genet Genomics* 2020;47:119–21.
- 10 Wang D, Hu B, Hu C, et al. Clinical characteristics of 138 hospitalized patients with 2019 novel coronavirus-infected pneumonia in Wuhan, China. *JAMA* 2020. doi:10.1001/jama.2020.1585. [Epub ahead of print: 07 Feb 2020].

Copyright 2020 BMJ Publishing Group. All rights reserved. For permission to reuse any of this content visit <https://www.bmj.com/company/products-services/rights-and-licensing/permissions/>
BMJ Case Report Fellows may re-use this article for personal use and teaching without any further permission.

Become a Fellow of BMJ Case Reports today and you can:

- ▶ Submit as many cases as you like
- ▶ Enjoy fast sympathetic peer review and rapid publication of accepted articles
- ▶ Access all the published articles
- ▶ Re-use any of the published material for personal use and teaching without further permission

Customer Service

If you have any further queries about your subscription, please contact our customer services team on +44 (0) 207111 1105 or via email at support@bmj.com.

Visit casereports.bmj.com for more articles like this and to become a Fellow