

Calcification in the wall of brain abscess

Thumati Sanjay,¹ Rajeev Ranjan,² Anirudda Deshpande³

¹Department of Neurosurgery, Rohini Superspecialty Hospital, Warangal, Telangana, India

²Department of Neurology, Max Care Hospital, Warangal, Telangana, India

³Department of Neurology, Vinayaka Neuro Multispecialty Clinic, Warangal, Telangana, India

Correspondence to

Dr Anirudda Deshpande, dr.anirudda.deshpande@gmail.com

Accepted 7 December 2018

DESCRIPTION

We report a 17-year-old young man who was an epileptic since the age of 2 years. The patient was brought to the emergency medical ward with multiple episodes of seizures. The semiology of the seizures was right partial with secondary generalisation.

On taking the clinical history from the patient's mother, she recalled that the patient had high-grade fever, recurrent vomiting, seizures and altered sensorium at the age of 2 years. The patient was given intravenous antiepileptics and antibiotics for more than a week. He was later shifted to a syrup formulation of antiepileptic medications (details of which are unavailable).

Subsequently, the patient was irregular in taking antiepileptic medications, resulting in frequent seizures at various intervals. CT scan was done approximately 9 months prior to the present hospitalisation. It showed a thick-walled, lentiform shaped, calcific rim (yellow arrow) surrounding an isodense area on the left temporo-occipital lobe of the cerebral hemisphere resembling a brain abscess (red arrow; [figure 1](#)). Contrast study images were unavailable. The patient was advised surgery. However, the patient's family did not comply with the advice. The patient continued the antiepileptic medication, although irregularly.

On the emergency medical ward, the patient was given injectable phenytoin 10 mg/kg body weight as

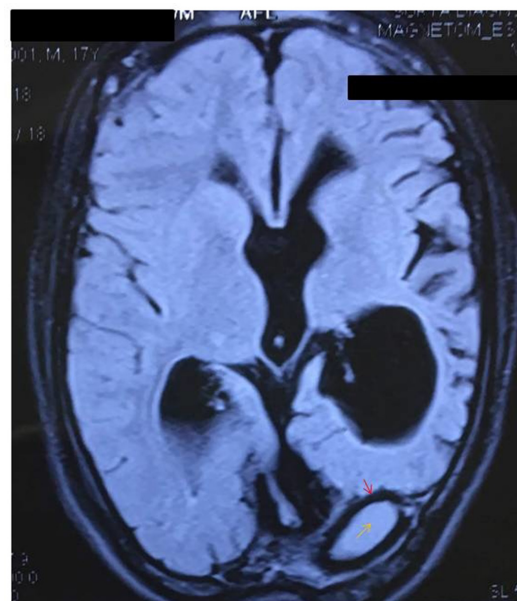


Figure 2 The fluid-attenuated inversion recovery axial sequence of MRI brain showing a lentiform shaped, hypointense rim (red arrow) surrounding an island of isointense liquefied material in the left temporo-occipital lobe (yellow arrow).

loading dose. An MRI of the brain was done to look for structural abnormality in the brain parenchyma.

The fluid-attenuated inversion recovery axial sequence of MRI brain ([figure 2](#)) showed a lentiform shaped, hypointense rim (red arrow) surrounding an island of isointense liquefied material in the left temporo-occipital lobe (yellow arrow).

The T2-weighted axial sequence ([figure 3](#)) showed a hypointense lentiform rim (red arrow) surrounding an island of liquefied material which was hyperintense (blue arrow). The susceptibility-weighted axial image showed blooming of the lentiform rim ([figure 4](#); red arrow) suggestive of probable calcification. The island of liquefied material within the calcific wall was isointense (yellow arrow), highly suggestive of brain abscess surrounded by calcific wall.

The calcific wall along with the brain abscess was completely excised, and the patient was advised 6 weeks of intravenous nafcillin 2 g every fourth hourly, metronidazole 500 mg every eighth hourly and prophylactic four drug antitubercular therapy (isoniazid 150 mg/rifampicin 450 mg/pyrazinamide 750 mg/ethambutol 800 mg along with pyridoxine 20 mg once daily) empirically for a period of 1 year (with regular follow-up).

Postoperative histopathology and microbiology evaluation revealed liquefactive material containing predominantly lymphocytic inflammatory

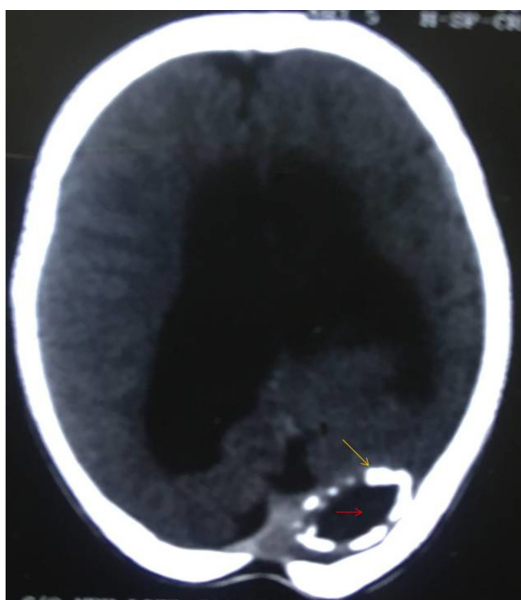
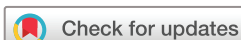

Figure 1 CT brain shows a thick-walled, lentiform shaped, calcific rim surrounding (yellow arrow) an isodense area on the left temporo-occipital lobe of the cerebral hemisphere resembling a brain abscess (red arrow).



© BMJ Publishing Group Limited 2019. No commercial re-use. See rights and permissions. Published by BMJ.

To cite: Sanjay T, Ranjan R, Deshpande A. *BMJ Case Rep* 2019;**12**:e228426. doi:10.1136/bcr-2018-228426

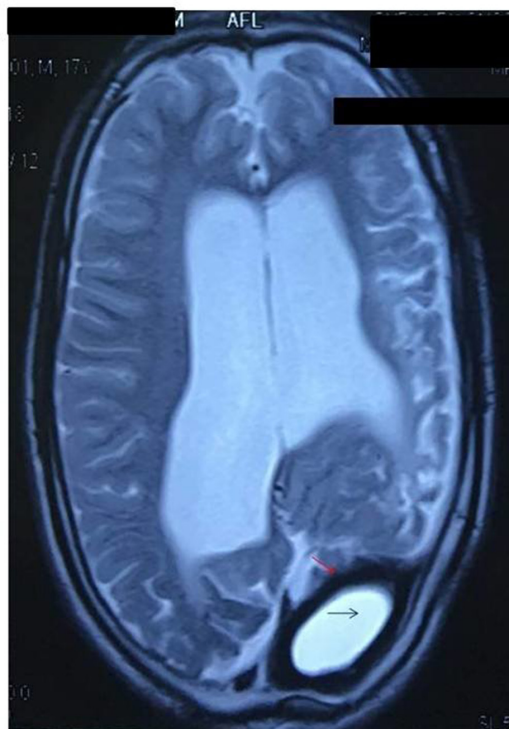


Figure 3 The T2-weighted axial sequence showing a hypointense lentiform rim (red arrow) surrounding an island of liquefied material which was hyperintense (blue arrow).

infiltrate, hence suggestive of the brain abscess. Gram staining for Gram-positive/Gram-negative organisms and Ziehl Nielsen staining for acid-fast bacilli were negative. This could be

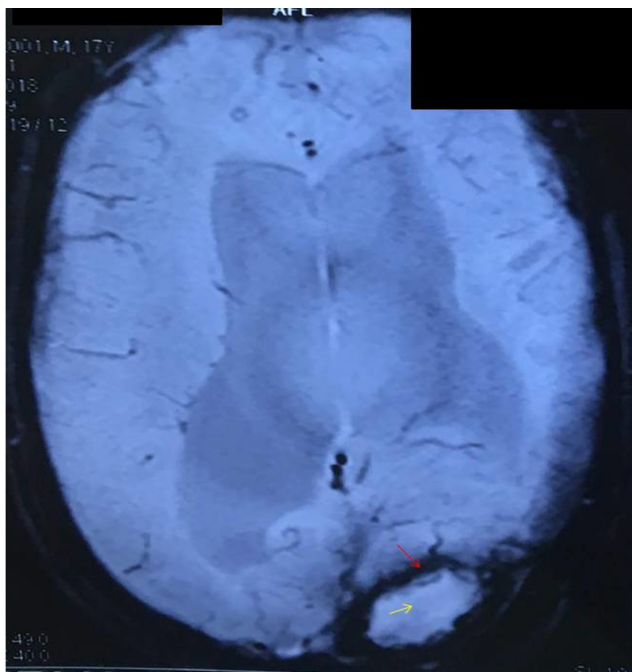


Figure 4 The susceptibility-weighted axial image showing blooming of the lentiform rim (red arrow) suggestive of probable calcification.

Learning points

- Brain abscess is a collection of pus which is surrounded by a capsule which is usually well vascularised.
- Calcification is common with tuberculosis and cysticercosis and is rare in brain abscess of other bacterial origin.
- Meningitis predisposes to brain abscess with calcification. The calcific rim formation was proposed to be due to a long course of development of abscess postmeningitis.

attributed to the chronicity of patients indolent illness. The parasitic tests in the form of IgM toxoplasmosis were negative. Cerebrospinal Fluid (CSF) PCR for toxoplasmosis could not be done due to cost constraints. As the patient could not afford prolonged hospital stay, bacterial/tubercular culture sensitivity and repeat imaging of brain, and he had to be discharged against medical advice and lost to follow-up.

Brain abscess is a collection of pus which is surrounded by capsule which is usually well vascularised. The incidence of brain abscesses is roughly 8% of intracranial masses in low-income and middle-income countries. In the west, the incidence is about 1%–2%.

For the brain abscess to develop, inoculation of an organism is required into the brain parenchyma where there is a devitalised of brain tissue. It may also develop in a region with poor microcirculation. The lesion evolves from an early cerebritis stage to the stage of organisation and capsule formation. Contiguous spread, haematogenous dissemination or following trauma are the common modes of entry of organisms leading to brain abscess.

Calcification is common with tuberculosis and cysticercosis and is rare in brain abscess of other bacterial origin.¹ Meningitis predisposes to brain abscess with calcification. The calcific rim formation was proposed to be due to a long course of development of abscess postmeningitis.² Differential diagnosis to be considered here are metastasis, primary brain tumour, resolving haematoma, tuberculomas, hydatid cyst and demyelinating disorders. Clinical features of fever and meningism, and radiological features of reduction of ring enhancement in delayed scan, finding of gas within the lesion, multilocularity, leptomeningeal or ependymal enhancement favour the diagnosis of brain abscess.³

Contributors TS and RR made substantial contributions to the conception and design of the work; acquisition, analysis and interpretation of the data. TS and AD were involved in drafting the work and revising it critically for important intellectual content. AD approved the final version to be published.

Funding The authors have not declared a specific grant for this research from any funding agency in the public, commercial or not-for-profit sectors.

Competing interests None declared.

Patient consent Obtained.

Provenance and peer review Not commissioned; externally peer reviewed.

REFERENCES

- 1 Chowdhury F, Haque M, Sarkar M, et al. Brain abscess: surgical experiences of 162 cases. *Neuroimmunol Neuroinflamm* 2015;2:153–61.
- 2 Kim HS, Kim DM, Ju CI, et al. Intracranial calcification caused by a brain abscess : a rare cause of intracranial calcification. *J Korean Neurosurg Soc* 2013;54:148–50.
- 3 Rizvi T, Garg A, Singh M, et al. Large intracranial mass with a calcified rim - is it a brain abscess? *Pediatr Neurosurg* 2005;41:112–4.

Copyright 2018 BMJ Publishing Group. All rights reserved. For permission to reuse any of this content visit <https://www.bmj.com/company/products-services/rights-and-licensing/permissions/>
BMJ Case Report Fellows may re-use this article for personal use and teaching without any further permission.

Become a Fellow of BMJ Case Reports today and you can:

- ▶ Submit as many cases as you like
- ▶ Enjoy fast sympathetic peer review and rapid publication of accepted articles
- ▶ Access all the published articles
- ▶ Re-use any of the published material for personal use and teaching without further permission

For information on Institutional Fellowships contact consortiasales@bmjgroup.com

Visit casereports.bmj.com for more articles like this and to become a Fellow