

# An interesting case of vanishing shoulder

Shishir Murugharaj Suranigi,<sup>1</sup> Abhay Harsh Kerketta,<sup>1</sup> Pasupathy Palaniappan,<sup>1,2</sup> Syed P Najimudeen<sup>1</sup>

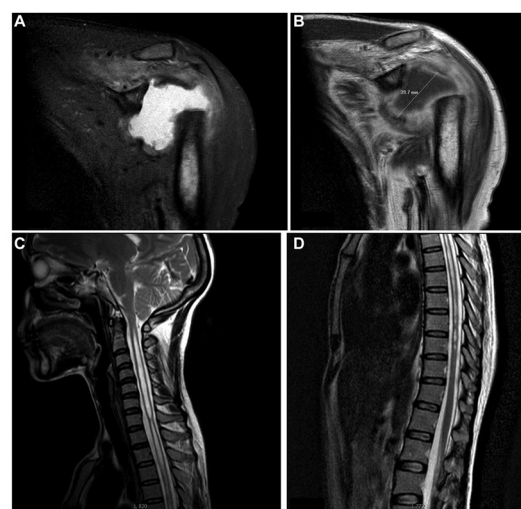
<sup>1</sup>Department of Orthopaedics, Pondicherry Institute of Medical Sciences, Pondicherry, India  
<sup>2</sup>Department of Orthopaedics, Jawaharlal Institute of Postgraduate Medical Education, Pondicherry, India

**Correspondence to**  
Dr Pasupathy Palaniappan,  
drastos@gmail.com

Accepted 17 August 2018

## DESCRIPTION

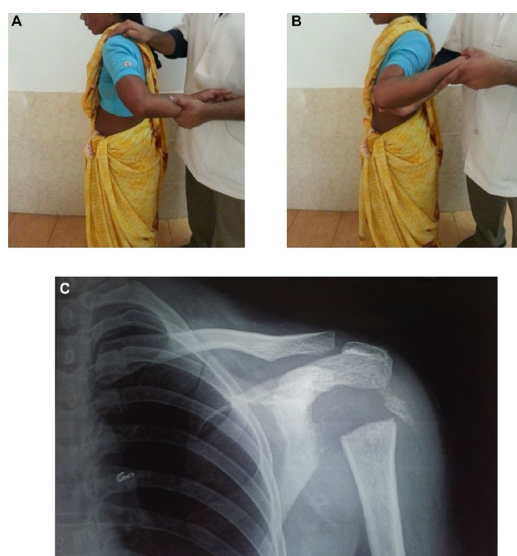A 37-year-old woman with progressive difficulty in using her left arm and with discomfort in the left shoulder was evaluated. Her complaints were of insidious onset and progressed over a period of 3 months. She had a soft shoulder and passive movements in the left shoulder were increased in all ranges, with internal and external rotation of 180° each (figure 1A,B). Active abduction was up to 90°. Radiographs of the shoulder demonstrated the absence of humeral head and a small sliver of bone, reminiscent of the greater tubercle (figure 1C). She was evaluated for neuropathic arthropathy, infection, neoplastic, metabolic and endocrine causes of osteolysis using appropriate blood tests and imaging techniques. Her blood parameters were normal. MRI confirmed absence of the proximal humerus and resorption and expansion of the glenoid cavity (figure 2A,C). A syrinx extending from the C2–D9 spinal region (figure 2C,D) was incidentally found corroborating with the suspicion of neuropathy, but the patient had no neurological manifestations and the nerve conduction tests were normal. Presence of pain, extensive osteolysis and absence of neuropathy led to the suspicion of Gorham-Stout syndrome (GSS). Since the patient had minimal disability, she was not willing for a biopsy or any form of surgical intervention. Due to lack of convincing evidence in the literature, pharmacotherapy was not tried and the patient was



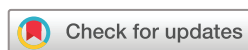**Figure 2** (A,B) T1-weighted and T2-weighted MRI demonstrating absence of the humeral head and the shoulder joint distended with fluid. (C and D) T2-weighted MRI revealing a syrinx involving the cervical and dorsal spinal segments.

put on a regimen of shoulder strengthening and range of motion exercises. On telephonic enquiry, she revealed that the disability did not worsen at 2 years and hence refused further hospital visits. GSS is a rare disease, and to the best of our knowledge its presentation alongside an extensive syrinx is not reported in the literature.

GSS is included in a heterogeneous group of disorders characterised by idiopathic osteolysis.<sup>1</sup> GSS affects both the axial and appendicular skeletons, but has a preponderance towards the maxillofacial bones, the shoulder and the pelvic girdles. The aetiology of GSS is not very clear. Dysregulation of osteoclast function and proliferation of lymphangiomatous tissues have been considered the widely accepted theories.<sup>1</sup> The disease can be mono-ostotic or polyostotic and is self-limiting, but the prognosis may vary depending on the site and severity of osteolysis. Localised bone resorption may be the only feature in the initial stages when the disease may be entirely asymptomatic, the disease being detected only after a pathological fracture or incidentally on radiographs. Asymptomatic disease does not warrant surgical intervention except when the disease involves the weight-bearing bones and the spine, where prompt excision of the disease tissue and stabilisation may prevent disastrous complications. Advanced disease of the spine and the thorax may present with neurological deficits or chylothorax, respectively. Finding non-malignant proliferation of small vessels in the biopsy specimen



**Figure 1** (A,B) Exaggerated external and internal rotation with the shoulder abducted to 90°. (C) A plain radiograph of the shoulder joint demonstrating resorption of the humeral head.



© BMJ Publishing Group Limited 2018. No commercial re-use. See rights and permissions. Published by BMJ.

**To cite:** Suranigi SM, Kerketta AH, Palaniappan P, et al. *BMJ Case Rep* Published Online First: [please include Day Month Year]. doi:10.1136/bcr-2018-226768

## Images in...

with a clinical background of unprovoked osteolysis and pain is confirmatory of GSS.<sup>2</sup>

The treatment usually involves excision of the disease tissue and reconstruction with bone graft and prostheses depending

on the affected site and expected complications. Treatment with vitamin D, calcitonin, bisphosphonates and radiation has been tried in the past with varied outcomes.<sup>3</sup>

### Learning points

- ▶ Although a rare entity, Gorham-Stout syndrome should be considered in the differential diagnosis in cases of unprovoked osteolysis and pain even in the presence of a syrinx, and has to be differentiated from neuropathic arthropathy, where surgical outcomes are poor.
- ▶ The treatment options are varied and should be tailored as per the needs of the patient and the site and severity of the disease.
- ▶ Vitamin D, bisphosphonates, calcitonin and radiation, which have been shown to arrest disease progression, may be of use in the early stages.

**Contributors** SMS: treating surgeon, data collection and manuscript review. AHK: treating surgeon and manuscript review. PP: treating surgeon, data collection and manuscript preparation. SPN: treating surgeon and manuscript review.

**Funding** The authors have not declared a specific grant for this research from any funding agency in the public, commercial or not-for-profit sectors.

**Competing interests** None declared.

**Patient consent** Obtained.

**Provenance and peer review** Not commissioned; externally peer reviewed.

### REFERENCES

- 1 El-Kouba G, de Araújo Santos R, Pilluski PC, *et al*. GORHAM-STOUT SYNDROME: PHANTOM BONE DISEASE. *Rev Bras Ortop* 2010;45:618–22.
- 2 Nikolaou VS, Chytas D, Korres D, *et al*. Gorham-Stout syndrome): A review of a rare entity. *World J Orthop* 2014;5:694–8.
- 3 Rao P, Kotwal PP, Goel S. Painless destruction of the shoulder joint: a case report. *Clin Rheumatol* 2001;20:143–6.

Copyright 2018 BMJ Publishing Group. All rights reserved. For permission to reuse any of this content visit <http://group.bmj.com/group/rights-licensing/permissions>.  
BMJ Case Report Fellows may re-use this article for personal use and teaching without any further permission.

Become a Fellow of BMJ Case Reports today and you can:

- ▶ Submit as many cases as you like
- ▶ Enjoy fast sympathetic peer review and rapid publication of accepted articles
- ▶ Access all the published articles
- ▶ Re-use any of the published material for personal use and teaching without further permission

For information on Institutional Fellowships contact [consortiasales@bmjgroup.com](mailto:consortiasales@bmjgroup.com)

Visit [casereports.bmj.com](http://casereports.bmj.com) for more articles like this and to become a Fellow