Renal cell carcinoma with level 2 IVC thrombus

Samarth Agarwal, Ram Niwas Yadav, Gaurav Garg, Manoj Kumar

Department of Urology, King George's Medical University, Lucknow, Uttar Pradesh, India

Correspondence to
Dr Samarth Agarwal,
rebellite@gmail.com

Accepted 22 June 2018

DESCRIPTION

A 40-year-old male patient, a chronic smoker for the last 10 years, presented with oedema of the lower legs and gross painless haematuria of 2 months duration. He also gave history of weight loss and loss of appetite. Physical examination revealed a right abdominal mass. Complete blood haemogram was normal. A comprehensive metabolic evaluation including serum calcium levels, C-reactive protein, liver function and urinalysis was also found normal.

Multidetector CT scan showed a right renal tumour of size 8×8 cm involving upper and mid-pole with tumour thrombus extending from the renal vein (RV) into the infrahepatic inferior vena cava (IVC) (figure 1). CT angiography was further performed to confirm the vascularity and extent of RV thrombus as shown in figure 2.

X-ray chest did not show any pulmonary metastasis. The rest of the metastatic workup was also negative. A diagnosis of locally advanced renal cell carcinoma (RCC) was made.

A modified chevron incision was used to enter the abdominal cavity. The kidney and anterior surface of IVC and aorta were exposed using a self-retaining retractor. Early ligation of right renal artery was the next step. We then mobilised contralateral RV and IVC to allow for vascular control above and below the level of thrombus. Minor hepatic vessel leaving from IVC to the caudate lobe was encountered and ligated. Following this step, vascular loops were applied sequentially over infrarenal IVC, contralateral RV and lastly on suprarenal IVC. No cardiopulmonary bypass was required.

The tumour was located at the lower and mid-pole of the right kidney with a diameter of about 8.0 cm. On manual palpation the tumour thrombus was palpable in RV and vena cava, and reached just below the hepatic margin. An intraoperative ultrasound was also performed which confirmed the extent of tumour from renal ostium to hepatic margin.

A longitudinal venotomy was done and then thrombus was dissected from the IVC and extracted quickly. Any remaining residual thrombus was checked. The vena cava cavorraphy was then performed with Prolene 4-0 vascular sutures with double continuous anastomosis technique. Air was also removed prior to closure of IVC by tilting the table in Trendelenburg position and first removing the infrarenal clamp. All perinephric fat and hilar lymph nodes were kept towards the renal side and dissected out with the specimen. The procedure was performed successfully.

A multidetector CT scan was repeated at 2 weeks in the postoperative period which did not reveal any residual tumour. A repeat ultrasound Doppler of bilateral lower limb extremities done at 2 weeks also did not reveal any deep vein thrombus and limb oedema had completely subsided by third week.

RCC is commonly associated with a venous thrombosis with up to 9%–14% of the patients having IVC thrombus at the time of the diagnosis.[1]

According to Neves and Zincke, the level of the IVC thrombus was classified as level I when it is limited to the RV, level II when it involves infrahepatic vena cava, level III when it involves retrohepatic IVC and level 4 when thrombus involves supradiaphragmatic IVC or right atrium.

Locally advanced RCC can have a myriad of presentation from haematuria to fatigue, weight loss to lower extremity oedema, ascites and pulmonary embolism.[2]

Our patient presented with lower limb oedema and haematuria. Although CT abdomen clearly demonstrated the renal carcinoma with tumour thrombus extending to IVC, for all cases of gross haematuria, a cystoscopy and urine cytology should be considered as it is the standard of care for evaluation of gross haematuria.

CT plays an important role in delineating the primary renal pathology and the extent of thrombus invasion into IVC. Because thrombus study requires enhancement phase, a multidetector CT has improved the sensitivity and specificity of CT in detecting RCC by improving accuracy of staging and enhancing surgical planning.[3 4]

MRI is however the gold standard for demonstrating level and extent of tumour invasion in IVC with a sensitivity close to 100%. Recent studies have however highlighted equal efficacy of both MRI and multidetector CT for evaluation of tumour thrombus.

In the postoperative period most authors advocate obtaining an MRI within 1–2 weeks to rule out any remaining thrombus owing to the aggressive nature of the disease.[3 4]

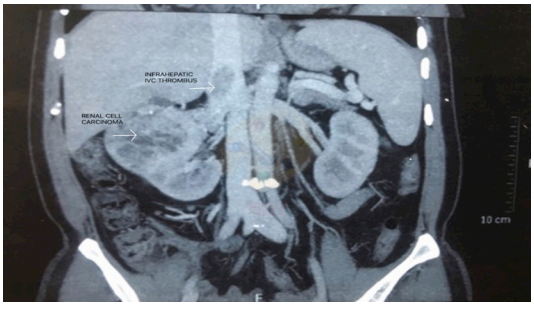

Figure 1 Right renal cell carcinoma involving upper and mid-pole with tumour thrombus extending into infrahepatic inferior vena cava (IVC).

Check for updates

© BMJ Publishing Group Limited . No commercial re-use. See rights and permissions. Published by BMJ.

To cite: Agarwal S, Yadav RN, Garg G, *et al*. *BMJ Case Rep* Published Online First: [*please include* Day Month Year]. doi:10.1136/bcr-2018-225465

BMJ Case Reports: first published as 10.1136/bcr-2018-225465 on 5 July 2018. Downloaded from http://casereports.bmj.com/ on 17 April 2024 by guest. Protected by copyright.

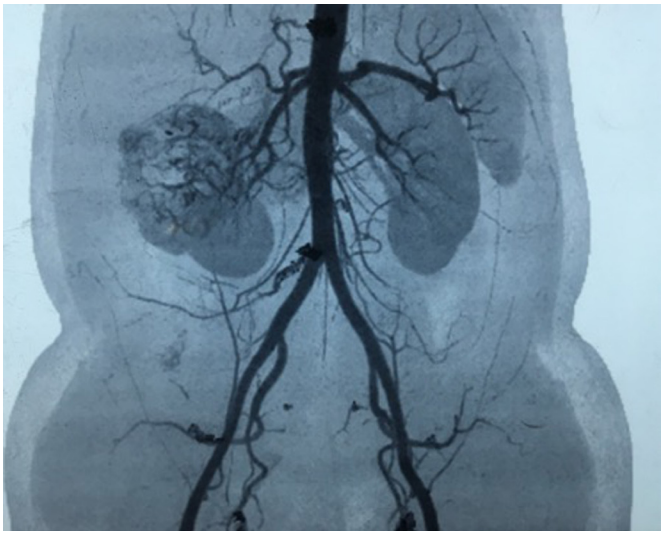

Figure 2 CT angiography showing right renal mass with feeding vasculature.

The purpose of both CT and MRI diagnostic modality includes characterising the extent of tumour into IVC, local extension of the renal tumour into the perirenal and adipose tissue which aids in staging. The metastatic involvement of the ipsilateral adrenal gland can also be evaluated. The presence and absence of retroperitoneal or intra-abdominal lymphadenopathy or occult metastases in other organs can also be shown clearly.[1]

Early ligation of renal artery is an important step in management of such patients. In their study of 82 patients, Ciancio *et al* proposed early ligation of renal artery as compared with preoperative embolisation of renal tumours and found it significantly reduced bleeding by collapsing many of the collaterals. They also proposed early control of renal artery by ligating it behind the RV.[5]

The level of the thrombus dictates the surgical approach which could include total nephrectomy, limited or extensive IVC dissection, or vascular or cardiopulmonary bypass.[6 7]

Learning points

- Renal cell carcinoma with inferior vena cava thrombus is fairly common.
- Multidetector CT or MRI is the cornerstone of diagnosis and staging.
- In most case series reported in literature, radical nephrectomy and inferior vena caval thrombectomy result in good oncologic outcomes in majority of such patients.

Contributors SA: concept, design, supervision, processing, writing manuscript and critical analysis. RNY: concept, design, supervision, processing and critical analysis. GG: processing, writing manuscript and critical analysis. MK: concept, supervision and writing manuscript.

Funding The authors have not declared a specific grant for this research from any funding agency in the public, commercial or not-for-profit sectors.

Competing interests None declared.

Patient consent Obtained.

Provenance and peer review Not commissioned; externally peer reviewed.

REFERENCES

1 Woodruff DY, Van Veldhuizen P, Muehlebach G, *et al*. The perioperative management of an inferior vena caval tumor thrombus in patients with renal cell carcinoma. *Urol Oncol* 2013;31:517–21.
2 Parekh DJ, Cookson MS, Chapman W, *et al*. Renal cell carcinoma with renal vein and inferior vena caval involvement: clinicopathological features, surgical techniques and outcomes. *J Urol* 2005;173:1897–902.
3 Constantinides C, Recker F, Bruehlmann W, *et al*. Accuracy of magnetic resonance imaging compared to computerized tomography and renal selective angiography in preoperatively staging renal cell carcinoma. *Urol Int* 1991;47:181–5.
4 Lawrentschuk N, Gani J, Riordan R, *et al*. Multidetector computed tomography vs magnetic resonance imaging for defining the upper limit of tumour thrombus in renal cell carcinoma: a study and review. *BJU Int* 2005;96:291–5.
5 Ciancio G, Vaidya A, Soloway M. Early ligation of the renal artery using the posterior approach: a basic surgical concept reinforced during resection of large hypervascular renal cell carcinoma with or without inferior vena cava thrombus. *BJU Int* 2003;92:488–9.
6 Suggs WD, Smith RB, Dodson TF, *et al*. Renal cell carcinoma with inferior vena caval involvement. *J Vasc Surg* 1991;14:413–8.
7 Neves RJ, Zincke H. Surgical treatment of renal cancer with vena cava extension. *Br J Urol* 1987;59:390–5.

Copyright 2018 BMJ Publishing Group. All rights reserved. For permission to reuse any of this content visit http://group.bmj.com/group/rights-licensing/permissions.
BMJ Case Report Fellows may re-use this article for personal use and teaching without any further permission.

Become a Fellow of BMJ Case Reports today and you can:
- Submit as many cases as you like
- Enjoy fast sympathetic peer review and rapid publication of accepted articles
- Access all the published articles
- Re-use any of the published material for personal use and teaching without further permission

For information on Institutional Fellowships contact consortiasales@bmjgroup.com

Visit casereports.bmj.com for more articles like this and to become a Fellow

BMJ Case Reports: first published as 10.1136/bcr-2018-225465 on 5 July 2018. Downloaded from http://casereports.bmj.com/ on 17 April 2024 by guest. Protected by copyright.