# Crescent sign in abdominal aortic aneurysm

Pooya Iranpour, Sara Haseli

Radiology Department, Shiraz University of Medical Sciences, Shiraz, Iran

**Correspondence to**
Dr Pooya Iranpour, pooya.iranpour@gmail.com

Accepted 18 May 2018

## DESCRIPTION

A 70-year-old man referred to emergency department with acute onset of severe flank pain. In initial examinations, the patient was pale, with pulse rate of 120/min and blood pressure of 95/65. In abdominal palpation a pulsatile mass was detectable. Urgent resuscitation was done.

The patient had been known to have hypertension and abdominal aortic aneurysm (AAA) since 7 years ago. Abdominal CT scan without and with contrast injection (figures 1 and 2) showed a large fusiform abdominal aorta with crescentic focus of hyperdensity (black arrow) within the mural thrombus (white arrow), known as high-attenuating crescent sign. Retroperitoneal haematoma was also observed anterior to psoas muscles bilaterally (asterisks). Endovascular repair was chosen as an emergent surgical procedure. The patient was discharged on postoperative day 7, and recovery was uneventful.

High-attenuating crescent sign is intramural or mural thrombus haemorrhage of an abdominal aneurysm and means impending or acute aortic aneurysm rupture.[1]

AAA rupture has high mortality rate even with emergent surgical repair; so prompt correct diagnosis is necessary for proper management. There are several predictive factors in AAA rupture, such as large size of the aneurysm, rapid increase in diameter, focal wall discontinuity and crescent sign. Crescent sign—an indicator of AAA complication and impending rupture—has high specificity and positive predictive value of 77% and 93%, respectively.[2]

The pathophysiology of this sign is dissecting blood through mural thrombosis or wall of the aneurysm resulting in weakening of the wall. It is of relatively high density compared with psoas muscle in contrast-enhanced CT scan and is greater than aorta in non-contrast CT images.[3]

**Figure 1** Non-contrast enhanced abdominal CT scan shows an abdominal aorta aneurysm with mural thrombosis (white arrow) and crescent sign (black arrow).

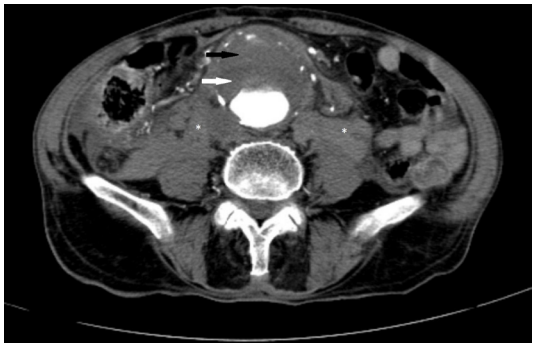

**Figure 2** After injection of contrast patent lumen of the aneurysm is opacified. Hyperdense crescent sign is visible as rim of increased density (black arrow) within the mural thrombus (white arrow), relatively hyperdense compared with psoas muscles. Retroperitoneal haematoma is visible anterior to psoas muscles (asterisk).

### Learning points

- Hyperdense crescent sign is due to haemorrhage into the wall of aneurysm or within the mural thrombosis.
- Hyperdense crescent sign indicates impending aneurysm rupture.

**Contributors** PI has planned the work and provided the case and critically reviewed the article. SH has performed the literature review and has written the article.

**Funding** The authors have not declared a specific grant for this research from any funding agency in the public, commercial or not-for-profit sectors.

**Competing interests** None declared.

**Patient consent** Next of kin consent obtained.

**Provenance and peer review** Not commissioned; externally peer reviewed.



## REFERENCES

1 Gonsalves CF. The hyperattenuating crescent sign. *Radiology* 1999;211:37–8.
2 Vu KN, Kaitoukov Y, Morin-Roy F, *et al*. Rupture signs on computed tomography, treatment, and outcome of abdominal aortic aneurysms. *Insights Imaging* 2014;5:281–93.
3 Mehard WB, Heiken JP, Sicard GA. High-attenuating crescent in abdominal aortic aneurysm wall at CT: a sign of acute or impending rupture. *Radiology* 1994;192:359–62.



**To cite:** Iranpour P, Haseli S. *BMJ Case Rep* Published Online First: [*please include* Day Month Year]. doi:10.1136/bcr-2018-225435