

Emphysematous gastritis secondary to *Sarcina ventriculi*

Matthew Alvin,¹ Nour Al Jalbout²

¹Radiology, Johns Hopkins Hospital, Baltimore, Maryland, USA

²Emergency Medicine, Johns Hopkins Hospital, Baltimore, Maryland, USA

Correspondence to
Dr Matthew Alvin,
malvin2@jhmi.edu

Accepted 26 January 2018

DESCRIPTION

An 87-year-old man with history of dementia, coronary artery disease on dual antiplatelet therapy and oesophagitis presented to the emergency department with acute-onset coffee ground emesis and left upper quadrant abdominal pain of 1-day duration. Vital signs were normal. Exam was notable for diffuse abdominal pain without peritoneal signs.

Medical work-up was remarkable for haemoglobin of 8.2 g/dL, lactate of 6.3 mmol/L and white blood cell count of $21.84 \times 10^9/L$. CT with angiography of the abdomen and pelvis revealed extensive portal and mesenteric venous gas as well

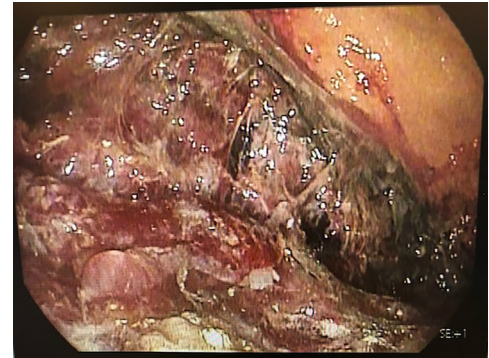


Figure 3 Upper endoscopy image of the stomach demonstrates diffuse inflammation and necrosis.

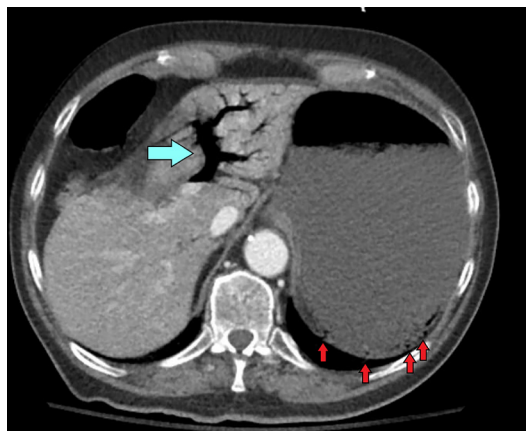


Figure 1 Axial CT image of the upper abdomen with intravenous contrast demonstrates extensive portal venous gas (blue arrow). Multiple locules of gas (red arrows) are present in the wall of the stomach.

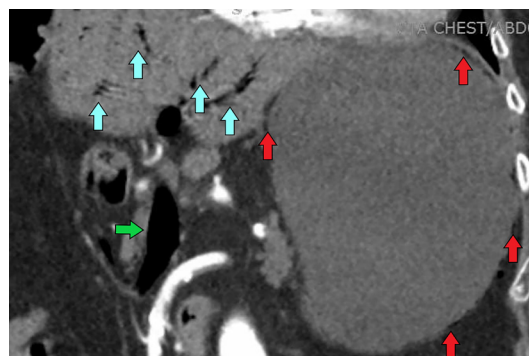


Figure 2 Coronal CT of the upper abdomen with intravenous contrast demonstrates extensive portal venous gas (blue arrows). Gas is also present in the superior mesenteric vein (green arrow). Multiple locules of gas (red arrows) are present in the wall of the stomach.

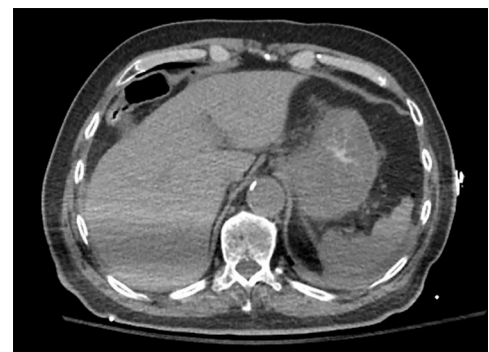
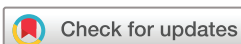
Figure 4 Axial CT image of the upper abdomen without intravenous contrast at 24 hours post-treatment with antibiotics demonstrates resolution of portal venous gas. The stomach wall is diffusely thickened with resolution of air in the wall.

as gastric emphysema (figures 1 and 2). The bowel was normal.

Exploratory laparotomy was performed to evaluate for bowel ischaemia. It demonstrated normal bowel, while upper endoscopy demonstrated diffuse severe erosive and necrotic gastritis (figure 3), consistent with emphysematous gastritis. In addition to fluids and a proton pump inhibitor, antibiotics were initiated for suspected infectious aetiology. Blood cultures were negative. Gastric biopsy findings were consistent with acute phlegmonous gastritis secondary to *Sarcina ventriculi*, a rare organism implicated in severe gastric pathology, with predisposition towards patients with delayed gastric emptying (not in our patient though). Within 24 hours, repeat non-contrast CT of the abdomen and pelvis demonstrated resolution of portal venous gas and gastric emphysema



To cite: Alvin M, Al Jalbout N. *BMJ Case Rep* Published Online First: [please include Day Month Year]. doi:10.1136/bcr-2018-224233

Learning points

- ▶ Emphysematous gastritis is a life-threatening form of gastric emphysema.
- ▶ Diagnosis is based on a combination of imaging, clinical and endoscopic findings.
- ▶ Urgent identification and initiation of antibiotics are essential, although mortality rates remain high despite treatment.

(figure 4), with resolution of patient symptoms. A repeat endoscopy 5 days later revealed resolution of necrosis without ulceration.

Emphysematous gastritis is a rare, life-threatening form of gastric emphysema due to gas-forming bacteria, where clinical presentation in combination with imaging is crucial for accurate diagnosis.¹⁻³ Notably, gastric emphysema is a benign finding and may look identical on imaging. Essential diagnostic features of emphysematous gastritis include severe abdominal pain, haematemesis and high lactate, whereas patients are generally asymptomatic with gastric

emphysema. Early recognition is important to allow for immediate initiation of broad-spectrum antibiotics and fluid support.² Surgery is indicated if gastric infarction is suspected via endoscopy.¹

Contributors NAJ provided both the initial diagnosis and care of the patient, respectively. MA wrote the initial manuscript, which was subsequently reviewed and edited by NAJ.

Competing interests None declared.

Patient consent Obtained.

Provenance and peer review Not commissioned; externally peer reviewed.

© BMJ Publishing Group Ltd (unless otherwise stated in the text of the article) 2018. All rights reserved. No commercial use is permitted unless otherwise expressly granted.

REFERENCES

- 1 Al-Jundi W, Shebl A. Emphysematous gastritis: case report and literature review. *Int J Surg* 2008;6:e63–6.
- 2 Rountree KM, Lopez PP. Emphysematous gastritis, a spectrum of disease: a four-case report. *Am Surg* 2017;83:285–7.
- 3 Murnan SD, Miller J, Kuhn A. Gastric emphysema: a cannot-miss emergency medicine diagnosis. *Pediatr Emerg Care* 2017;10.1097/PEC.0000000000001202. [Epub ahead of print 14 Jun 2017].

Copyright 2018 BMJ Publishing Group. All rights reserved. For permission to reuse any of this content visit <http://group.bmj.com/group/rights-licensing/permissions>.
BMJ Case Report Fellows may re-use this article for personal use and teaching without any further permission.

Become a Fellow of BMJ Case Reports today and you can:

- ▶ Submit as many cases as you like
- ▶ Enjoy fast sympathetic peer review and rapid publication of accepted articles
- ▶ Access all the published articles
- ▶ Re-use any of the published material for personal use and teaching without further permission

For information on Institutional Fellowships contact consortiasales@bmjgroup.com

Visit casereports.bmj.com for more articles like this and to become a Fellow