

# 'Toxic' ST elevation

Amal Paul,<sup>1</sup> Anandaroop Lahiri<sup>2</sup>

<sup>1</sup>Department of Cardiology, Christain Medical College and Hospital, Vellore, Tamil Nadu, India

<sup>2</sup>Department of Cardiac Electrophysiology and Pacing, Christian Medical College and Hospital, Vellore, Tamil Nadu, India

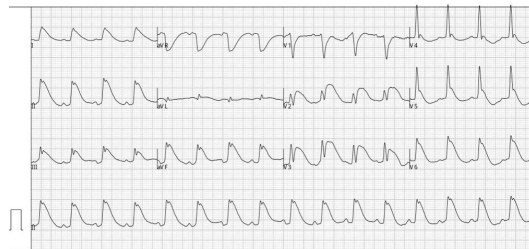
## Correspondence to

Dr Anandaroop Lahiri, anandaroop\_lahiri@yahoo.com

Accepted 13 July 2017

## DESCRIPTION

A young man was admitted to the emergency department after consuming zinc phosphide, with severe drug refractory hypotension. ECG (refer [figure 1](#)) revealed ST segment elevation involving anterior, lateral and inferior leads. Serum levels of potassium, calcium, magnesium and phosphorous were normal; serum troponin-T



**Figure 1** ST segment elevation involving anterior, lateral and inferior leads.

was 1126 ng/nL (upper limit of normal 14 ng/nL), with associated metabolic acidosis. Echocardiogram revealed severe left ventricular systolic dysfunction. Severe myocardial depression with histopathological evidence of myocyte vacuolation and myocytolysis has been occasionally described with aluminium phosphide toxicity, primarily mediated by phosphine. The absence of an antidote makes the mortality high, once refractory shock ensues. Our patient succumbed to this condition. Zinc phosphide toxicity mediated by phosphine can have similar multisystem involvement, though dramatic electrocardiographic changes are uncommon.<sup>1,2</sup> However, as evidenced by our report, ST segment elevation involving multiple leads on the ECG, though rare, maybe a hazardous manifestation of zinc phosphide poisoning leading to a fulminant course.

**Contributors** AP: involved in the management of the patient and collection of data with regard to the patient. AL: involved in the preparation of the manuscript and editing of the image.

**Competing interests** None declared.

**Patient consent** Not required.

**Provenance and peer review** Not commissioned; externally peer reviewed.

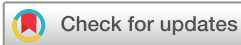© BMJ Publishing Group Ltd (unless otherwise stated in the text of the article) 2018. All rights reserved. No commercial use is permitted unless otherwise expressly granted.

## REFERENCES

- 1 Proudfoot AT. Aluminium and zinc phosphide poisoning. *Clin Toxicol* 2009;47:89–100.
- 2 Trakulsrichai S, Kosanyawat N, Atiksawedparit P, et al. Clinical characteristics of zinc phosphide poisoning in Thailand. *Ther Clin Risk Manag* 2017;13:335–40.

## Learning points

- ▶ Toxins are an important cause of ST segment elevation that need to be suspected in the emergency department. Phosphide overdose is a significant cause of cardiotoxicity, mediated by phosphine.
- ▶ ST segment elevation occurring in multiple territories is unlikely to be due to an acute coronary syndrome. Such situations demand the consideration of other causes of ST segment elevation.



**To cite:** Paul A, Lahiri A. *BMJ Case Rep* Published Online First: [please include Day Month Year]. doi:10.1136/bcr-2017-221457

Copyright 2018 BMJ Publishing Group. All rights reserved. For permission to reuse any of this content visit <http://group.bmj.com/group/rights-licensing/permissions>.

BMJ Case Report Fellows may re-use this article for personal use and teaching without any further permission.

Become a Fellow of BMJ Case Reports today and you can:

- ▶ Submit as many cases as you like
- ▶ Enjoy fast sympathetic peer review and rapid publication of accepted articles
- ▶ Access all the published articles
- ▶ Re-use any of the published material for personal use and teaching without further permission

For information on Institutional Fellowships contact [consortiasales@bmjgroup.com](mailto:consortiasales@bmjgroup.com)

Visit [casereports.bmj.com](http://casereports.bmj.com) for more articles like this and to become a Fellow