Primary pericardial mesothelioma and asbestos exposure: a rare fatal disease

Diana Maria Monteiro Freitas,[1] Raquel L Ramos,[2] Luísa Serpa Pinto,[3] Rosa Ribeiro[4]

[1]Internal Medicine, Hospital Geral de Santo Antonio SA, Porto, Portugal
[2]Internal Medicine, Hospital Geral de Santo Antonio SA, Porto, Portugal
[3]Internal Medicine, Hospital Geral de Santo Antonio SA, Porto, Portugal
[4]Internal Medicine, Hospital Geral de Santo Antonio SA, Porto, Portugal

Correspondence to
Dr Diana Maria Monteiro Freitas,
di.monteiro.freitas@gmail.com

Accepted 23 March 2017

DESCRIPTION

A 73-year-old woman without a history of cardiovascular disease was admitted to the hospital with progressive dyspnoea on exertion during the past several weeks, bilateral lower extremity oedema, orthopnoea and paroxistic nocturnal dyspnoea. She lived a few metres away from a badly preserved building containing asbestos for 50 years. Estimated jugular venous pressure was 6+5 cm H_2O, a pericardial friction rub was heard, bilateral basal lung crackles were present and symmetrical below-knee pitting oedema was seen. Probrain natriuretic peptide was 2304 pg/mL, and chest radiograph showed a globular cardiac silhouette and blunting of the costophrenic angles due to a small transudative pleural effusion containing benign mesothelial cells on cytological analysis. Transthoracic echocardiogram showed a large pericardial effusion with diastolic collapse of the right ventricle and a hypotransparent mass (4×1.6 cm) attached to the visceral pericardium in the right apex (video 1). Therapeutic pericardiocentesis was performed and cytological analysis of pericardial fluid demonstrated malignant cells of inconclusive origin. CT scan of the chest, abdomen and pelvis, mammography and upper and lower gastrointestinal endoscopies showed no evidence of extracardiac disease. A primary cardiac tumour was assumed and positron emission tomography-CT was done, as a part of the staging workup, demonstrating isolated hyperfixation in the apex and right atrium.

Four days after hospital admission, recurrent pericardial effusion was documented and pericardiectomy was undertaken. A primary pericardial malignant mesothelioma was diagnosed based on histological examination.

The patient was treated with carboplatin and pemetrexed experiencing disease progression and died 1 year after diagnosis.

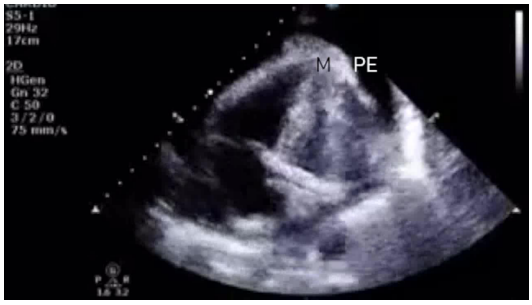

Video 1 Transthoracic echocardiogram showing a large circumferential pericardial effusion (PE) with right ventricular diastolic collapse and a hypotransparent mass (M) attached to the visceral pericardium in the right apex.

Learning points

- Primary pericardial malignant mesothelioma (PPMM) is an extremely rare tumour, with an incidence <0.002%. Besides, its insidious nature and the absence of specific clinical manifestation result in PPMM being often misdiagnosed as other forms of pericardial disease, and antemortem diagnosis is infrequent.[1]
- Due to the absence of a premalignant lesion, late presentation and few treatment approaches, PPMM carries a poor prognosis and its outcome is uniformly fatal, with a mean survival time of 6–10 months from diagnosis.[2]
- Risk factors include simian virus 40 infection, radiation exposure, thorotrast, tuberculosis and exposure to non-asbestos materials such as erionite.[2] We emphasise the exposure to asbestos in this case, an association that remains controversial in the literature and that has rarely been reported in the absence of concomitant pleural disease.[3]

Contributors All authors contributed substantially to the conception of this manuscript. DMMF and RLR were responsible for reporting the case. DMMF, RLR and LSP wrote the learning points and performed the bibliographic research. DMMF had full responsibility for the final work.

Competing interests None declared.

Patient consent Obtained from next of kin.

Provenance and peer review Not commissioned; externally peer reviewed.

© BMJ Publishing Group Ltd (unless otherwise stated in the text of the article) 2017. All rights reserved. No commercial use is permitted unless otherwise expressly granted.

REFERENCES

1 Lee MJ, Kim DH, Kwan J, *et al*. A case of malignant pericardial mesothelioma with constrictive pericarditis physiology misdiagnosed as pericardial metastatic cancer. *Korean Circ J* 2011;41:338–41.
2 Fernandes R, Nosib S, Thomson D, *et al*. A rare cause of heart failure with preserved ejection fraction: primary pericardial mesothelioma masquerading as pericardial constriction. *BMJ Case Rep* 2014;2014:bcr2013203194.
3 Suman S. Primary pericardial mesothelioma presenting as pericardial constriction: a case report. *Heart* 2004;90:4e–4.

To cite: Freitas DMM, Ramos RL, Serpa Pinto L, *et al*. *BMJ Case Rep* Published Online First: [*please include* Day Month Year]. doi:10.1136/bcr-2017-219949

BMJ Case Reports: first published as 10.1136/bcr-2017-219949 on 12 May 2017. Downloaded from http://casereports.bmj.com/ on 17 April 2024 by guest. Protected by copyright.

Copyright 2017 BMJ Publishing Group. All rights reserved. For permission to reuse any of this content visit
http://group.bmj.com/group/rights-licensing/permissions.
BMJ Case Report Fellows may re-use this article for personal use and teaching without any further permission.

Become a Fellow of BMJ Case Reports today and you can:
- Submit as many cases as you like
- Enjoy fast sympathetic peer review and rapid publication of accepted articles
- Access all the published articles
- Re-use any of the published material for personal use and teaching without further permission

For information on Institutional Fellowships contact consortiasales@bmjgroup.com

Visit casereports.bmj.com for more articles like this and to become a Fellow

BMJ Case Reports: first published as 10.1136/bcr-2017-219949 on 12 May 2017. Downloaded from http://casereports.bmj.com/ on 17 April 2024 by guest. Protected by copyright.