



OPEN ACCESS

CASE REPORT

Ureteral inguinal hernia: an uncommon trap for general surgeons

Zarif Yahya,¹ Yahya Al-habbal,¹ Sayed Hassen²

¹Department of General Surgery, Eastern Health, Box Hill, Victoria, Australia

²Department of Hepatobiliary, Upper GI and General Surgery, Eastern Health, Box Hill, Victoria, Australia

Correspondence to
Dr Zarif Yahya, zarify@gmail.com

Accepted 19 February 2017

SUMMARY

Inguinal hernias involving the ureter, a retroperitoneal structure, is an uncommon phenomenon. It can occur with or without obstructive uropathy, the latter posing a trap for the unassuming general surgeon performing a routine inguinal hernia repair. Ureteral inguinal hernia should be included as a differential when a clinical inguinal hernia is diagnosed concurrently with unexplained hydronephrosis, renal failure or urinary tract infection particularly in a male. The present case describes a patient with a known ureteroinguinal hernia who proceeded to having a planned hernia repair and ureteric protection. The case is a reminder that when faced with an unexpected finding such an indirect sliding inguinal hernia, extreme care should be taken to ensure that no structures are inadvertently damaged and that a rare possibility is the entrapment of the ureter in the inguinal canal.

BACKGROUND

Ureteral hernias were first described in 1880 and <140 cases have been reported in the literature,¹ with even fewer described with incarceration and ureteric obstruction.² Majority of these cases are associated with inguinal hernias and incarceration is relatively uncommon due to the large size of the inguinal hernia.³

Ureteral inguinal hernias are more common in men, typically in the fifth and sixth decades of life. Many cases occur in patients with a history of kidney transplantation given the anterior location of the transplanted ureter within the space of Retzius. Ureteral inguinal hernias also occur more commonly on the right side than the left side. This is because on the left, the fascia of Toldt sits at the level of the secondary root of the sigmoid mesocolon which appears to tighten and fix the ureter in the retroperitoneum.^{4 5}

Ureteral inguinal hernias are predominantly indirect rather than direct (80% vs 20%), and can occur in two anatomical variants. A paraperitoneal type, where the ureter slides beside a peritoneal sac and constitutes part of the hernia wall, occurs in 80% of cases. Less commonly an extraperitoneal type occurs (20%), where the ureter is accompanied only by retroperitoneal fat and no peritoneal sac is present.⁵ Bladder involvement is very rare as it is associated with direct hernia and usually presents with symptoms of bladder outlet obstruction such as urinary retention, frequency and haematuria.

A ureteral inguinal hernia often goes undiagnosed until surgical repair is performed, where the

ureter is inadvertently injured. This highlights the importance of preoperative assessment. A CT urogram can be used to identify this phenomenon; however, it is difficult to justify these tests in every patient who presents with a groin lump and can be considered as a first line of investigation for a patient with unexplained renal failure or unilateral hydronephrosis on ultrasound scan (USS).

Ureteroinguinal hernias are treated surgically due to the risk of obstructive uropathy. An open hernia repair with simple reduction of the ureter may be sufficient, or in more complex cases resection of redundant ureter followed by primary anastomosis or ureteroneocystostomy. In the latter, post-operative imaging with USS or CT should be done to ensure patency and proper replacement of the ureter.^{6 7} Laparoscopic repair has no role in ureteroinguinal hernias and has only been described in the management of urinary bladder hernias.⁸

The present case confirms the importance of preoperative assessment and diagnosis of ureteral inguinal hernias. It also highlights that this phenomenon can be missed in the routine preoperative assessment for an elective routine day case repair of an inguinal hernia. In such case, an awareness of the condition, a high index of suspicion and careful tissue dissection is essential.

CASE PRESENTATION

An 81-year-old man from nursing home care presents with multiple facial lacerations after a mechanical fall requiring plastic surgery. He was admitted under a general medical unit due to comorbidities which includes congestive cardiac failure, rheumatoid arthritis, bilateral hip replacement, benign prostatic hypertrophy and chronic alcoholism. He had known bilateral inguinal hernias containing fat of which the right side has been mildly symptomatic.

INVESTIGATIONS

He was found to have an *Escherichia coli* urinary tract infection which was treated with oral antibiotics. An outpatient genitourinary USS 3 months prior to his admission had shown a non-obstructing renal stone in the right proximal ureter. A CT urogram was performed which showed bilateral small renal and ureteric stones. In particular, within the distal right ureter 5 cm from the vesicoureteric junction there was a 5 mm calculus. The ureter proximal to the calculus was mildly dilated though tapered distally, and was looped within a right-sided indirect inguinal hernia (figures 1 and 2).



CrossMark

To cite: Yahya Z, Al-habbal Y, Hassen S. *BMJ Case Rep* Published online: [please include Day Month Year] doi:10.1136/bcr-2017-219288

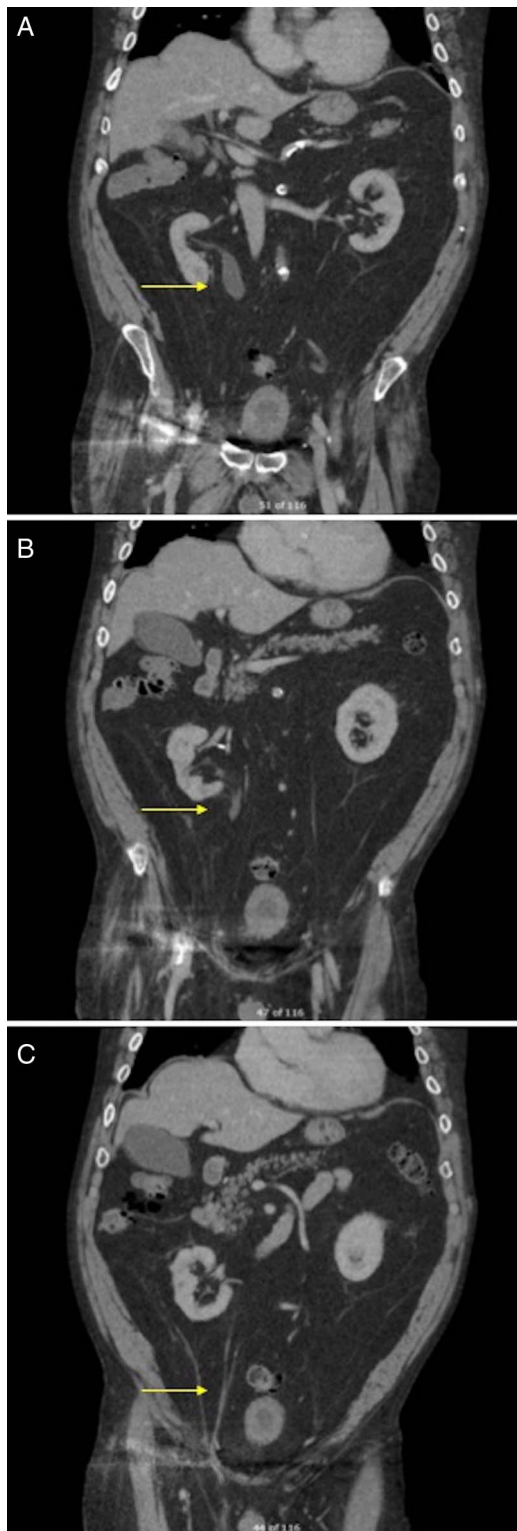

Figure 1 Computed Tomography (CT) intravenous pyelogram showing a partially dilated right ureter extending down towards a right inguinal hernia (arrow).

DIFFERENTIAL DIAGNOSIS

- ▶ Indirect inguinal hernia with bowel, omentum or extraperitoneal fat
- ▶ Femoral hernia
- ▶ Hydrocele or varicocele
- ▶ Ureteric, bladder or prostate malignancy
- ▶ Pelvic or retroperitoneal malignancy

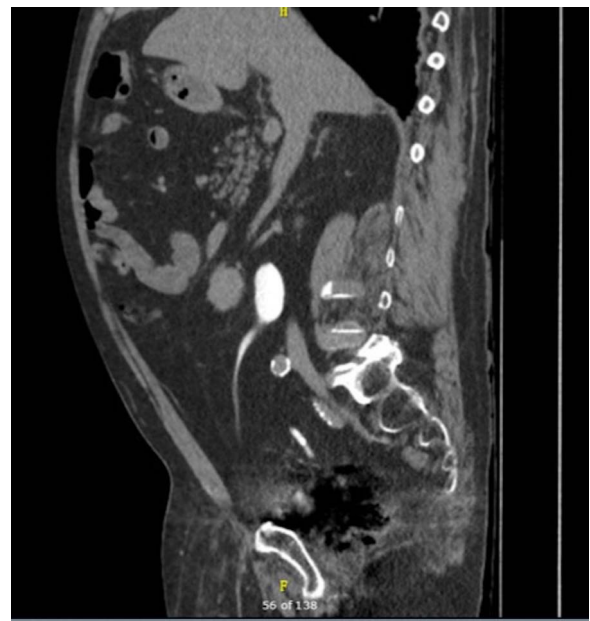

Figure 2 Sagittal view of CT intravenous pyelogram showing dilated proximal right ureter extending down to inguinal canal (arrow). Note that retroperitoneal structures, including the pancreas (A), are sitting forward and extending down into hernia sac (B).

TREATMENT

They proceeded to having a cystoureteroscopy and stent insertion was performed by a urologist who was unable to retrieve the calculus. This was due to the looping nature of the distal right ureter within a sliding irreducible inguinal hernia. Intraoperative retrograde pyelogram showed a 'fish hook' appearance of the distal ureter (figure 3).

The patient was referred to the general surgical unit and after a preoperative assessment he proceeded to having an elective open right inguinal hernia repair with mesh (Lichtenstein repair). Intraoperatively, a sliding indirect hernia was identified containing fat which was initially thought to be a large lipoma of the cord. Careful dissection of the fatty tissue eventually revealed a deeper component with a large broad base extending from the internal ring. The surgical team concluded that this was actually retroperitoneal fat which was further dissected, exposed and suture-ligated before excision. The right ureter, with a palpable stent in situ, was easily identified and preserved throughout. The inguinal canal was short with a weak posterior wall and there was no appreciable sac, nor any intraperitoneal structures found.

OUTCOME AND FOLLOW-UP

The patient recovered from his hernia repair with no complications. He was subsequently recalled for his second cystoureteroscopy where his distal ureteric calculus was successfully extracted and a new stent was inserted as a precaution in view of removal in 6-week time. He recovered from his urinary tract infection and continues to see the urologists as an outpatient.

Review of the patient's medical records revealed he had been seen by two general surgeons in the past 3 years for his bilateral inguinal hernias and was deemed not fit for surgery due to his comorbidities. Only his right inguinal hernia was mildly symptomatic at the time and it was agreed that the risks associated with surgery outweighed the benefits. With the ureteric obstruction, his hernia repair was a necessity rather than a luxury.

Figure 3 Intraoperative retrograde pyelogram showing the right ureter (A) before and (B) after inguinal hernia repair. Note the position of the ureter in relation to the prosthesis in (A) as it extends below the right superior pubic rami.

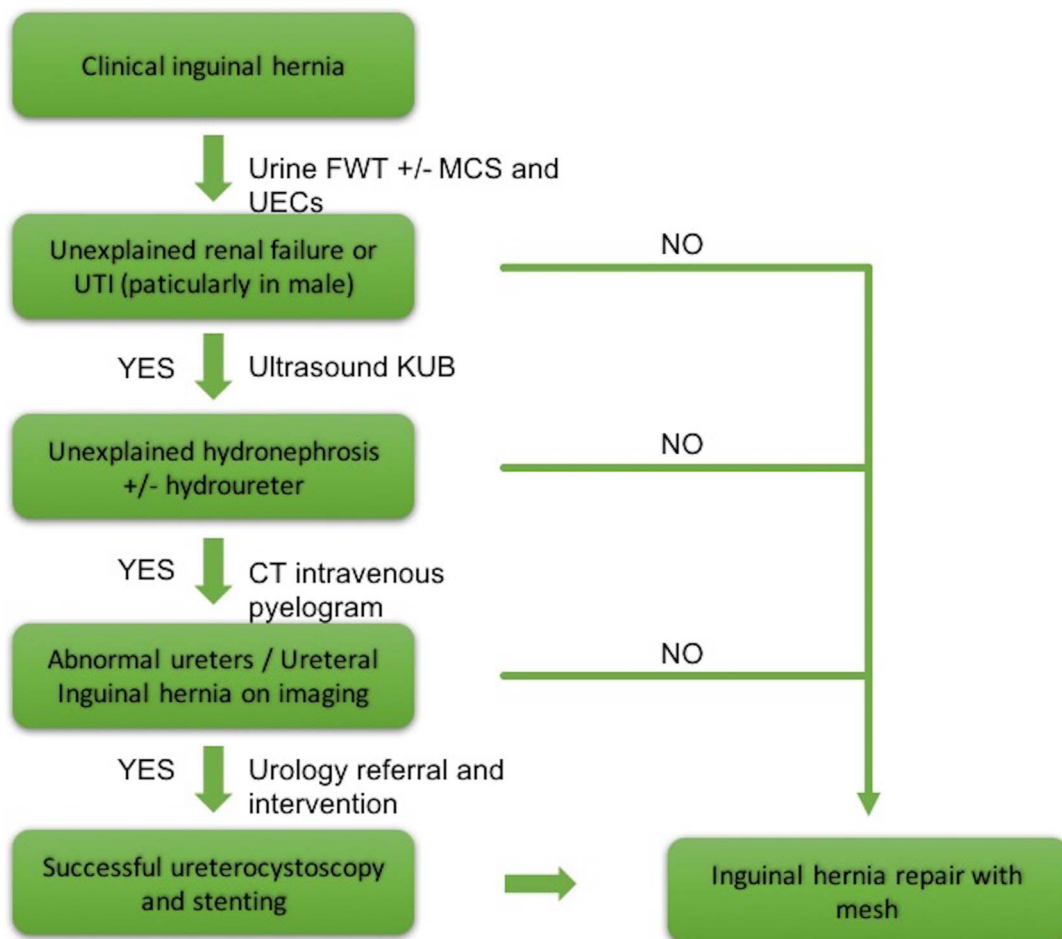
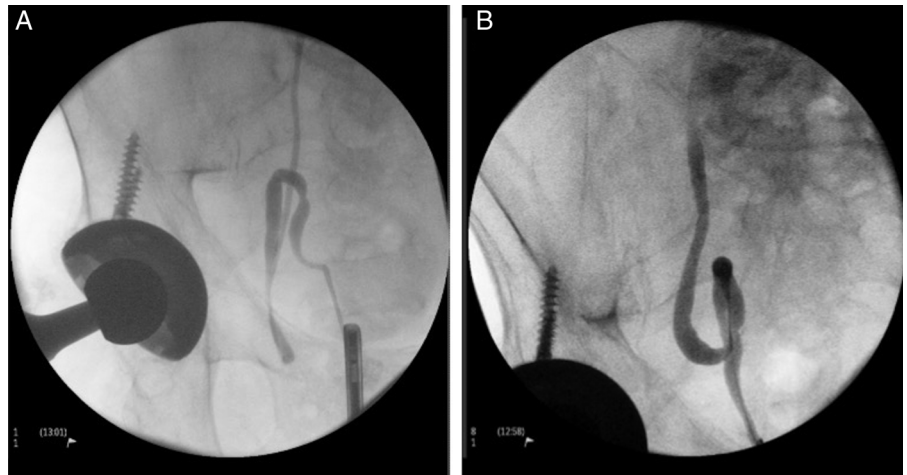


Figure 4 Algorithm for suspected ureteral involvement in the symptomatic inguinal hernia.

operation. One can only speculate what would happen if this patient had proceeded to his hernia repair without identifying radiologically the contents of his inguinal hernia prior to surgery.

DISCUSSION

Inguinal hernias have been described to contain wide range of intraperitoneal structures such as small bowel, large bowel, the

appendix (Amyand's hernia), a Meckel's diverticulum (Littre's hernia), omentum and bladder (especially in direct hernia). Protrusion of these retroperitoneal structures (or part of them) through the inguinal canal is defined as a sliding hernia. Herniation of the kidney and ureter, whole or partial, can happen in patients with renal transplant.⁹ This condition is out of the scope of this paper.

Ureter-containing inguinal hernias can be of two types: para-peritoneal and extraperitoneal. In the paraperitoneal type, a

loop of ureter is extended alongside a peritoneal sac. The herniated ureter is adherent to the posterior peritoneum, both of which are present in the hernia. It is a sliding type of hernia that is thought to be due to traction of underlying structures or adhesions that attach the ureter to the posterior peritoneum. Paraperitoneal type of ureteral hernia is believed to be acquired. Herniated bowel may also be present. It has been noted that the ureteral loop is located medial to the peritoneal sac, and when the ureter is extended into the scrotum it is more likely to be obstructed.⁹ In contrast to the paraperitoneal type of ureteral hernia, the extraperitoneal type is thought to be due to a congenital embryonic defect that results in fusion between the ureter and the genitoinguinal ligaments. It is theorised to be the result of failure of separation of the ureteric bud from the Wolffian duct, both of which are then drawn down to the scrotum to form the epididymis and vas deferens.^{9 10} In a case reported by McKay *et al*,¹ the patient needed to squeeze his scrotum to initiate micturition.

There have been multiple case reports and case series quoted in the literature.¹ Obesity and anterior displacement of the ipsilateral ureter from psoas muscle at L4 level seem to be among risk factors.¹¹ Scarring from previous hernia repair has also been raised as another possible risk factor.¹² Diagnosis can be made preoperatively or intraoperatively. Ipsilateral hydronephrosis with inguinal hernia should alert the clinician to the presence of ureter in the hernia. This would warrant a CT urography.⁹

A ureteral inguinal hernia often does not lead to strangulation and obstructive uropathy due to the large size of majority of these inguinal hernias.³ The condition is often diagnosed incidentally, either during or after herniorrhaphy, when the ureter is inadvertently injured. In the case described, ureteral involvement was successfully identified during investigation for a urinary tract infection during a completely unrelated hospital admission. It is believed that the infection was a result of renal stones, a common and often asymptomatic condition; however, in the presence of abnormal anatomy, calculi had become obstructed in the mid ureter. With a low likelihood of passing the calculus spontaneously, appropriate intervention was initiated by the urology unit.

Not many patients, nor surgeons for that matter, are fortunate enough to have diagnosed a ureteral inguinal hernia before surgery is performed. If the diagnosis is made preoperatively, we suggest stenting the ureter preoperatively to facilitate identifying, reducing and preserving the ureter. This was the case with our patient.

However, the same approach as described above can be adopted in difficult cases where there is some ambiguity. We suggest an algorithm to identify such hernias to avoid the caveat of ureteric injury (figure 4). In an open inguinoscrotal hernia repair, if the hernia contains fat that does not meet the characteristics of a cord lipoma and lacks the presence of the classical peritoneal sac, the possibility of herniating retroperitoneal structures, particularly the ureter, should be raised. In this situation, careful reduction of the fat should be performed. If the fat is completely irreducible, careful dissection at the level of the deep ring should be sought to avoid damaging a ureter.

Learning points

- ▶ A ureteral inguinal hernia should be considered when a clinical inguinal hernia is diagnosed concurrently with unexplained unilateral hydronephrosis, renal failure or urinary tract infection.
- ▶ Preoperative assessment should be performed on all patients having inguinal hernia repair, with minimum investigations being a urine full ward test and basic blood tests to assess renal function.
- ▶ Majority of cases occur in the absence of ureteral obstruction, hence it may be near impossible to make the diagnosis preoperatively.
- ▶ In such cases, an awareness of the condition, a high index of suspicion and careful surgical dissection is of utmost importance. These principles and techniques may avoid inadvertent injury to the ureter and avoid significant patient morbidity.

Acknowledgements Department of General Surgery, Box Hill Hospital Eastern Health, Victoria, Australia.

Contributors As corresponding author, ZY was responsible for conception and design of the case report as well as collection and interpretation of relevant patient data. Both ZY and YA performed a literature review. ZY and YA drafted and critically revised the article for accuracy and appropriateness of intellectual content. As the Director of General Surgery, SH provided valuable insights, guidance and direction in drafting the article. SH also proof-read the article and along with ZA and YA gave approval for the final manuscript to be submitted.

Competing interests None declared.

Patient consent Obtained.

Provenance and peer review Not commissioned; externally peer reviewed.

Open Access This is an Open Access article distributed in accordance with the Creative Commons Attribution Non Commercial (CC BY-NC 4.0) license, which permits others to distribute, remix, adapt, build upon this work non-commercially, and license their derivative works on different terms, provided the original work is properly cited and the use is non-commercial. See: <http://creativecommons.org/licenses/by-nc/4.0/>

REFERENCES

- 1 McKay JP, Organ M, Gallant C, *et al*. Inguinoscrotal hernias involving urologic organs: a case series. *Can Urol Assoc J* 2014;8:E429–32.
- 2 Ballard JL, Dobbs RM, Malone JM. Ureteroinguinal hernia: a rare companion of sliding inguinal hernias. *Am Surg* 1991;57:720–2.
- 3 Eilber KS, Freedland SJ, Rajfer J. Obstructive uropathy secondary to ureteroinguinal herniation. *Rev Urol* 2001;3:207–8.
- 4 Sanchez AS, Tebar JC, Martin MS, *et al*. Obstructive uropathy secondary to ureteral herniation in a pediatric en bloc renal graft. *Am J Transplant* 2005;5:2074–7.
- 5 Giuly J, François, GF, Giuly D, *et al*. Intrascrotal hernia of the ureter and fatty hernia. *Hernia* 2003;7:47–9.
- 6 Mantle M, Kingsnorth AN. An unusual cause of back pain in an achondroplastic man. *Hernia* 2003;7:95–6.
- 7 Giglio M, Medica M, Germinale F, *et al*. Scrotal extraperitoneal hernia of the ureter: case report and literature review. *Urol Int* 2001;66:166–8.
- 8 Khan A, Beckley I, Dobbins B, *et al*. Laparoscopic repair of massive inguinal hernia containing the urinary bladder. *Urol Annal* 2014;6:159.
- 9 Lu A, Burstein J. Paraperitoneal inguinal hernia of ureter. *J Radiol Case Rep* 2012;6:22–6.
- 10 Odisho AY, Freise CE, Tomlanovich SJ, *et al*. Inguinal herniation of a transplant ureter. *Kidney Int* 2010;78:115.
- 11 Allam ES, Johnson DY, Grewal SG, *et al*. Inguinoscrotal herniation of the ureter: Description of five cases. *Int J Surg Case Rep* 2015;14:160–3.
- 12 Golgor E, Stroszczyński C, Froehner M. Extraperitoneal inguinoscrotal herniation of the ureter: a rare case of recurrence after hernia repair. *Urol Int* 2009;83:113–15.

Copyright 2017 BMJ Publishing Group. All rights reserved. For permission to reuse any of this content visit <http://group.bmj.com/group/rights-licensing/permissions>.
BMJ Case Report Fellows may re-use this article for personal use and teaching without any further permission.

Become a Fellow of BMJ Case Reports today and you can:

- ▶ Submit as many cases as you like
- ▶ Enjoy fast sympathetic peer review and rapid publication of accepted articles
- ▶ Access all the published articles
- ▶ Re-use any of the published material for personal use and teaching without further permission

For information on Institutional Fellowships contact consortiasales@bmjgroup.com

Visit casereports.bmj.com for more articles like this and to become a Fellow