

# A case of fulminant necrotising fasciitis

Kelsey van Son,<sup>1</sup> Claudia Savelkoul,<sup>2</sup> Roland Mollen,<sup>3</sup> David HT Tjan<sup>2</sup>

<sup>1</sup>Emergency Department, Gelderse Vallei Hospital, Ede, The Netherlands

<sup>2</sup>Department of Intensive Care, Gelderse Vallei Hospital, Ede, The Netherlands

<sup>3</sup>Department of Surgery, Gelderse Vallei Hospital, Ede, The Netherlands

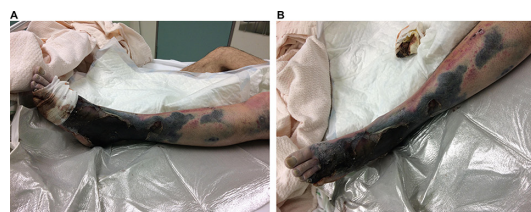
**Correspondence to**  
David HT Tjan, tjand@zgv.nl

KS and CS contributed equally.

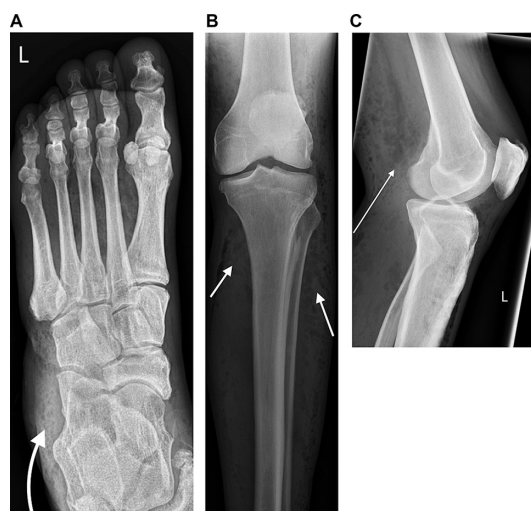
Accepted 27 March 2017

## DESCRIPTION

A 57-year-old man presented to the emergency department with fever, chills and a wound on his



**Figure 1** (A,B) The extension of necrotising fasciitis of the left lower extremity.

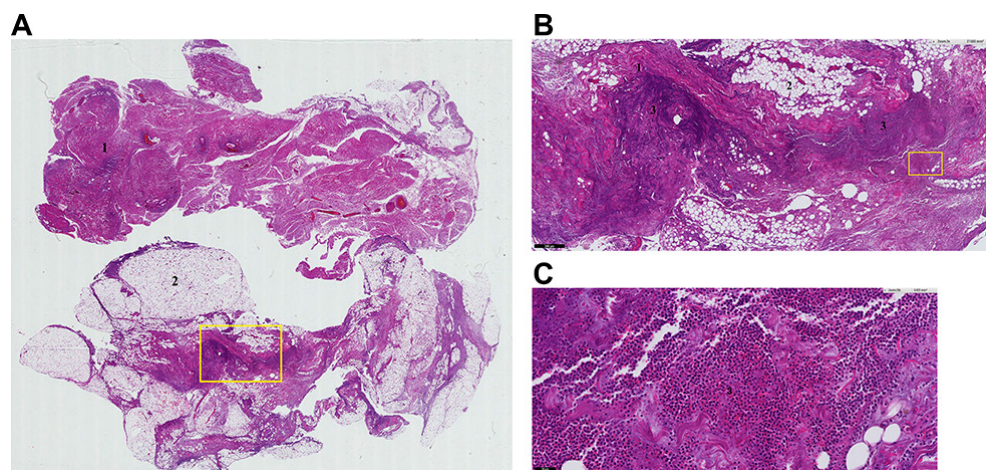


**Figure 2** X-rays of the foot (A) and knee (B and C) showing subcutaneous air (arrows), which is typical of necrotising fasciitis.

left foot since 2 weeks. He had no previous medical history. Despite receiving flucloxacillin, the wound was neglected and became necrotic with skin discoloration and a purulent, foul-smelling discharge. The leg developed functional impairment with severe claudication pain. All digits were pale, cold and numb (figure 1A, B). Biochemistry showed high infection parameters and hyperlactaemia as a sign of hypoperfusion. Hyperglycaemia revealed de novo diabetes. X-rays of the left lower extremity showed subcutaneous air (figure 2A–C).

Patient underwent immediate left transfemoral amputation. Postoperatively he was treated in the intensive care unit with piperacilline/tazobactam and clindamycin due to septic shock. Microbiological cultures revealed a *Bacteroides fragilis* and *Pasteurella* species. Histology confirmed necrotising fasciitis (figure 3A–C). CT angiography showed a stenosis in the common and left external iliac artery for which a stent was placed by percutaneous transluminal angioplasty (figure 4). Patient recovered and was discharged to a rehabilitation centre.

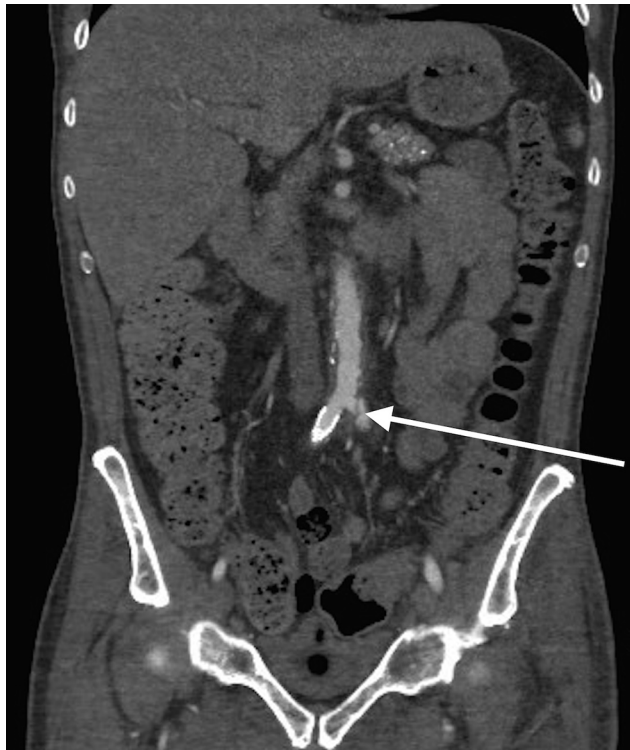
This case illustrates that delayed recognition and treatment can cause rapid disease progression and increases the risk of a poor outcome. It is characterised by inflammation, sepsis, multiorgan failure and even death, with a mortality rate of 30%.<sup>1,2</sup> There are many risk factors for development of necrotising fasciitis (box). Necrotising fasciitis is polymicrobial in nature, with most cultures yielding a mixture of aerobic and anaerobic organisms (table 1). Early diagnosis of necrotising fasciitis and aggressive treatment with surgical debridement and antibiotics determine its outcome.<sup>3</sup> Despite excellent healthcare in developed western countries, a fulminant course of necrotising fasciitis with disabling outcomes can still occur.



**Figure 3** (A) Overview of tissue from the left lower extremity affected by necrotising fasciitis showing fascia (1) and fat tissue (2). (B) The infiltrate (3) is localised next to the fascia (1). (C) The infiltrate (3) contains neutrophils, which implies bacterial infection. A pathology analysis contributes to the clinical diagnosis of necrotising fasciitis.



**To cite:** van Son K, Savelkoul C, Mollen R, et al. *BMJ Case Rep* Published Online First: [please include Day Month Year]. doi:10.1136/bcr-2016-219142



**Figure 4** CT scan showing a stenosis (arrow) of the common and external left iliac artery left.

#### Box Risk factors for necrotising fasciitis

**Immunosuppression:** medication (such as steroids, chemotherapy, infliximab) or disease (AIDS, malignancy, tuberculosis) induced

**Cardiovascular diseases:** arteriosclerosis, congestive heart failure, renal failure

**Trauma:** fractures, surgery, insect/animal bites, frostbite, intravenous drug abuse

**Skin diseases:** systemic lupus erythematosus, abscess, psoriasis, varicella

**Gastrointestinal:** diverticulitis, perirectal abscess or perforated viscus

**Other:** diabetes mellitus, obesity, pregnancy, advanced age

**Table 1** Bacteria causing necrotising fasciitis

Gram-positive aerobic bacteria	Gram-negative aerobic bacteria	Anaerobic bacteria
Group A $\beta$ -haemolytic streptococci	<i>Escherichia coli</i>	<i>Bacteroides</i> spp
Group B streptococci	<i>Pseudomonas aeruginosa</i>	<i>Clostridium</i> spp
Enterococci	<i>Proteus</i> spp	<i>Peptostreptococcus</i> spp
Coagulase negative staphylococci	<i>Serratia</i> spp	
<i>Staphylococcus aureus</i>		
<i>Bacillus</i> spp		

#### Learning points

- Provide adequate instructions to patients with wounds in order to prevent unnecessary extension and impairment; especially in patients with risk factors, such as diabetes and smoking.
- Necrotising fasciitis is an uncommon but potentially fatal condition especially if unrecognised.
- Management should consist of immediate resuscitation, early surgical debridement and administration of broad spectrum intravenous antibiotics.

**Contributors** KvS is responsible for admitting the patient to the hospital, participated in writing the article (and revision), and received informed consent from the patient. CS is responsible for care of the patient in the ICU and participated in writing the article (and revision). DHTT is responsible for care of the patient in the ICU and critically revised the article. RM is responsible for surgical care of the patient and critically revised the article. KvS and CS are guarantors.

**Competing interests** None declared.

**Patient consent** Obtained.

**Provenance and peer review** Not commissioned; externally peer reviewed.

© BMJ Publishing Group Ltd (unless otherwise stated in the text of the article) 2017. All rights reserved. No commercial use is permitted unless otherwise expressly granted.

#### REFERENCES

- 1 Van S, De VJ, Bijker JB, *et al.* Review of 58 patients with necrotizing fasciitis in the Netherlands. *World J Emerg Surg* 2016;11:7–12.
- 2 Corona PS, Erimeiku F, Reverté-Vinaixa MM, *et al.* Necrotising fasciitis of the extremities: implementation of new management technologies. *Injury* 2016;47(Suppl 3):S66–S71.
- 3 Singh G, Bharpoda P, Reddy R. Necrotizing fasciitis: a study of 48 cases. *Indian J Surg* 2015;77:345–50.

Copyright 2017 BMJ Publishing Group. All rights reserved. For permission to reuse any of this content visit <http://group.bmj.com/group/rights-licensing/permissions>.  
BMJ Case Report Fellows may re-use this article for personal use and teaching without any further permission.

Become a Fellow of BMJ Case Reports today and you can:

- Submit as many cases as you like
- Enjoy fast sympathetic peer review and rapid publication of accepted articles
- Access all the published articles
- Re-use any of the published material for personal use and teaching without further permission

For information on Institutional Fellowships contact [consortiasales@bmjgroup.com](mailto:consortiasales@bmjgroup.com)

Visit [casereports.bmj.com](http://casereports.bmj.com) for more articles like this and to become a Fellow