

Anisakiasis: a growing cause of abdominal pain!

Joana Carmo,¹ Susana Marques,¹ Miguel Bispo,^{1,2} David Serra²

¹Department of Gastroenterology, Hospital Egas Moniz, Centro Hospitalar de Lisboa Ocidental, Lisboa, Portugal

²Department of Gastroenterology, Hospital da Luz, Lisboa, Portugal

Correspondence to

Dr Joana Carmo,
joanavcarmo@gmail.com

Accepted 12 March 2017

DESCRIPTION

A previously healthy man, aged 32 years, was admitted with severe epigastric pain, vomiting and low-grade fever since the previous week. On physical examination, he had moderate abdominal tenderness. Laboratory results showed mild leucocytosis. After a careful interview, he revealed that he recently ate sushi. An upper gastrointestinal endoscopy was performed and showed on the gastric body, a filiform parasite firmly attached to an area of swollen and hyperaemic mucosa, with its end penetrating the gastric mucosa (figure 1). The larva was removed with a Roth net and the patient's symptoms resolved immediately (figure 2). Microbiological analysis showed the larva belonged to *Anisakis* spp.

Anisakiasis is a zoonosis caused by nematode parasites of the genus *Anisakis*.¹ It is caused by the consumption of contaminated raw or undercooked fish or seafood.² Most of the cases were described in Japan due to food habits; however, it has been increasingly recognised in Western countries.²⁻³ Patients can have allergic symptoms like angioedema, urticarial and anaphylaxis.¹ Gastrointestinal symptoms include abdominal pain, nausea and vomiting and complications like digestive bleeding, bowel obstruction, perforation and peritonitis can also arise.¹ Patients can have a low-grade fever.¹ A severe leucocytosis can be present, but peripheral eosinophilia is rare.³ Three clinical patterns of the gastrointestinal tract involvement were described and all of them can mimic an acute surgical abdomen: (1) gastric acute form in which endoscopic removal of the larva is a curative treatment;¹⁻² (2) intestinal form with an acute or chronic presentation, a more challenging diagnosis

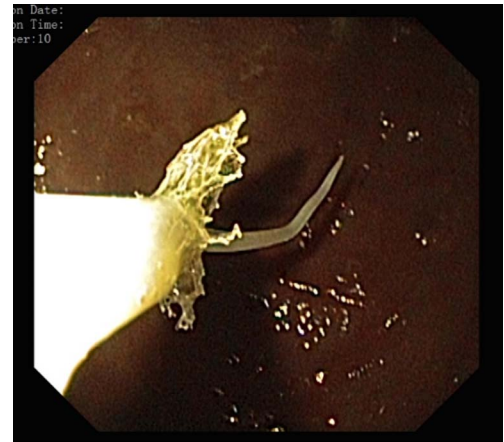

Figure 2 The larva was removed with a Roth net.

and classically surgically treated;¹⁻³ (3) ectopic subtype with peritoneal cavity involvement.²⁻³

Learning points

- ▶ Owing to changes in food habits, anisakiasis is a growing disease in Western countries, which should be suspected in patients with a history of ingestion of raw or uncooked fish.
- ▶ Anisakiasis can mimic an acute surgical abdomen.
- ▶ Endoscopy plays an important role in the diagnosis and treatment of gastric anisakiasis.

Contributors JC and SM did the writing of the manuscript. DS and MB were responsible for the revision of its contents.

Competing interests None declared.

Patient consent Obtained.

Provenance and peer review Not commissioned; externally peer reviewed.

REFERENCES

- 1 Shimamura Y, Muwanwella N, Chandran S, et al. Common symptoms from an uncommon infection: gastrointestinal anisakiasis. *Can J Gastroenterol Hepatol* 2016;2016:5176502.
- 2 Bucci C, Gallotta S, Morra I, et al. Anisakis, just think about it in an emergency. *Int J Infect Dis* 2013;17:e1071-2.
- 3 Ortega AR, Torres MA, Frutos CG, et al. Gastrointestinal anisakiasis. Study of a series of 25 patients. *Gastroenterol Hepatol* 2003;26:341-6.

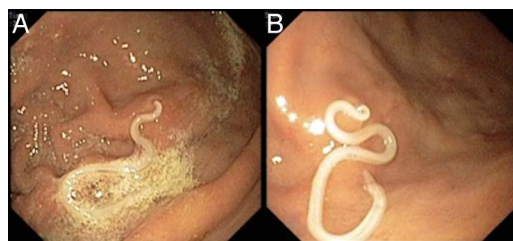


Figure 1 A parasite firmly attached to an area of swollen and hyperaemic mucosa, with its end penetrating gastric mucosa, was seen on the gastric body in an upper gastrointestinal endoscopy.



To cite: Carmo J, Marques S, Bispo M, et al. *BMJ Case Rep* Published online: [please include Day Month Year] doi:10.1136/bcr-2016-218857

Copyright 2017 BMJ Publishing Group. All rights reserved. For permission to reuse any of this content visit <http://group.bmj.com/group/rights-licensing/permissions>.
BMJ Case Report Fellows may re-use this article for personal use and teaching without any further permission.

Become a Fellow of BMJ Case Reports today and you can:

- ▶ Submit as many cases as you like
- ▶ Enjoy fast sympathetic peer review and rapid publication of accepted articles
- ▶ Access all the published articles
- ▶ Re-use any of the published material for personal use and teaching without further permission

For information on Institutional Fellowships contact consortiasales@bmjgroup.com

Visit casereports.bmj.com for more articles like this and to become a Fellow