

Rare case of pyoderma gangrenosum originating in the spleen

Tatsuya Fujikawa,^{1,2} Takayasu Suzuka³

¹Mitoyo General Hospital, Kan-onji, Japan

²Seikeikai Hospital, Sakai, Japan

³Department of Internal Medicine (I), Osaka Medical College, Takatsuki, Japan

Correspondence to

Dr Tatsuya Fujikawa, tfujikawa-gi@umin.ac.jp

The abstract was previously presented as a poster at the Society of General Internal Medicine annual meeting in 2015 (Tracking ID number 2144481).

Accepted 5 February 2017

DESCRIPTION

A 51-year-old woman with a moderately controlled type 2 diabetes and previous diagnosis of pyoderma gangrenosum (PG) of the neck presented with acute fever, left upper quadrant pain and isolated splenomegaly. Abdominal contrast-enhanced CT demonstrated loculated splenic collections with thick enhancing walls (figure 1) suspicious for abscess. Although we considered an infectious abscess in the spleen as a differential diagnosis, blood cultures had no growth. After 1 week of antibiotics, imaging demonstrated enlargement of the splenic lesions. Open splenectomy was performed because antibiotics did not show an effect and there was a concern for splenic rupture. The splenic abscesses (figure 2) contained large numbers of inflammatory cells, mainly neutrophils.

The patient was at risk for infection due to only moderately controlled diabetes. Nevertheless, sterile neutrophilic infiltrates in the spleen were observed because neither blood cultures prior to

antibiotic use nor splenic collections demonstrated any bacterial growth.

PG originating in the spleen was diagnosed, and she improved with prednisolone. However, as prednisolone was tapered, an intra-abdominal abscess developed, along with a skin abscess in the neck. Assuming exacerbation of PG, we added cyclosporine A, leading to disappearance of the abscesses.

PG is an idiopathic neutrophilic dermatosis, considered a reaction to a condition such as inflammatory bowel disease, rheumatoid arthritis or paraproteinaemia.^{1 2} Diagnosis requires exclusion of other similar-appearing disorders.^{1 2} PG often develops at sites of skin trauma, such as scars, but can occur anywhere, though splenic PG is rarely reported.³ Treatment options include prednisolone, cyclosporine, tumour necrosis factor blockers, intravenous immunoglobulin, plasmapheresis and methotrexate,^{1 3} but PG is often intractable. Surgery, including ulcer debridement, is usually avoided during active disease due to the risk of triggering new lesions.^{1 3} However, surgery may be required if there is risk of death with medical management alone.¹ Such patients require systemic immunosuppressive therapy prior to surgery to avoid risk of recurrence.¹

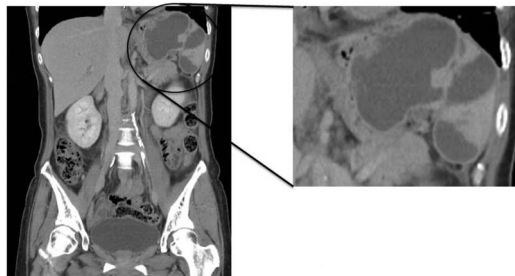


Figure 1 Abdominal contrast-enhanced CT demonstrated loculated splenic collections with thick enhancing walls (figure 1) suspicious for abscess.

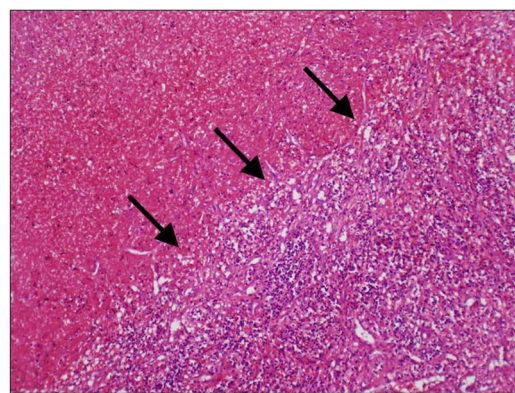


Figure 2 Pathology findings in the spleen showing splenic abscess-like nodules (arrows) containing large numbers of inflammatory cells, mainly neutrophils, consistent with pyoderma gangrenosum.

Learning points

- ▶ Pyoderma gangrenosum (PG) is a rare idiopathic neutrophilic dermatosis often associated with systemic diseases such as inflammatory bowel disease and arthritis.
- ▶ PG can occur anywhere on the body and particularly in traumatic or surgical scars.
- ▶ PG must be treated with systemic steroids or immunosuppressive agents, but sometimes even surgery is required, though it is generally contraindicated.

Contributors TF wrote, reviewed and edited the manuscript and contributed to discussion. TS also contributed to discussion.

Competing interests None declared.

Patient consent Obtained.

Provenance and peer review Not commissioned; externally peer reviewed.

REFERENCES

- 1 Khajehnoori M, O'Brien T. A case of surgically treated peristomal pyoderma gangrenosum in a patient with rheumatoid arthritis. *J Surg Case Rep* 2016;2016:rjw103.
- 2 Powell FC, Su WD, Perry HO. Pyoderma gangrenosum: classification and management. *J Am Acad Dermatol* 1996;34:395–409.
- 3 Cohen PR. Neutrophilic dermatoses. *Am J Clin Dermatol* 2009;10:301–12.



To cite: Fujikawa T, Suzuka T. *BMJ Case Rep* Published online: [please include Day Month Year] doi:10.1136/bcr-2016-216909

Copyright 2017 BMJ Publishing Group. All rights reserved. For permission to reuse any of this content visit <http://group.bmj.com/group/rights-licensing/permissions>.
BMJ Case Report Fellows may re-use this article for personal use and teaching without any further permission.

Become a Fellow of BMJ Case Reports today and you can:

- ▶ Submit as many cases as you like
- ▶ Enjoy fast sympathetic peer review and rapid publication of accepted articles
- ▶ Access all the published articles
- ▶ Re-use any of the published material for personal use and teaching without further permission

For information on Institutional Fellowships contact consortiasales@bmjgroup.com

Visit casereports.bmj.com for more articles like this and to become a Fellow