

Airway compromising an airway

Andrew Wesley Hoey,¹ Neil Foden,² Richard Oakley²

¹Department of Otolaryngology and Head and Neck Surgery, Royal National Throat, Nose and Ear Hospital, London, UK
²Department of Otolaryngology and Head and Neck Surgery, Guy's and St Thomas' NHS Foundation Trust, London, UK

Correspondence to
 Andrew Wesley Hoey,
 andrew.hoey@nhs.net

Accepted 16 June 2016

DESCRIPTION

There are several tracheostomy tube types that can be used by patients who present to the emergency department with temporary or long-term artificial airways. While specific knowledge of each type may not be required, it is important for the emergency physician to be aware of their general structure and the complications that can arise from them. Modern tracheostomy tubes tend to be made of plastic, but some older tubes—such as the silver Negus—can be made of metal. These tubes are particularly popular with older long-term tracheostomy patients. However, due to their cost and relative scarcity, these tubes tend to be used for longer than their intended life-span and are therefore at risk of excess wear.

A 48-year-old ventilator dependent man with a silver Negus tracheostomy in situ presented to our unit acutely distressed, but not decompensated. He was mildly tachycardic, but maintained oxygen saturation via his ventilator. The metal outer cannula of his tracheostomy tube had broken off and became lodged in his left main bronchus (figure 1). The patient underwent a rigid bronchoscopy and the outer cannula was removed with minimal trauma (figure 2). He suffered transient dysphonia due to mild glottic oedema, but made a quick recovery and was later discharged home.

The fracture of silver tracheostomy tubes is rare, but has previously been reported in the literature.¹ Up to 70% of these cases involve metal (silver, copper, nickel or zinc) tracheostomy tubes.² As in this case, the fracture generally occurs at the junction between the base plate and outer cannula (figure 3). Fractures are in this location in over 80% of cases, irrespective of tube type.³

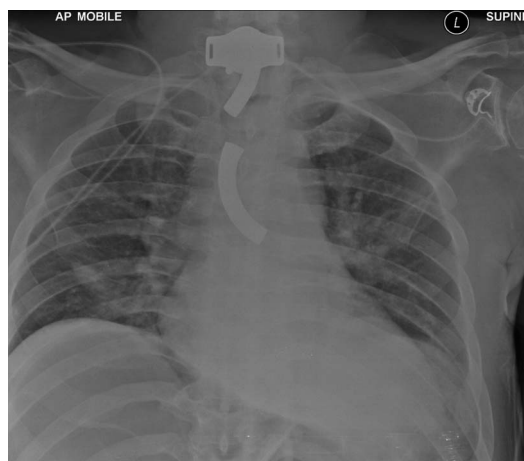

Figure 1 Chest X-ray demonstrating dislodged metal outer cannula resting in the left main bronchus. The metal base plate and remaining inner tube of the tracheostomy can also be seen.

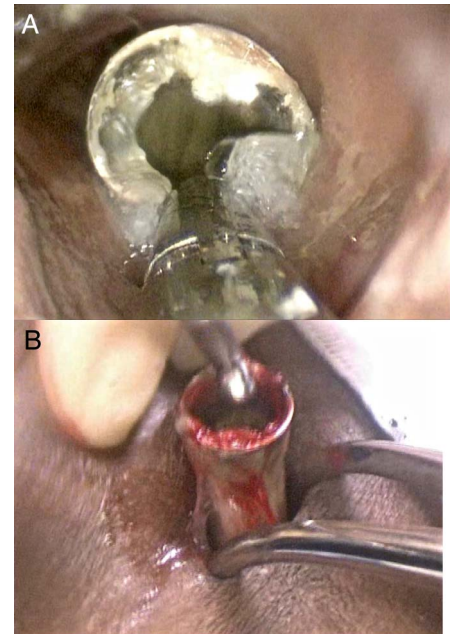


Figure 2 Silver Negus outer cannula being removed from the left main bronchus (A) and the tracheostomy stoma (B).

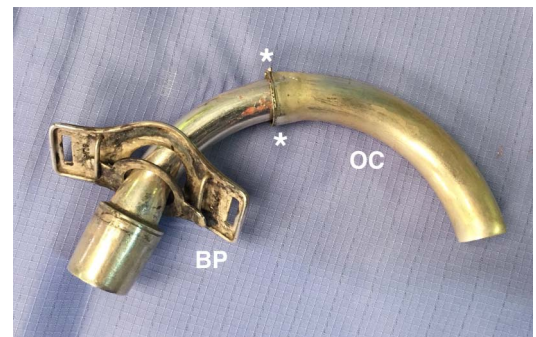


Figure 3 Fractured silver Negus tracheostomy tube showing fracture of OC from BP and the fracture site (*). BP, base plate; OC, outer cannula.

Learning points

- ▶ Airway foreign bodies are a common cause of airway compromise and the presence of surgical airways can make the management of these patients additionally challenging.
- ▶ The majority of tracheostomy tubes are now plastic, but older tubes made of metal may still be encountered.
- ▶ Urgent senior Ear, Nose and Throat input should be gained early in the acute management of these patients.



To cite: Hoey AW, Foden N, Oakley R. *BMJ Case Rep* Published online: [please include Day Month Year] doi:10.1136/bcr-2016-215761

Airway foreign bodies are a common cause for patients presenting to the emergency department with acute airway compromise. Managing such a patient with an artificial airway can be daunting, but knowledge of tracheostomy tubes and of the potential complications they may cause can mediate this. However, an urgent ear, nose and throat senior review should always be sought in the case of acute surgical airway compromise.

Contributors AWH reviewed the literature and prepared the manuscript. NF provided critical review and images. RO revised and supervised the manuscript.

Competing interests None declared.

Patient consent Obtained.

Provenance and peer review Not commissioned; externally peer reviewed.

REFERENCES

- 1 Brockhurst PJ, Feltoe CK. Corrosion and fracture of a silver tracheostomy tube. *J Laryngol Otol* 1991;105:48–9.
- 2 Pirochchai P, Lertchanaruengrit P, Vatanasapt P, *et al*. Fractured metallic tracheostomy tube in a child: a case report and review of the literature. *J Med Case Rep* 2010;4:234.
- 3 Parida PK, Kalaiarasi R, Gopalakrishnan S, *et al*. Fractured and migrated tracheostomy tube in the tracheobronchial tree. *Int J Pediatr Otorhinolaryngol* 2014;78:1472–5.

Copyright 2016 BMJ Publishing Group. All rights reserved. For permission to reuse any of this content visit <http://group.bmj.com/group/rights-licensing/permissions>.
BMJ Case Report Fellows may re-use this article for personal use and teaching without any further permission.

Become a Fellow of BMJ Case Reports today and you can:

- ▶ Submit as many cases as you like
- ▶ Enjoy fast sympathetic peer review and rapid publication of accepted articles
- ▶ Access all the published articles
- ▶ Re-use any of the published material for personal use and teaching without further permission

For information on Institutional Fellowships contact consortiasales@bmjgroup.com

Visit casereports.bmj.com for more articles like this and to become a Fellow