

Delayed airway extrusion of type 1 thyroplasty Gore-Tex implant

James Morris, David Mike Thomas

Department of ENT,
Gloucestershire Hospitals NHS
Foundation Trust, Gloucester,
UK

Correspondence to
James Morris,
james.morris@glos.nhs.uk

Accepted 3 July 2016

DESCRIPTION

In March 2005, a 46-year-old woman suffered with a right-sided unilateral idiopathic vocal fold palsy that failed to recover. She underwent type 1 thyroplasty where a length of Gore-Tex ribbon was implanted via an external approach in order to medialise the paralysed vocal fold and so as to improve voice quality.

After an initially excellent response to the procedure and voice therapy, she was discharged from follow-up in December 2005. In 2015 she developed dysphonia and flexible nasendoscopy demonstrated an anterior commissure polyp with an overlying granulation tissue (figure 1). The edge of the implant was also seen extruding into an otherwise stable airway. The patient declined CT scanning and open removal of the implant, choosing instead to proceed to examination under an

anaesthetic and endoscopic removal of the implant (figures 2 and 3). The patient recovered uneventfully and has declined a further medialisation procedure. Her voice has recovered with no swallowing difficulties (figure 4).

This was a popular technique for vocal cord medialisation. However, the current favoured technique is injectable materials such as hyaluronic acid.¹ Complications such as rejection and extrusion of Gore-Tex implants following external approach thyroplasty have been reported at early stages but literature review did not reveal such a late manifestation.² This case is important because it highlights

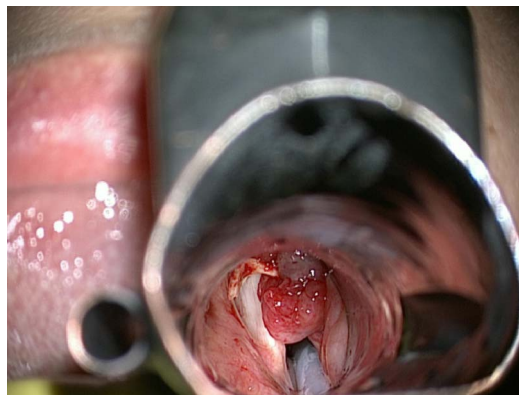

Figure 1 Implant extrusion into airway with associated granulation tissue presenting a potential airway compromise.

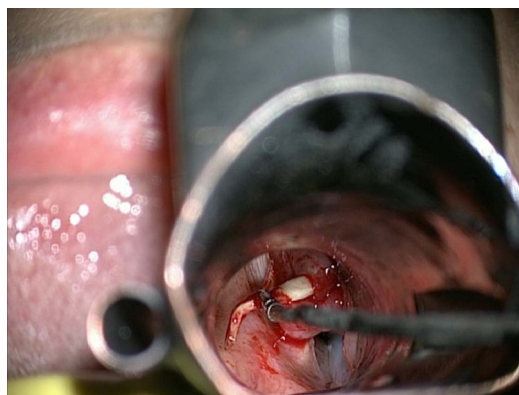

Figure 2 The implant is removed intact endoscopically with a standard microlaryngoscopy set up and jet insufflation.

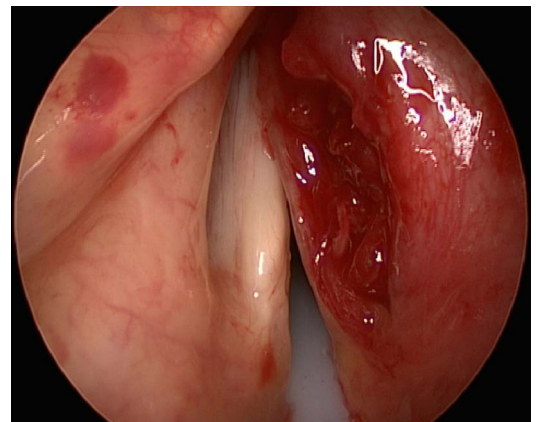


Figure 3 Postextraction view. The implant was removed intact but there was a significant tissue deficit in the right vocal fold.

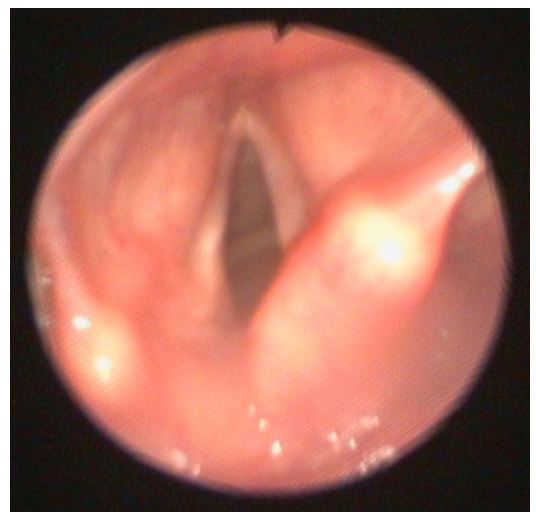

Figure 4 Six weeks postprocedure endoscopic view. The mucosal covering of the vocal folds had completely re-epithelialised.



To cite: Morris J,
Thomas DM. *BMJ Case Rep*
Published online: [please
include Day Month Year]
doi:10.1136/bcr-2016-
215704

that extrusion of this material is possible at this late stage with potentially life-threatening consequences.

Learning points

- ▶ Extrusion of implants can occur at unexpectedly late stages.
- ▶ Such complications can be airway obstructing and life-threatening.

Contributors JM wrote the manuscript and supervised by DMT.

Competing interests None declared.

Patient consent Obtained.

Provenance and peer review Not commissioned; externally peer reviewed.

REFERENCES

- 1 Costello D. Change to earlier surgical interventions: contemporary management of unilateral vocal fold paralysis. *Curr Opin Otolaryngol Head Neck Surg* 2015;23:181–4.
- 2 Cotter CS, Avidano MA, Crary MA, *et al.* Laryngeal complications after type 1 thyroplasty. *Otolaryngol Head Neck Surg* 1995;113:671–3.

Copyright 2016 BMJ Publishing Group. All rights reserved. For permission to reuse any of this content visit <http://group.bmj.com/group/rights-licensing/permissions>.

BMJ Case Report Fellows may re-use this article for personal use and teaching without any further permission.

Become a Fellow of BMJ Case Reports today and you can:

- ▶ Submit as many cases as you like
- ▶ Enjoy fast sympathetic peer review and rapid publication of accepted articles
- ▶ Access all the published articles
- ▶ Re-use any of the published material for personal use and teaching without further permission

For information on Institutional Fellowships contact consortiasales@bmjgroup.com

Visit casereports.bmj.com for more articles like this and to become a Fellow