Lessons learnt from a case of multiple myeloma

Raju Vaishya, Amit Kumar Agarwal, Vipul Vijay

Orthopaedic & Joint Replacement Surgery, Indraprastha Apollo Hospitals, New Delhi, India

Correspondence to
Professor Raju Vaishya, raju.vaishya@gmail.com

Accepted 12 August 2015

DESCRIPTION

A 41-year-old man presented with pain in his right arm for 6 weeks, with no systemic problems. Radiography revealed a large lytic lesion in the proximal third of the humerus (figure 1), with elevated erythrocyte sedimentation rate (ESR; 81 mm) and increased uptake only in the right humerus (figure 2) on a three phase isotope technetium 99-m (99mTc) bone scan. Histology of the lesion indicated it to be multiple myeloma; the tumour cells were positive for CD45 and CS 138. Following core biopsy, the patient sustained a pathological fracture requiring a closed interlocking humeral nail (figure 3). A positron emission tomography CT (PET/CT) scan revealed multiple FDG (18F fluoro-2-deoxy-D-glucose) avid skeletal lesions (figure 4) and increased uptake in the right proximal humerus (figure 5). A bone marrow biopsy showed an increased (40%) and unevenly distributed population of plasma cells (figure 6), suggestive of multiple myeloma.

A solitary lytic lesion in the diaphysis of a long bone with a high ESR could present a diagnostic dilemma as it may mimic infection, or a benign, malignant or metastatic tumour. Isotope bone scanning has limited usefulness in osteolytic lesions as it can only detect bony involvement if there is osteoblastic response.[1] A PET/CT scan is a better imaging modality, as it is able to early on detect a lesion and also can assess the extent of activeness of disease.[2] Owing to the high-metabolic rate of tumour cells, there is resultant

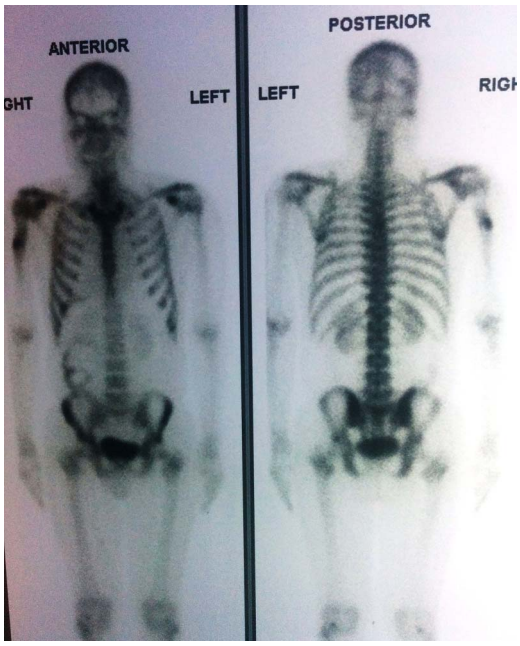

Figure 2 A radionuclide isotope bone scan showing increased uptake in the right proximal humerus and normal tracer distribution in the remaining skeleton.

Figure 1 Anteroposterior radiograph of the humerus showing a large osteolytic lesion involving the upper third of the humerus.

Figure 3 A pathological fracture of the humerus fixed with an interlocking humeral nail.

To cite: Vaishya R, Agarwal AK, Vijay V. *BMJ Case Rep* Published online: [*please include* Day Month Year] doi:10.1136/bcr-2015-211358

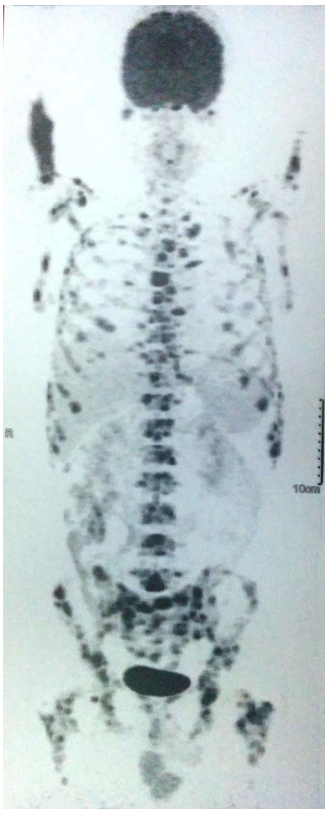

Figure 4 A positron emission tomography/CT scan showing diffuse and multiple involvement of skeleton.

Figure 5 Increase fluoro-2-deoxy-D-glucose uptake in proximal humerus on positron emission tomography/CT scan.

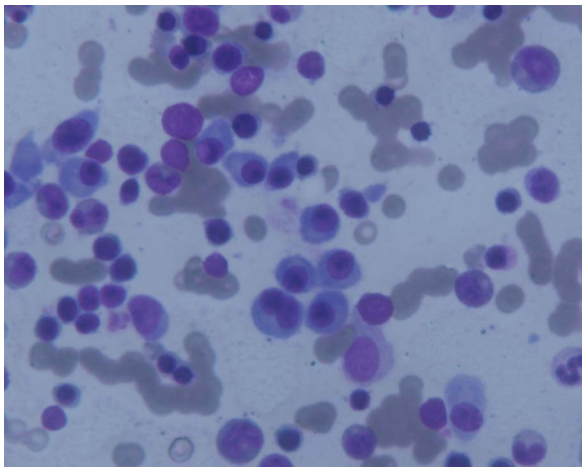

Figure 6 Bone marrow biopsy showing increased and unevenly distributed plasma cells.

higher demand for glucose, and therefore the FDG uptake is increased, differentiating them from normal cells. Large osteolytic lesions are prone to pathological fractures and should be considered for prophylactic fixation, as per Mirels' criteria.[3] In this case, the score was 9 and should have been considered for prophylactic fixation, which might have prevented a pathological fracture.

Learning points

- Osteolytic lesions are best seen on positron emission tomography scan; an isotope radionuclide bone scan can miss these lesions, as there is no osteoblastic activity.
- Large lytic lesions should be prophylactically fixed with a nail or plate to avoid pathological fracture, if the Mirels' score is high (>8).
- A bone biopsy in large lytic lesions may be associated with a pathological fracture and hence must be performed carefully and only if absolutely necessary.

Competing interests None declared.

Patient consent Obtained.

Provenance and peer review Not commissioned; externally peer reviewed.

REFERENCES

1 Healy CF, Murray JG, Eustace SJ, *et al*. Multiple myeloma: a review of imaging features and radiological techniques. *Bone Marrow Res* 2011;2011:583439.
2 Fogelman I, Cook G, Israel O, *et al*. Positron emission tomography and bone metastases. *Semin Nucl Med* 2005;35:135–42.
3 Mirels H. Metastatic disease in long bones. A proposed system for diagnosing impending pathological fractures. *Clin Orthop Relat Res* 1989;249:256–64.