

# Spectral-domain optical coherence tomography findings of peripapillary staphyloma

Jia-Kang Wang,<sup>1,2</sup> Tzu-Lun Huang<sup>2</sup>

<sup>1</sup>Department of Medicine, National Yang Ming University, Taipei, Taiwan  
<sup>2</sup>Department of Ophthalmology, Far Eastern Memorial Hospital, New Taipei, Taiwan

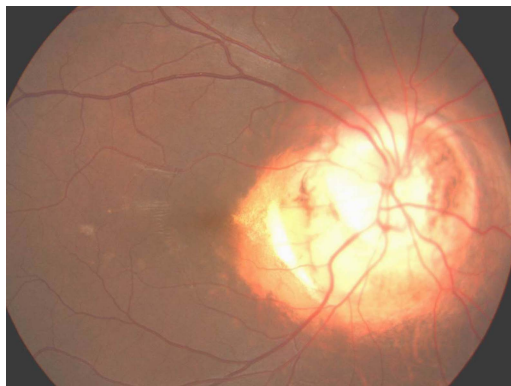## Correspondence to

Dr Jia-Kang Wang,  
 jiakangw2158@gmail.com

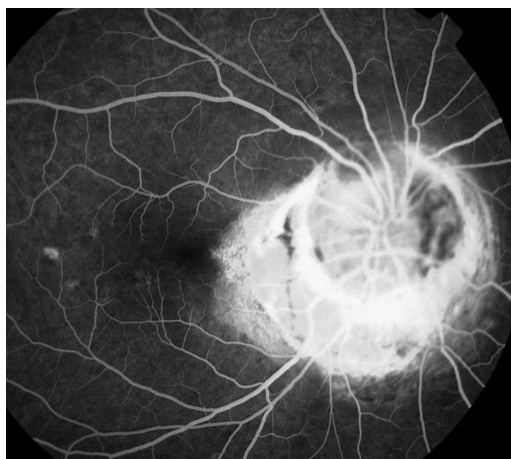
Accepted 1 May 2015

## DESCRIPTION

A 10-year-old girl presented with blurred vision in her right eye since birth. Birth, developmental and medical histories were otherwise unremarkable. Her best corrected visual acuity was 20/30 and 20/20 in the right and left eyes, respectively, with bilateral mild myopia (−3.5 dioptres). Anterior segment, lens, ocular motility, Ishihara test and intraocular pressure were normal. Relative afferent papillary defect was negative. Normal fundus was found in the left eye. Right fundus photography revealed large peripapillary atrophy (deep cupping surrounding optic disc especially in the inferior side) with 6 disc diameters in width surrounded by pigmented ring with normal retinal vasculature

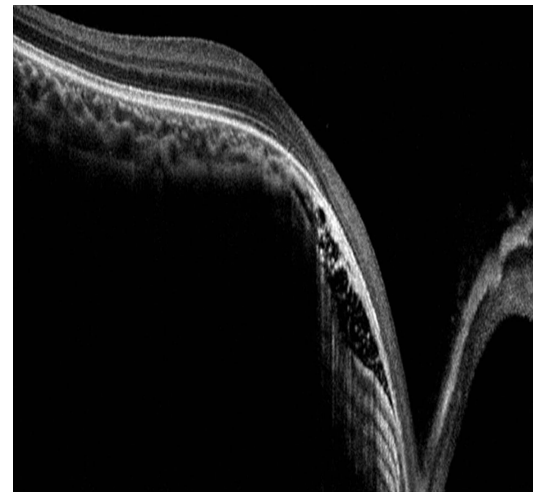


**Figure 1** Large peripapillary atrophy (deep cupping surrounding optic disc especially in the inferior side) with 6 mm disc diameter in width surrounded by pigmented ring with normal retinal vasculature on fundus photography.

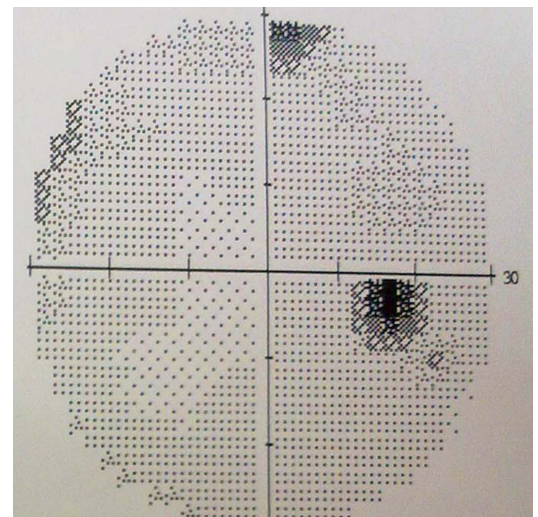


**Figure 2** Staining of peripapillary atrophy was found by fundus fluorescein angiography.

(figure 1). There was no overlying central glial white veil on the disc and it was not associated with choroidal coloboma, excluding possibilities of morning glory syndrome and optic disc coloboma.<sup>1</sup> Staining of peripapillary atrophy was found by fundus fluorescein angiography (figure 2). The patient was diagnosed as peripapillary staphyloma. The spectral-domain optical coherence tomography (RTVue, Optovue, New York, USA) demonstrated deep excavation between fovea and disc, 2.1 mm in depth. There was normal foveal structure without accompanying serous macular detachment



**Figure 3** Spectral-domain optical coherence tomography demonstrated deep excavation between fovea and disc, 2.1 mm in depth, but normal foveal structure.



**Figure 4** Visual field showing mild upper field defect.



To cite: Wang J-K, Huang T-L. *BMJ Case Rep* Published online: [please include Day Month Year] doi:10.1136/bcr-2015-210558

(figure 3). The visual field showed mild upper field defect corresponding to deep inferior optic cupping (figure 4). Kim *et al*<sup>2</sup> described the largest case series, including 19 patients with

### Learning points

- ▶ Peripapillary staphyloma is a rare congenital disease, having deep fundus excavation of chorioretinal atrophy surrounding a relatively normal appearing optic disc, and normal retinal vasculature, without retinochoroidal coloboma.
- ▶ Peripapillary staphyloma is mostly unilateral, sporadic and non-hereditary, and results from developmental failure of the posterior sclera from neural crest cells occurring around the fifth month of gestation.
- ▶ Peripapillary staphyloma may be associated with macular schisis or serous macular detachment, which can be demonstrated clearly on spectral-domain optical coherence tomography.

peripapillary staphyloma. Two patients (11%) had bilateral involvement. Variable visual acuity and refractive errors can be present. Other ocular and systemic abnormalities may be found among these patients. There was one case of a 4-year-old boy with peripapillary staphyloma reported to be associated with macular schisis and serous macular detachment found on spectral-domain optical coherence tomography.<sup>3</sup> To the best of our knowledge, this is the first case report associated with such findings of spectral-domain optical coherence tomography.

**Competing interests** None declared.

**Patient consent** Obtained.

**Provenance and peer review** Not commissioned; externally peer reviewed.

### REFERENCES

- 1 Dutton GN. Congenital disorders of the optic nerve: excavations and hypoplasia. *Eye* 2004;18:1038–48.
- 2 Kim SH, Choi MY, Yu YS, *et al*. Peripapillary staphyloma: clinical features and visual outcome in 19 cases. *Arch Ophthalmol* 2005;123:1371–6.
- 3 Woo SJ, Hwang JM. Spectral-domain optical coherence tomography of peripapillary staphyloma. *Graefes Arch Clin Exp Ophthalmol* 2009;247:1573–4.

Copyright 2015 BMJ Publishing Group. All rights reserved. For permission to reuse any of this content visit <http://group.bmj.com/group/rights-licensing/permissions>.  
BMJ Case Report Fellows may re-use this article for personal use and teaching without any further permission.

Become a Fellow of BMJ Case Reports today and you can:

- ▶ Submit as many cases as you like
- ▶ Enjoy fast sympathetic peer review and rapid publication of accepted articles
- ▶ Access all the published articles
- ▶ Re-use any of the published material for personal use and teaching without further permission

For information on Institutional Fellowships contact [consortiasales@bmjgroup.com](mailto:consortiasales@bmjgroup.com)

Visit [casereports.bmj.com](http://casereports.bmj.com) for more articles like this and to become a Fellow