

Successful primary coronary angioplasty for acute inferior myocardial infarction in a patient with RII-type single coronary artery

Aslı Vural,¹ Hakan Aksoy,² Ahmet Karagöz,¹ Barış Dindar²

¹Department of Cardiology, Giresun University, Giresun, Turkey

²Department of Cardiology, Kirikkale State Hospital, Kirikkale, Turkey

Correspondence to

Dr Ahmet Karagöz,
drahmetkgz@hotmail.com

Accepted 9 February 2015

DESCRIPTION

A single coronary artery is a rare coronary anomaly in which only one coronary artery arises from the aortic trunk by a single ostium and supplies the entire myocardium. Although rare, reports about revascularisation of congenitally abnormal coronary vessels are present in the literature.¹ We report a case of a 72-year-old man with previously unknown coronary anomaly presenting with acute inferior myocardial infarction.

The patient was admitted to the emergency room with typical chest pain at rest for 6 h. He was diagnosed as acute inferior myocardial infarction and coronary angiography was performed immediately. The left coronary artery ostium cannulation attempt failed. The right coronary artery (RCA) was cannulated with a right Judkins-guiding catheter. In the left anterior oblique cranial projection, the whole coronary system was visualised from a single ostium, located at the right sinus of Valsalva and giving off branches to the RCA and the left coronary system (figure 1). There was a thrombotic total occlusion in the proximal-portion of the RCA. There was an arterial collateral from left coronary system to RCA, which filled the distal part of the RCA anterogradely. The lesion was crossed with a 0.014-inch guidewire and a bare metal stent (3.5×16 mm) was implanted. Stenting of the occluded branch was performed successfully (figure 2). The patient was free

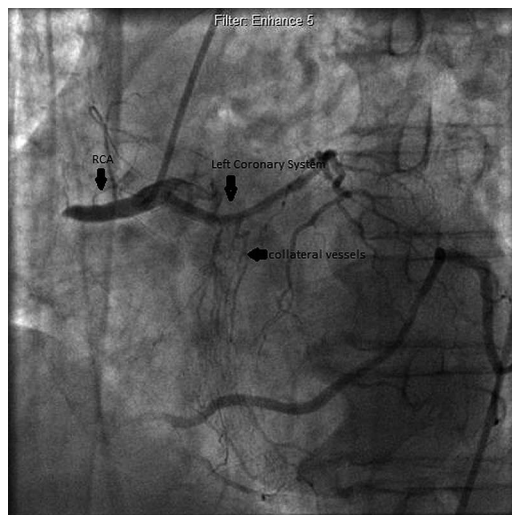


Figure 1 Demonstration of coronary arterial tree. The left coronary system arises from the proximal part of the right coronary artery (RCA). RCA is totally occluded in the proximal part and filling of the distal portion via collaterals from left coronary system is also seen.

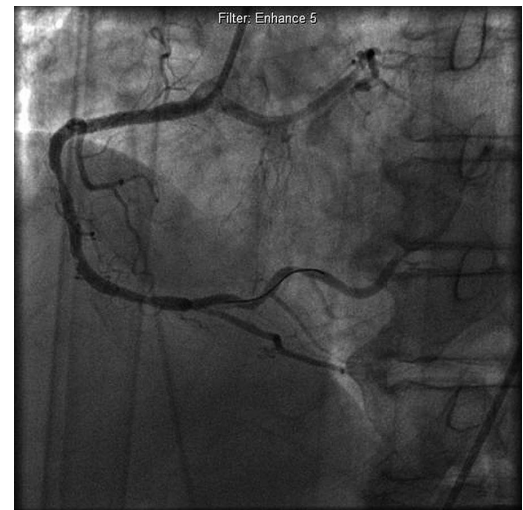

Figure 2 Appearance of right coronary artery after percutaneous transluminal coronary angioplasty.

from chest pain and discharged uneventfully. Single coronary artery anomalies are usually benign and asymptomatic. If a patient with single coronary artery anomaly has a heart attack, routine percutaneous intervention should be performed.

Learning points

- ▶ A single coronary artery is a rare congenital anomaly, with an incidence of 0.02% in patients who undergo coronary angiography.²
- ▶ Lipton method is used for classification of single coronary artery according to the site of origin and anatomical distribution of the branches.³
- ▶ In patients who require emergency percutaneous interventions, presence of coronary anomalies should not cause doubt about the performance of the procedure and the intervention should be applied as soon as possible.

Twitter Follow Ahmet Karagöz at @drahmetkgz

Contributors AV and HA participated in the writing of the manuscript and performed the percutaneous intervention. AK and BD participated in interpreting the data, taking care of the patient and reviewing the literature.

Competing interests None.

Patient consent Obtained.

Provenance and peer review Not commissioned; externally peer reviewed.



To cite: Vural A, Aksoy H, Karagöz A, et al. *BMJ Case Rep* Published online: [please include Day Month Year] doi:10.1136/bcr-2014-208325

REFERENCES

1 Dai J, Katoh O, Kyo E, *et al.* Percutaneous intervention in a patient with a single coronary artery arising from the right coronary sinus of Valsalva. *Hellenic J Cardiol* 2014;55:427–32.

2 Yamanaka O, Hobbs RE. Coronary artery anomalies in 126,595 patients undergoing coronary arteriography. *Cathet Cardiovasc Diagn* 1990;21:28–40.

3 Lipton MJ, Barry WH, Obrez I, *et al.* Isolated single coronary artery: diagnosis, angio-graphic classification, and clinical significance. *Radiology* 1979;130:39–47.

Copyright 2015 BMJ Publishing Group. All rights reserved. For permission to reuse any of this content visit <http://group.bmj.com/group/rights-licensing/permissions>.
BMJ Case Report Fellows may re-use this article for personal use and teaching without any further permission.

Become a Fellow of BMJ Case Reports today and you can:

- ▶ Submit as many cases as you like
- ▶ Enjoy fast sympathetic peer review and rapid publication of accepted articles
- ▶ Access all the published articles
- ▶ Re-use any of the published material for personal use and teaching without further permission

For information on Institutional Fellowships contact consortiasales@bmjgroup.com

Visit casereports.bmj.com for more articles like this and to become a Fellow