

## CASE REPORT

## Resection of a large carotid paraganglioma in Carney-Stratakis syndrome: a multidisciplinary feat

Rebecca Spenser Nicholas,<sup>1</sup> Ayyaz Quddus,<sup>2</sup> Charlotte Topham,<sup>2</sup> Daryll Baker<sup>2</sup><sup>1</sup>Department of Plastic & Reconstructive Surgery, Royal Free Hospital, London, UK<sup>2</sup>Department of Vascular Surgery, Royal Free Hospital, London, UK**Correspondence to**  
Rebecca Spenser Nicholas,  
rebeccanicholas@gmail.com

Accepted 21 February 2015

**SUMMARY**

A 39-year-old man was referred to the vascular surgeons with a right-sided cervical mass, palpitations, headaches and sweating. He had presented with abdominal discomfort 12 months earlier. Investigations had revealed a gastrointestinal stromal tumour (GIST) and left adrenalectomy. CT of the neck with contrast demonstrated a large right carotid paraganglioma, extending superiorly from below the carotid bifurcation to encase the internal carotid artery. Genetic screening confirmed the diagnosis of Carney-Stratakis syndrome, an SDH-D germline mutation leading to GIST and multifocal paragangliomas.

Successful surgical excision required considerable multidisciplinary teamwork between neuroendocrinologists, anaesthetists and surgeons. The tumour was highly vascular and involved the right carotid body, hypoglossal and vagus nerves. Access was challenging and maxillofacial surgical expertise were required for division of the mandible. The patient made a good recovery following speech and swallowing rehabilitation.

**BACKGROUND**

Multidisciplinary teamwork is essential in order to provide the best possible care for our patients. This report describes the management of a man with a rare syndrome that affects multiple organ systems, which required extensive medical and surgical collaboration.

Carney-Stratakis syndrome (CSS) is an autosomal dominant inherited condition comprising multifocal paragangliomas (PGLs) and gastrointestinal stromal tumours (GIST). It is a rare condition with a prevalence of <1/1 000 000, caused by germline mutations in succinate dehydrogenase subunits B, C or D leading to formation of neuroendocrine tumours with oncogenic activity.<sup>1 2</sup>

We report a case of large carotid PGL in CSS which necessitated extensive preoperative planning and teamwork between multiple disciplines. The tumour position, involvement and vascularity are characteristic of head and neck PGLs.<sup>3</sup> Collaboration between neuroendocrine physicians, anaesthetists, vascular and maxillofacial surgeons, and speech and language therapists (SALT) was essential in order to safely resect the tumour and rehabilitate the patient post-operatively. The case demonstrates clearly how teamwork between colleagues from various specialties was integral to achieving safe and effective patient care.

**CASE PRESENTATION**

A fit-and-well 39-year-old postman, with a family history of lung cancer and hypertension, was referred to the vascular surgeons with a right-sided cervical mass, palpitations, headaches and sweating. He had presented with abdominal discomfort 12 months earlier, and following investigation had been diagnosed with a stomach GIST and left adrenal pheochromocytoma, which had necessitated left adrenalectomy.

On examination he was normotensive with a blood pressure of 135/87 mm Hg, heart rate of 60 bpm. Head and neck examination demonstrated the right cervical mass with no palpable lymphadenopathy. General examination was unremarkable.

**INVESTIGATIONS**

At time of referral to vascular surgery, the patient had already undergone extensive investigations. Twelve months earlier when he had presented to his local hospital with vague abdominal discomfort, he underwent upper gastrointestinal endoscopy. This revealed a mass arising from the muscularis propria of the lesser curvature of the stomach. Biopsy and immunocytochemistry confirmed this to be a high-grade epithelioid GIST.

Following this diagnosis, contrast-enhanced CT scan of the chest, abdomen and pelvis demonstrated a stomach mass, consistent with the GIST, and a left supra-adrenal PGL. CT of the neck with contrast demonstrated a large right carotid PGL (9×4.5×2.3 cm), extending superiorly from below the carotid bifurcation to encase the internal carotid artery (figure 1). It also showed a small (8 mm) contralateral carotid body PGL located at the level of the second cervical vertebrae.

<sup>123</sup>I metaiodobenzylguanidine scintigraphy was subsequently conducted, revealing high uptake within the left supra-adrenal PGL. Left adrenalectomy was performed laparoscopically without complication prior to referral to the neuroendocrine team for their specialist opinion on the case.

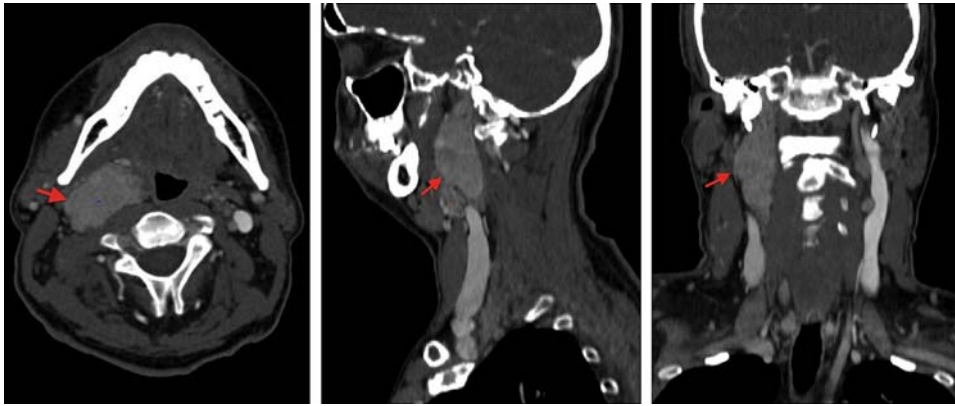
Blood and urine tests showed raised chromogranin A (66 IU/L; reference range 0–27), raised plasma normetadrenaline (2.20 nmol/L; reference range <1.3 nmol/L), raised 24 h urine normetadrenaline (4.84 nmol; reference range 0–4) and raised 24 h urine 3-methoxytyramine (11.26 nmol; reference range 0–2.5) with normal plasma and 24 h urine metadrenaline levels.

Following neuroendocrine multidisciplinary team (MDT) review, a 68-Ga-DOTA octreotate positron emission tomography scan was performed. This demonstrated high uptake within the GIST tumour,



CrossMark

**To cite:** Nicholas RS, Quddus A, Topham C, et al. *BMJ Case Rep* Published online: [please include Day Month Year] doi:10.1136/bcr-2014-208271



**Figure 1** CT images demonstrating right carotid body tumour (paraganglioma) measuring 9.0×4.5×2.3 cm. It extends from the caroticojugular spine of the temporal bone superiorly, down to below the level of the carotid bifurcation, enveloping the superior part of the common carotid artery.

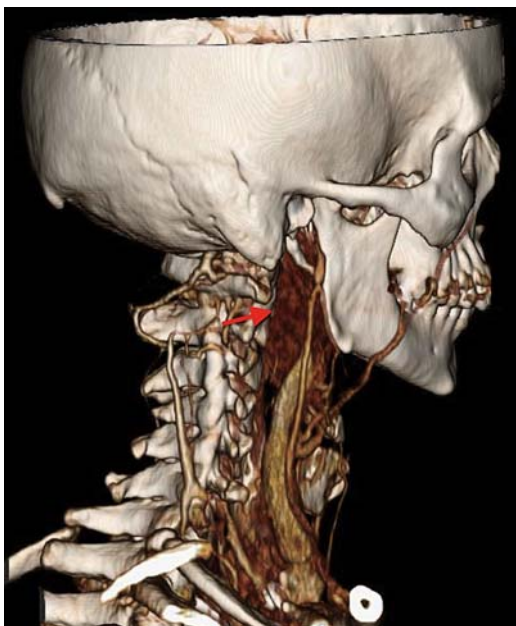
the bilateral head and neck PGLs, and some additional small nodes of uptake in close proximity to the ascending aorta.

The patient was referred for genetic screening in light of the presence of multiple PGLs and the GIST. This established a diagnosis of CSS in association with an SDH-D germline mutation.

### TREATMENT

Following discussion between the neuroendocrine, vascular and hepatobiliary MDTs, excision of the right carotid body tumour was deemed to be the treatment priority, given its increasing size and functionality. The GIST tumour would be excised subsequently. The small left carotid PGL had not changed significantly over the past year to warrant any surgical intervention.

Excision of the large right carotid body tumour was performed by an experienced vascular surgeon, though necessitated extensive perioperative planning and teamwork between neuroendocrine physicians, radiologist, anaesthetist, vascular and maxillofacial surgeons. Detailed three-dimensional reconstructions of the head and neck CT scans enabled detailed preoperative surgical planning (figure 2). Achieving adequate access to



**Figure 2** Three-dimensional reconstruction of CT images demonstrating right carotid paraganglioma in situ.

the tumour was challenging and required maxillofacial surgical input in order to divide and subsequently reform the mandible. This posed additional challenges for the anaesthetic team regarding how to achieve and maintain a safe airway throughout the procedure. The tumour was highly vascular and involved the right carotid body, hypoglossal and vagus nerves (figure 3). Blood pressure was successfully controlled throughout the 9 h operation despite tumour manipulation. Both nerves were preserved and the mandible was reformed with titanium and screws.

As planned, the patient was admitted to the intensive care unit following surgery and had an uneventful immediate post-operative recovery. Nasogastric feeding was started following surgery and propranolol and doxazosin were initiated to control heart rate and blood pressure, prior to discharge from intensive care 4 days postoperatively.

The patient had a hoarse voice and swallowing difficulties postoperatively, as predicted from the necessary and prolonged manipulation of the vagus and hypoglossal nerves which had been adherent to the tumour. Review by SALT and fiberoptic endoscopic evaluation of swallowing confirmed inadequate swallowing protection, vocal fold abduction and non-clearance of secretions, with the need for long-term rehabilitation.

On the 15th postoperative day the patient was discharged home from hospital, with ongoing support from the community SALT team in place. On outpatient follow-up 3 months post discharge, the patient had ongoing hoarseness and difficulty swallowing, so a percutaneous endoscopic gastrostomy tube was inserted to allow supplementation of his nutritional intake.

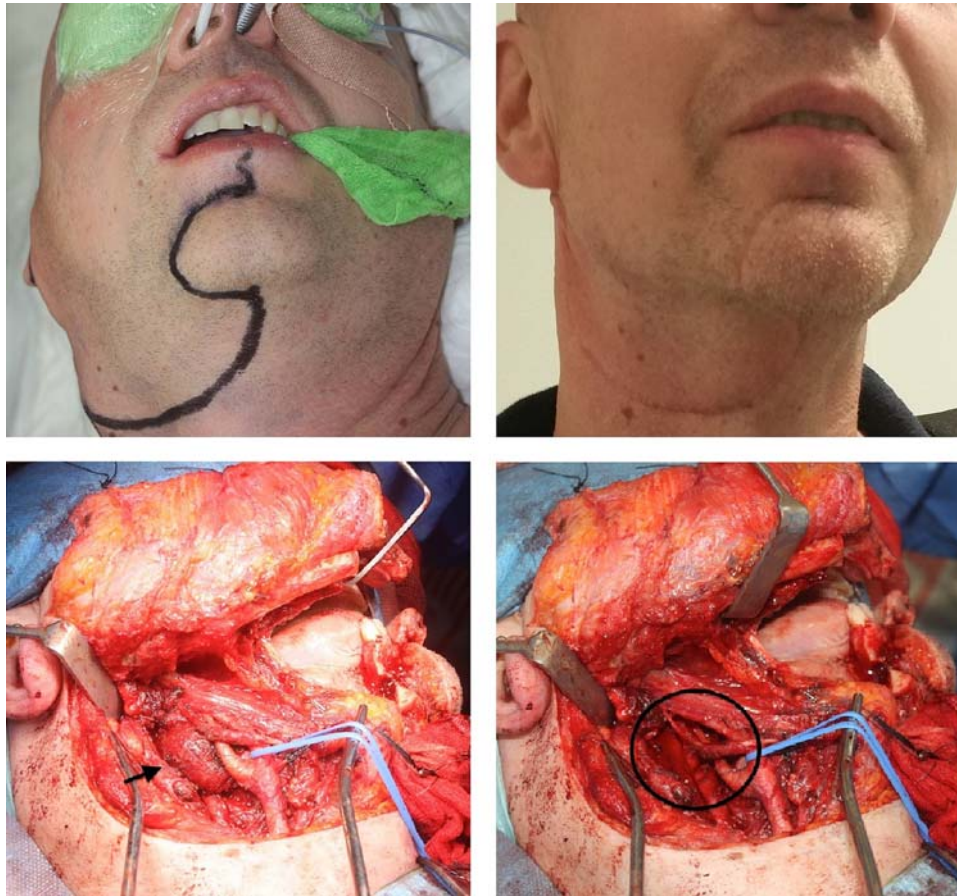
### OUTCOME AND FOLLOW-UP

At 4 months post carotid body tumour resection, the patient was able to return to work as a postman. A year later the patient is now able to swallow and his voice strength has greatly improved.

GIST excision by the hepatobiliary surgical team is being planned as next priority and further therapy with lutetium 177 (<sup>177</sup>Lu) DOTA octreotate or radionuclide-targeted therapy is being considered by the neuroendocrine physicians to treat the residual disease he has associated with his CSS.

### DISCUSSION

PGLs are neuroendocrine tumours that can be derived from either the parasympathetic or sympathetic nervous system. They are rare tumours (1/300 000 incidence) that occur most



**Figure 3** Images showing preoperative markings, postoperative result and intraoperative images pre-excision and postexcision of tumour.

frequently in men and are usually benign. They typically occur in the second and third decades of life.<sup>4</sup> PGLs can be divided into two broad categories dependant on their anatomical location and autonomic function. Extra-adrenal tumours of the head and neck are characteristically located along the carotid bifurcation in close association with the vagus nerve, middle ear space or in the jugular foramen.<sup>5</sup> PGLs located below the neck characteristically occur within the adrenal medulla (phaeochromocytoma), in the upper mediastinum near the aorta, in the organ of Zuckerkandl (chromaffin cells of neural crest origin located along the aorta, most commonly at the inferior mesenteric artery origin or aortic bifurcation), or affecting the paraganglion cells of the urinary bladder. Sympathetic PGLs have a strong tendency to hypersecrete catecholamines (up to 90%) whereas only 5% of parasympathetic PGLs secrete catecholamines.<sup>6</sup>

Up to 35% of PGLs are thought to be hereditary and tumours located at the carotid bifurcation are approximately six times more likely to have a genetic predisposition compared with PGLs located elsewhere.<sup>7</sup> The hereditary syndromes associated with PGLs include Von Hippel Lindau disease, neurofibromatosis type 1, familial PGL syndromes 1–4, multiple endocrine neoplasia type 2 and CSS.

Extra-adrenal PGLs are generally associated with a threefold greater risk of metastases compared with adrenal PGLs.<sup>8</sup> Furthermore, there are currently no reliable histological, genetic or radiological markers to predict malignancy of these tumours except for the appearance of distant metastases in lung, liver or bone.<sup>9</sup> Owing to the possibility of metastases and functioning PGLs, the mainstay of treatment is surgical resection of

suspicious tumours that are functioning or enlarging. Even in instances where the tumour is non-functioning, excision is frequently advocated due to the likelihood of compromise of important vascular and neural structures caused by continued growth of the tumour.<sup>10</sup>

Our case demonstrates the importance of a multidisciplinary approach to surgical resection of a large carotid PGL in a patient with CSS. Careful preoperative preparation is imperative for patient safety. The aim of meticulous preoperative planning is not only to plan the surgical approach, but also to prevent potentially life-threatening catecholamine-induced complications that can be caused by tumour manipulation during surgery. These include hypertensive crisis, cardiac arrhythmias, pulmonary oedema and cardiac ischaemia.<sup>11</sup> A thorough anaesthetic assessment with optimisation of blood pressure, heart rate, anti-hypertensive medication and increasing salt and fluid intake in the preoperative period can reduce perioperative mortality to less than 3%.<sup>12</sup>

Carotid body PGLs are more likely to be malignant than adrenal PGLs and are not amenable to laparoscopic resection. Thus open resection is recommended for all large or invasive head and neck PGLs.<sup>13</sup> Cranial nerve injury (most commonly the vagus or hypoglossal nerve) is the most frequent complication following surgical resection of such PGLs.<sup>13</sup> On review of the literature, it is evident that nerve injury is associated with larger tumour size,<sup>14</sup> in keeping with the Shamblin classification system.<sup>15</sup> This emphasises the need for genetic screening in order to pre-empt familial occurrence and aid early diagnosis. Rates of cranial nerve damage are typically 20–30%, with the vast majority being temporary.<sup>14 16 17</sup>

Multidisciplinary teamwork and safe surgical resection are the cornerstones of current guidance on management of carotid body tumours.<sup>18 19</sup> Owing to their multifocal nature, interdisciplinary communication and collaboration is fundamental to the management of patients with neuroendocrine tumours.<sup>20</sup>

The excision of any carotid body tumour requires a multidisciplinary approach. The additional factors associated with CSS in our patient's case involved further specialists still (for extensive biochemical and radiological investigations, genetic counselling and diagnosis, prioritisation and planning of the adrenal pheochromocytoma, carotid body PGL and subsequent GIST excision) and made this case a true multidisciplinary feat. The case serves to highlight the importance of teamwork between colleagues from various specialties and illustrates the centrality of the MDT to achieve safe and effective management of such complex cases.

### Multidisciplinary specialist perspectives on case

#### *Endocrinology perspective*

"In complex hereditary syndromes the role of the Endocrinologist is to have a low threshold of suspicion and provide accurate interpretation of clinical and laboratory results in order to provide a diagnosis and oversee the management of the patient as a whole. This includes patient and family education, arranging genetic testing and surveillance. In this case, the Neuro-Endocrinology Specialist Team play a lead role in the overall coordination and oversight of the patient's long term care, though clearly collaboration with multiple other specialties is essential in order to provide the treatment the patient requires." (Dr. Tabinda Dugal, consultant endocrinologist)

#### *Anaesthetic perspective:*

"The role of the multidisciplinary team is vital to ensure a good outcome in these rare and complex cases. We, as anaesthetic perioperative physicians are able to impart knowledge relevant to the peri-operative course. Of particular importance is the pre-operative assessment of risk relating to cardio-respiratory fitness and subsequent optimisation, peri-operative management of the difficult airway and cardiovascular responses to tumour manipulation. Finally the post-operative analgesia, airway and cardiovascular management can be planned. Another vital role we have in the multidisciplinary team is reflection on cases and adaption of future management to maintain world class outcomes." (Dr Sandi Wylie, consultant anaesthetist)

#### *Speech and language therapy perspective*

"The speech and language therapy team works closely with patients postoperatively following carotid body tumour removal, assessing and treating them accordingly. Head and neck surgery to resect extensive tumours, such as in this case, carry the risk of vagus and hypoglossal nerve damage, which affect speech and swallowing. Important factors to note were the extent of nerve involvement in the tumour itself, whether any of the nerves needed to be sacrificed in order to achieve resection, and the length of anaesthesia required for the surgery. We serially assess the patient functionally in terms of vocal strength and safety of swallow, and use imaging techniques such as Fiberoptic Endoscopic Evaluation of Swallow (FEES) in order to assist with diagnosis and prognosis. Postoperatively we work closely with the patient, the surgical team, nurses, dieticians, nutritional nurses, ENT doctors and the community speech and language therapy teams in order to provide the joined-up and holistic care the patient needs to achieve a good recovery." (Nicola Perkins, speech and language therapist)

#### *Vascular surgical perspective*

"This is a complex case which involved careful teamwork between several specialties. In order to perform the surgery safely, it required meticulous preoperative planning and support from my anaesthetic and maxillofacial surgical colleagues intraoperatively. Postoperatively the case required extensive input from the speech and language therapy team, which is essential with any case involving the mandible. Their input was especially relevant in this case due to the inevitable speech and swallowing difficulties that follow the resection of a tumour that is involving the nerves which control speech and swallowing. The management of our patient in this case has demonstrated that the only way of ensuring success is a well-organised multidisciplinary team where every specialist has an important role." (Mr Darryll Baker, consultant vascular surgeon)

### Patient perspective

"I first found out I had a tumour in the stomach. That was a massive shock because I felt fine—the discomfort in my stomach had settled down by the time they did the endoscopy. Then they said they found some kind of tumour in my stomach. You automatically think its cancer and I'm going to die within a couple of months—you mind always goes to the worst case scenario.

They took further biopsies and ran further tests and scans and after about 3 weeks they told me the results. The stomach tumour was a GIST, but they found out I also had an enlarged adrenal gland. I had to have this removed, which seemed like a small operation to me. I took it for granted that it went smoothly with no complications. I felt back to normal and was working again as a postman within a couple of weeks.

About a month later I had another more in depth scan. It was at that point that I found out about the paraganglioma in my neck—there was a tiny small one on the left and a large one on the right. Because of the way it grows into other structures, the right carotid tumour had to come out without a doubt. Mr Baker explained everything to me fantastically. He briefed me about everything and explained that because of the way it was growing, he would like a maxillofacial surgeon there in the operation too, which would enable them to open the jaw if they needed to do that to get to the bottom of the tumour—which is what turned out to be necessary. He made me aware of all the risks of nerve damage and everything, and I decided to go through with it. I felt ok up until a day before the operation, when I started to feel nervous. I remember meeting the anaesthetist and both surgeons. They were all fantastic and explained things really well.

When I woke up after the operation I felt fine—I had no pain whatsoever. I thought I was just groggy after the operation. I could speak, but it was nothing compared to my usual voice. It was like having a really bad case of laryngitis. When I heard my own voice it didn't sound like me! To start with I told myself "it will get better in a couple of days" but then when it took longer it felt like it would be forever and permanent—that I wouldn't be able to speak normally again. I didn't know at the time, but when my wife saw me she was in complete shock—She was worried about the neck wound and all the metal staples, as well as my voice. I didn't see the kids for about 10 days.

I knew that the operation needed to be done and that it had been a success, though I also understood that the tumour had been involving the nerves in my neck that are needed for normal swallowing and speech. Even though they were careful and managed not to cut the nerves, it was inevitable that there was some damage, so after the operation I was unable to eat

and drink. Because the nerves were preserved I knew things would get better, but they still suffered significant damage, so took quite a while to improve. You don't realise how long nerves take to recover. The body takes quite a while to repair itself! You always assume that medical people can do a quick intervention and make something better, but there's no quick fix. It took a full year of speech and language therapy to get back to normal with eating and drinking and I had a PEG fitted to supplement my intake in the meantime. The jaw is still slightly stiff compared to the other side, which I've been told can take 18 months to go back to normal. Even simple things like brushing my teeth was really painful after the operation—that took about 9 months to get better.

I had fantastic support after the operation—speech therapy once per week. And my voice has been getting better and better. They put in an implant to push the vocal cords closer together and since then it's been even better. My swallowing has improved and things have moved on tremendously. I am still doing voice and swallowing exercises every day for an hour or so. I am really pleased with the scar on the neck—it is fading really well and the colour is lightening and is almost like my normal skin tone now. There is still a slight twinge in my jaw when I eat, but it is nothing severe, especially compared with the shooting pain in the jaw I got straight after the operation. It was difficult to open my jaw before, but I have had a trismus machine to help me stretch the muscles of my jaw to make the opening back to normal again.

I was back to work about 4 months after the operation, which helped a lot. Just being back to a normal routine was great. For my wife and children too, it was great to have a normal routine just like it was before. My family has adjusted really well and it made a massive difference to eat the Christmas meal together as a normal family this year. It's that kind of stuff you take for granted!

I used to think about the situation over and over, but now it takes up a very small part of my day and I get on as normal. The care I have had has been faultless—it really has been fantastic. When I think about the operation and read up on the internet and realise the amount of structures that run through the base of the skull and the neck and all the things that could have gone wrong, I am just relieved I can move my face—that it's not droopy on one side, my eyes are totally fine, my mouth can move, and speech and swallowing are all getting back to normal. I am really grateful for all the care I've had.

### Learning points

- ▶ This is a classic case of a rare syndrome. Carney-Stratakis syndrome is the dyad of paragangliomas and gastric stromal sarcomas.<sup>21</sup>
- ▶ A multidisciplinary team (MDT) approach was required to direct and achieve appropriate management. Complex cases such as this, with multifocal neuroendocrine tumours and physiological implications, require careful treatment prioritisation, planning and a full complement of specialist knowledge and expertise.
- ▶ Effective teamwork and communication between MDT members, including neuroendocrine physicians, anaesthetist, vascular and maxillofacial surgeons, is essential in order to achieve safe and timely patient care.

I was very aware of the doctors all working together throughout, and still now. They would send me all the notes from the MDT meetings and I always felt involved in all the decisions. At one point I was under about 12 different doctors in four different hospitals because the case was so complex! Before my diagnosis, the only thing I had been to the doctor for was the common cold—I hadn't seen a doctor in years! I used to assume that the one doctor would know everything. Now I know it's a lot more complicated than that and there are many different specialists who need to be involved and work together.”

**Contributors** Supervised by DB. Patient was under the care of DB. Report was written by RN, AQ and CT.

**Competing interests** None.

**Patient consent** Obtained.

**Provenance and peer review** Not commissioned; externally peer reviewed.

### REFERENCES

- 1 Tenorio Jiménez C, Izatt L, Chang F, *et al*. Carney Stratakis syndrome in a patient with SDHD mutation. *Endocr Pathol* 2012;23:181–6.
- 2 Corless CL, Barnett CM, Heinrich MC. Gastrointestinal stromal tumours: origin and molecular oncology. *Nat Rev Cancer* 2011;11:865–78.
- 3 Baez JC, Jagannathan JP, Krajewski K, *et al*. Pheochromocytoma and paraganglioma: imaging characteristics. *Cancer Imaging* 2012;12:153–62.
- 4 Shinn HK, Jung JK, Park JK *et al*. Hypertensive crisis during wide excision of gastrointestinal stromal cell tumor (GIST): undiagnosed paraganglioma—a case report. *Korean J Anesthesiol* 2012;62:289–92.
- 5 Parry DM, Li FP, Strong LC, *et al*. Carotid body tumors in humans: genetics and epidemiology. *J Natl Cancer Inst* 1982;68:573–8.
- 6 Erickson D, Kudva YC, Ebersold MJ, *et al*. Benign paragangliomas: clinical presentation and treatment outcomes in 236 patients. *J Clin Endocrinol Metab* 2001;86:5210–16.
- 7 Drovdic CM, Myers EN, Peters JA, *et al*. Proportion of heritable paraganglioma cases and associated clinical characteristics. *Laryngoscope* 2001;111:1822–7.
- 8 Khorram-Manesh A, Ahlman H, Nilsson O, *et al*. Long-term outcome of a large series of patients surgically treated for pheochromocytoma. *J Intern Med* 2005;258:55–66.
- 9 Harari A, Inabnet WB. Malignant pheochromocytoma: a review. *Am J Surg* 2011;201:700–8.
- 10 Carney JA, Stratakis CA. Familial paraganglioma and gastric stromal sarcoma: a new syndrome distinct from the Carney triad. *Am J Med Genet* 2002;108:132–9.
- 11 Kinney MA, Warner ME, vanHeerden JA, *et al*. Perioperative risks and outcomes of pheochromocytoma and paraganglioma resection. *Anesth Analg* 2000;91:1118–23.
- 12 Neumann HPH, Eng C. The approach to the patient with paraganglioma. *J Clin Endocrinol Metab* 2009;94:2677–83.
- 13 Gad A, Sayed A, Elwan H, *et al*. Carotid body tumors: a review of 25 years experience in diagnosis and management of 56 tumors. *Ann Vasc Dis* 2014;7:292–9.
- 14 Kruger AJ, Walker PJ, Foster WJ, *et al*. Important observations made managing carotid body tumors during a 25-year experience. *J Vasc Surg* 2010;52:1518–23.
- 15 Sajid MS, Hamilton G, Baker DM; Joint Vascular Research Group. A multicenter review of carotid body tumour management. *Eur J Vasc Endovasc Surg* 2007;34:127–30.
- 16 Kakkos SK, Reddy DJ, Shepard AD, *et al*. Contemporary presentation and evolution of management of neck paragangliomas. *J Vasc Surg* 2009;49:1365–73.
- 17 Fruhmant J, Geigl JB, Konstantiniuk P, *et al*. Paraganglioma of the carotid body: treatment strategy and SDH-gene mutations. *Eur J Vasc Endovasc Surg* 2013;45:431–6.
- 18 Lenders JW, Duh QY, Eisenhofer G, *et al*. Endocrine Society. Pheochromocytoma and paraganglioma: an endocrine society clinical practice guideline. *J Clin Endocrinol Metab* 2014;99:1915–42.
- 19 Makeieff M, Thariat J, Rey E, *et al*. Treatment of cervical paragangliomas. *Eur Ann Otorhinolaryngol Head Neck Dis* 2012;129:308–14.
- 20 de Herder WW, Mazzaferro V, Tavecchio L, *et al*. Multidisciplinary approach for the treatment of neuroendocrine tumors. *Tumori* 2010;96:833–46.
- 21 Stratakis CA, Carney JA. The triad of paragangliomas, gastric stromal tumours and pulmonary chondromas (Carney triad), and the dyad of paragangliomas and gastric stromal sarcomas (Carney-Stratakis syndrome): molecular genetics and clinical implications. *J Intern Med* 2009;266:43–52.

Copyright 2015 BMJ Publishing Group. All rights reserved. For permission to reuse any of this content visit <http://group.bmj.com/group/rights-licensing/permissions>.  
BMJ Case Report Fellows may re-use this article for personal use and teaching without any further permission.

Become a Fellow of BMJ Case Reports today and you can:

- ▶ Submit as many cases as you like
- ▶ Enjoy fast sympathetic peer review and rapid publication of accepted articles
- ▶ Access all the published articles
- ▶ Re-use any of the published material for personal use and teaching without further permission

For information on Institutional Fellowships contact [consortiasales@bmjgroup.com](mailto:consortiasales@bmjgroup.com)

Visit [casereports.bmj.com](http://casereports.bmj.com) for more articles like this and to become a Fellow