

Twin congenital epulis in the alveolar ridge of the maxilla and mandible in a newborn: a rare and interesting case

Deepak Sharma,¹ Srinivas Murki,¹ Tejo Pratap,¹ Vallamsetty Leelakumar²

¹Department of Neonatology, Fernandez Hospital, Hyderabad, Andhra Pradesh, India

²Department of Pediatric Surgery, Suraksha Children's Hospital, Tarnaka, Hyderabad, India

Correspondence to

Dr Deepak Sharma,
dr.deepak.rohtak@gmail.com

Accepted 14 August 2014

DESCRIPTION

Case
A term female with birth weight of 2.9 kg was born to a primi mother through normal vaginal delivery. The infant had apgar scores of 8/9/9. At birth the infant was diagnosed with two masses originating from the left maxilla and mandible. The upper maxillary mass was pedunculated and 2×2×1.5 cm in size and the mandibular mass was 1.5×1.5×1 cm in size (figures 1–3). The infant was evaluated with head ultrasound, whole body X-ray and echocardiography for other malformations; all reports were normal. The infant was diagnosed as a case of congenital epulis and was operated on. Both the masses were removed and the postoperative course was uneventful; the infant was discharged. The histopathology report confirmed the diagnosis of epulis.

Discussion

Congenital epulis is also known as Neumann's tumour, granular cell tumour or congenital gingival

granular cell tumour.¹ The incidence of congenital epulis has been reported to be about 0.0006%. The size of the lesion can vary from a few mm to 8 cm.² This tumour is more common in women, with female-to-male ratio being 8:1.³ This tumour arises from the mucosa of the gingiva, usually from the anterior part of the maxillary alveolar ridge. On examination, infants with congenital epulis clinically present with a mass protruding from the mouth, which may produce difficulty in feeding or breathing if it is large.⁴ These tumours are uniformly benign in nature. Differential diagnosis includes⁵

- ▶ Hemangioma
- ▶ Lymphangioma
- ▶ Fibroma
- ▶ Granuloma
- ▶ Rhabdomyosarcoma
- ▶ Osteogenic sarcoma
- ▶ Chondrogenic sarcoma
- ▶ Schwannoma
- ▶ Heterotopic gastrointestinal cyst

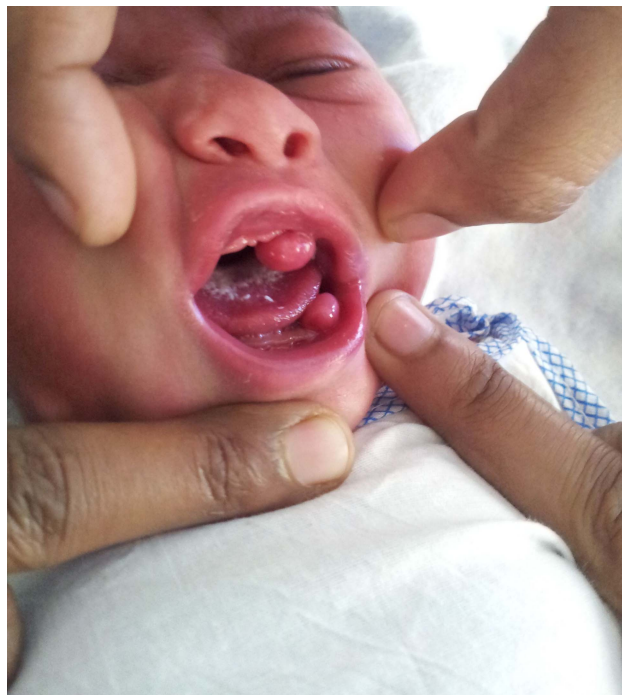

Figure 1 Two large pedunculated masses on the maxillary and mandibular alveolar ridges in a neonate female. Maxillary mass 2×2×1.5 cm in size and mandibular mass 1.5×1.5×1 cm in size.



CrossMark

To cite: Sharma D, Murki S, Pratap T, et al. *BMJ Case Rep* Published online: [please include Day Month Year] doi:10.1136/bcr-2014-206490

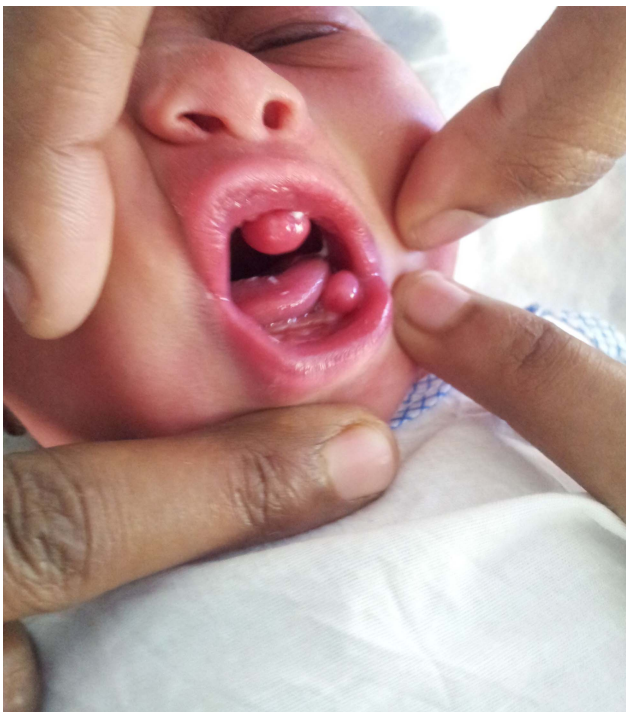

Figure 2 Two large pedunculated masses on the maxillary and mandibular alveolar ridges in a neonate female. Maxillary mass 2×2×1.5 cm in size and mandibular mass 1.5×1.5×1 cm in size.

Histology shows polygonal cells with pink, PAS-positive granular cytoplasm and regular, round, dark basophilic-staining nuclei.⁶ The recommended treatment is prompt surgical resection. These tumours have very good prognosis.⁷

Key messages

- ▶ Twin congenital epulis are very rare tumours seen at birth.
- ▶ Prompt surgical excision is the treatment of choice.
- ▶ These tumours should be confirmed with histopathology as other conditions can also present in similar fashion.

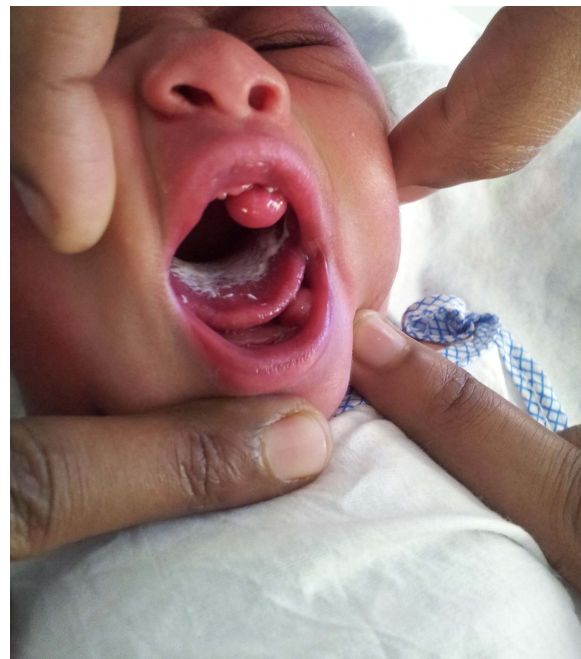


Figure 3 Two large pedunculated masses on the maxillary and mandibular alveolar ridges in a neonate female. Maxillary mass 2×2×1.5 cm in size and mandibular mass 1.5×1.5×1 cm in size.

Competing interests None.

Patient consent Obtained.

Provenance and peer review Not commissioned; externally peer reviewed.

REFERENCES

- 1 Neumann E. Elin fall von congaliter epulis. *Arch Helik* 1871;12:189.
- 2 Zuker RM, Buenecha R. Congenital epulis: review of the literature and case report. *J Oral Maxillofac Surg* 1993;51:1040–3.
- 3 Mueller DT, Callanan VP. Congenital malformations of the oral cavity. *Otolaryngol Clin North Am* 2007;40:141–60, vii.
- 4 Merrett SJ, Crawford PJ. Congenital epulis of the newborn: a case report. *Int J Paediatr Dent* 2003;13:127–9.
- 5 Lapid O, Shaco-Levy R, Krieger Y, *et al.* Congenital epulis. *Pediatrics* 2001;107:E22.
- 6 Lack EE, Worsham GF, Callihan MD, *et al.* Gingival granular cell tumors of the newborn (congenital "epulis"): a clinical and pathologic study of 21 patients. *Am J Surg Pathol* 1981;5:37.
- 7 Kumar Dutta H. Jaw and gum tumours in children. *Pediatr Surg Int* 2009;25:781–4.

Copyright 2014 BMJ Publishing Group. All rights reserved. For permission to reuse any of this content visit <http://group.bmj.com/group/rights-licensing/permissions>.
BMJ Case Report Fellows may re-use this article for personal use and teaching without any further permission.

Become a Fellow of BMJ Case Reports today and you can:

- ▶ Submit as many cases as you like
- ▶ Enjoy fast sympathetic peer review and rapid publication of accepted articles
- ▶ Access all the published articles
- ▶ Re-use any of the published material for personal use and teaching without further permission

For information on Institutional Fellowships contact consortiasales@bmjgroup.com

Visit casereports.bmj.com for more articles like this and to become a Fellow