

An unusual cause of haemoptysis: isolated tracheobronchial amyloidosis

K I Zalewska, A Brown, D J McKeon

Department of Respiratory Medicine, Ysbyty Gwynedd, Bangor, Gwynedd, UK

Correspondence to
Dr Kasia Zalewska,
kzalewska@doctors.net.uk

Accepted 28 July 2014

DESCRIPTION

A 64-year-old woman presented with chest pain, wheeze and haemoptysis. She had a history of previous pulmonary embolism (PE) and Sjögrens syndrome. A chest radiograph was unremarkable. CT pulmonary angiogram (CTPA) showed no evidence of PE; however, a mass was noted in the left lower lobe extending to the left hilum (figure 1).

Bronchoscopic examination demonstrated inflamed, friable mucosa in this area (figure 2) but no endobronchial lesion. Biopsies from this area showed fibrosis and deposition of eosinophilic amorphous material that was positive for Congo Red staining with an apple green birefringence. The deposits stained specifically with antibodies against λ light-chains, confirming the presence of amyloid light-chain (AL) amyloidosis in the bronchial mucosa.

Clinical evaluation, serum amyloid P component (SAP) scintigraphy and echocardiography did not show amyloid deposition in other organs, confirming isolated tracheobronchial amyloidosis. Further investigation for monoclonal plasma cell dyscrasia was negative.

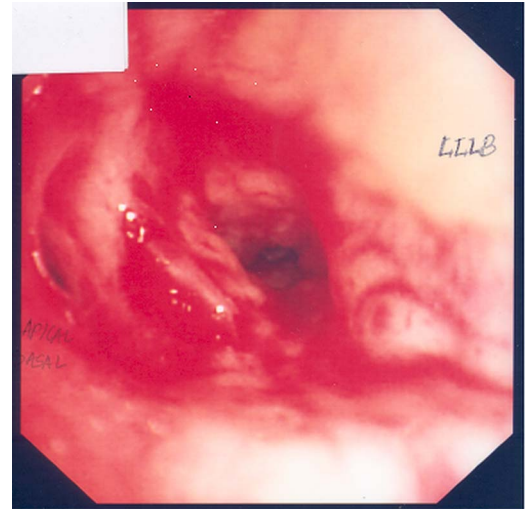


Figure 2 Inflamed, friable mucosa at bronchoscopy.

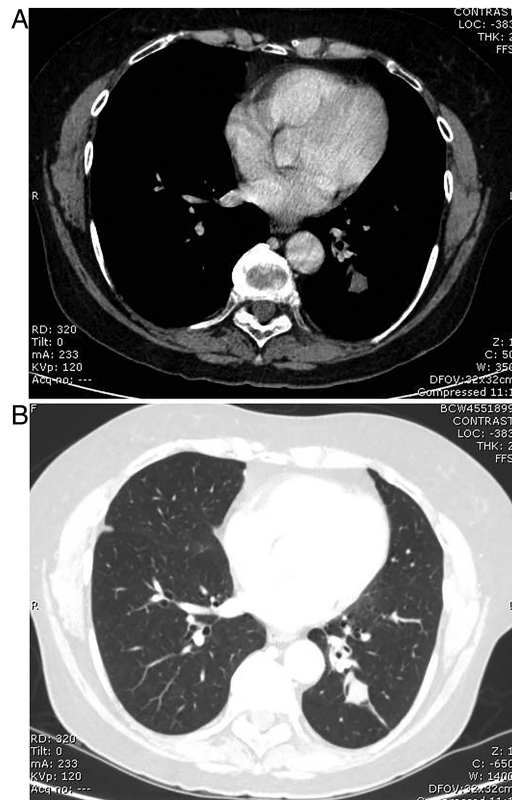


Figure 1 The left lower lobe mass seen on CT scan. (A) Soft tissue window. (B) Pulmonary window.

Learning points

- ▶ Pulmonary involvement in amyloidosis is uncommon. Patients may present with haemoptysis, dyspnoea, cough or recurrent pneumonia.
- ▶ Pulmonary amyloidosis appears in four patterns on imaging; parenchymal nodules, interstitial shadowing, tracheobronchial submucosal plaques or intraluminal nodules, which can mimic bronchogenic carcinoma.¹
- ▶ Diagnosis of isolated pulmonary amyloidosis requires investigations to exclude systemic amyloidosis.
- ▶ AL amyloid accounts for the majority of cases of pulmonary amyloidosis. AL amyloidosis is associated with monoclonal plasma cell dyscrasia,² therefore, patients with proven AL amyloidosis should also be evaluated for concurrent multiple myeloma.

Contributors KIZ, AB and DMM fulfil the criteria: substantial contributions to the conception or design of the work; or the acquisition, analysis, or interpretation of data for the work; drafting the work or revising it critically for important intellectual content; final approval of the version to be published; agreement to be accountable for all aspects of the work in ensuring that questions related to the accuracy or integrity of any part of the work are appropriately investigated and resolved.

Competing interests None.

Patient consent Obtained.

Provenance and peer review Not commissioned; externally peer reviewed.



To cite: Zalewska KI, Brown A, McKeon DJ. *BMJ Case Rep* Published online: [please include Day Month Year] doi:10.1136/bcr-2014-205118

REFERENCES

- 1 Pitz MW, Gibson IW, Johnston JB. Isolated pulmonary amyloidosis: case report and review of the literature. *Am J Hematol* 2006;81:212–13.
- 2 Dinner S, Witteles W, Witteles R, et al. The prognostic value of diagnosing concurrent multiple myeloma in immunoglobulin light chain amyloidosis. *Br J Haematol* 2013;161:367–37.

Copyright 2014 BMJ Publishing Group. All rights reserved. For permission to reuse any of this content visit <http://group.bmj.com/group/rights-licensing/permissions>.
BMJ Case Report Fellows may re-use this article for personal use and teaching without any further permission.

Become a Fellow of BMJ Case Reports today and you can:

- ▶ Submit as many cases as you like
- ▶ Enjoy fast sympathetic peer review and rapid publication of accepted articles
- ▶ Access all the published articles
- ▶ Re-use any of the published material for personal use and teaching without further permission

For information on Institutional Fellowships contact consortiasales@bmjgroup.com

Visit casereports.bmj.com for more articles like this and to become a Fellow